

## SURGICAL CONDITIONS OF THE ABDOMEN VIEWED ON A NATIVE ABDOMINAL RADIOGRAPH IN AN UPRIGHT POSITION

Rade R Babic <sup>1</sup>, Gordana Stankovic-Babic <sup>2</sup>, Mirko Krstic <sup>3</sup>, Natasa Markovic <sup>4</sup>, Sasa Zivic <sup>5</sup> and Zvonko Dinic <sup>6</sup>

The paper presents surgical conditions of the abdomen viewed on a native abdominal radiograph in an upright position: atresia anus, the Chilaiditi syndrome, ileus, pneumoperitoneum, calcified pancreas. A native radiograph of the abdomen in an upright position is a dominant examination method in diagnostics of an acute abdomen, intestinal obstruction and perforation and other pathologic conditions of the abdomen. *Acta Medica Medianae* 2007;46(2):68-70.

**Key words:** native roentgen of the abdomen, roentgen diagnostics

Institute of Radiology, Clinical Center Nis <sup>1</sup>,  
Clinic of Ophthalmology, Clinical Center Nis <sup>2</sup>  
Clinic of Cardiovascular Diseases, Clinical Center Nis <sup>3</sup>  
Surgical Clinic, Clinical Center Nis <sup>4</sup>  
Pediatric Internal Clinic, Clinical Center Nis <sup>5</sup>  
Institute in Ribarska Banja <sup>6</sup>

Correspondence to: Rade R Babic  
Institute of Radiology, Clinical Center Nis  
48 Dr Zoran Djindjic Blvd.  
18000 Nis, Srbija  
Tel.: 018/ 20 20 40

### Introduction

A radiological examination of the abdomen should always commence with a native radiograph of the abdomen in an upright position (1-6). It is the simplest and most commonly used examination method in diagnostics of pathologic conditions of abdominal organs; also, it is often a sufficient diagnostic method by itself (1-3,7,8). In special circumstances, a radiograph of the abdomen can be made with a patient lying on his side with a horizontal x-ray beam, which is the case with difficult patients; or in the Wangesteen-Ric position, which is used in children with gastrointestinal anomalies etc (1-5,9-12). A native radiograph of the abdomen in an upright position is a dominant examination method in diagnostics of an acute abdomen, intestinal obstruction and perforation and other pathologic conditions of the abdomen.

### Aims

The aim of the paper was to point out the diagnostic possibilities of a native radiograph of the abdomen in the field of surgical abdominal conditions. This paper is based on many years of material gathering and papers of other authors.

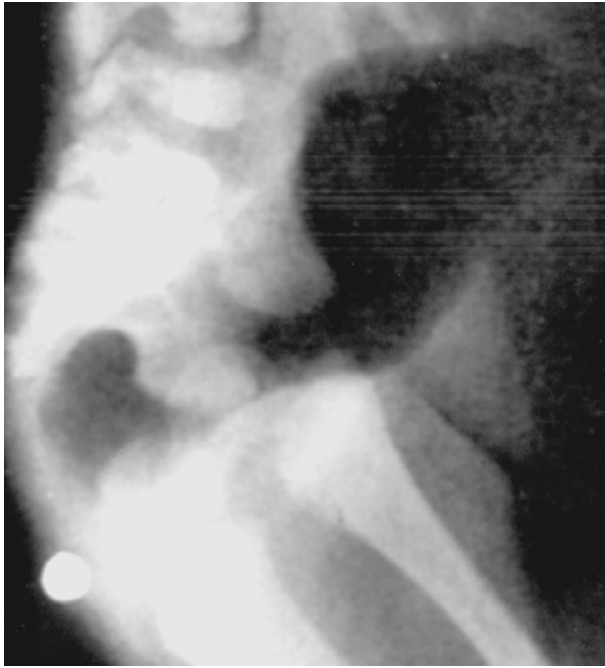The native radiographs of the abdomen were made by using a standard protocol:

*A native radiograph of the abdomen in an upright position.* Preparation of the patient: clothes were removed, as well as any metal objects from the patient's body. The patient is in an upright position. A 35x43cm or 35x35cm film is commonly used. The radiographic cassettes must carry a sign which marks the side of the patient. A technically correct radiograph must visualize the domes of the diaphragm and its sides must be clearly marked.

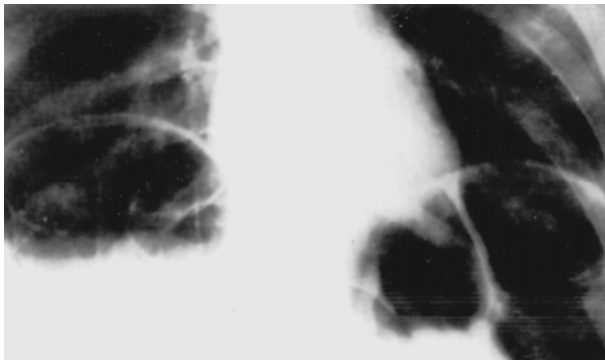*A radiograph of the abdomen in a patient lying on his side with a horizontal x-ray beam.* It is rarely used and only for difficult patients. A patient is lying on his side. A 35x43cm or 35x35cm film is commonly used. The radiographic cassettes must carry a sign which marks the side of the patient.

*A native radiograph of the abdomen in the Wangesteen-Ric position.* It is applied in children. Preparation of the patient: clothes were removed, as well as any metal objects from the child's body. The child's anus should be marked using a marker. Position: the child is held by its legs and hangs upside down. A 24x30 cm or 35x35 cm film is commonly used. Projection: anteroposterior (AP), posteroanterior (PA) or latero-lateral. The radiographic cassettes must carry a sign which marks the side of the patient. A technically correct radiograph must visualize the domes of the diaphragm, the metal marker and its sides must be clearly marked.

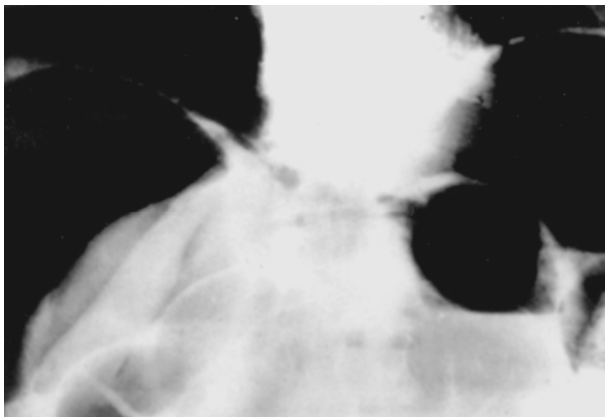
The results of the paper show the possibilities and advantages of the native radiograph of the abdomen in an upright position; with a patient lying on his side with a horizontal x-ray beam and in the Wangesteen-Ric position in diagnostics of surgical conditions of the abdomen.



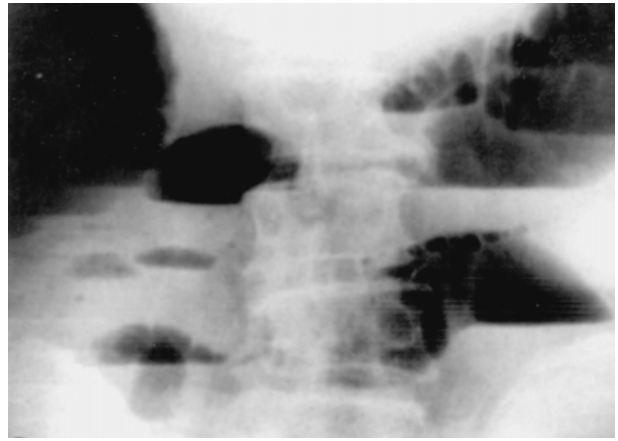
Picture 1. Anal and rectal atresia. A native radiograph of the abdomen in the Wangenstein-Ric position. The location of the anal atresia is marked with a metal marker. Transparency of the gas visualizes the blind ending of the intestine



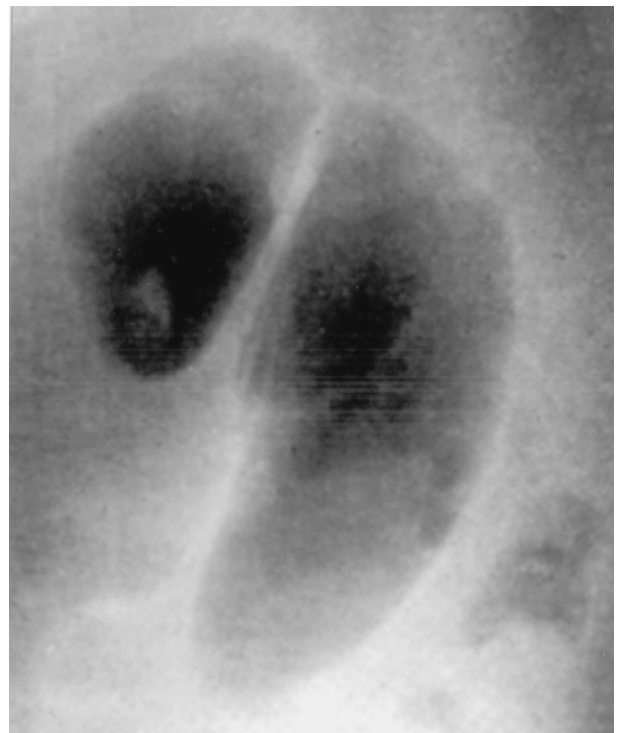Picture 2. Chilaiditi syndrome. Native radiograph of the abdomen in an upright position. Intrahepatodiaphragmal interposition of the colon; filled with gas



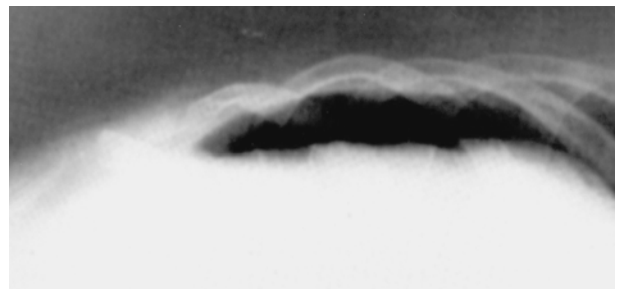
Picture 3. Pneumoperitoneum. Native radiograph of the abdomen in an upright position. Transparencies are visible subphrenically, on both sides, which represents free gas in the abdominal cavity, as a complication of a duodenal ulcer perforation



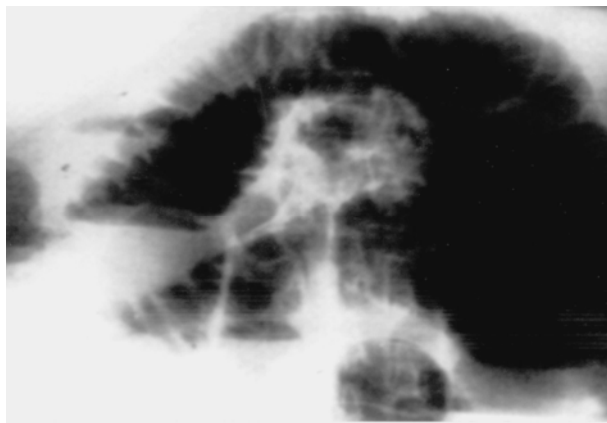
Picture 4. Ileus. Native radiograph of the abdomen in an upright position. Hydro-gas levels with gas distension of the intestine are visible, which is typical of the obstructive type of ileus



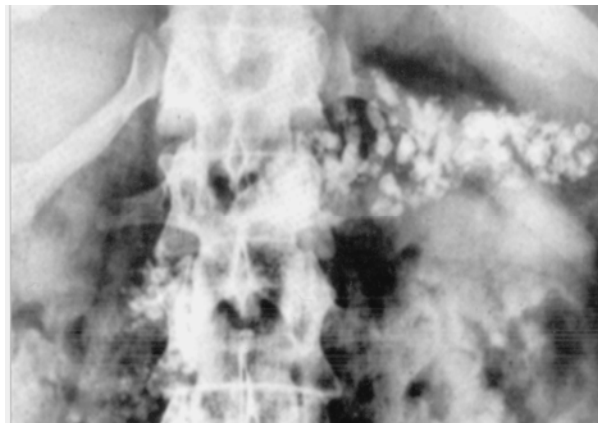
Picture 5. Ileus. Native radiograph of the abdomen in an upright position. Strangulated portion of the intestine, filled with gas, is visualized as a "coffee bean" with a central band-like transparency; a characteristic of strangulation type of ileus



Picture 6. Pneumoperitoneum. A radiograph of the abdomen with a patient lying on his side with a horizontal x-ray beam. A gas collection is visible as a transparency between the liver and the lateral abdominal wall



Picture 7. Ileus. Native radiograph of the abdomen in an upright position. Hydro-gas levels with gas distension of the intestine are visible



Picture 8. Calcified pancreas. Native radiograph of the abdomen in an upright position

### Discussion and conclusion

Native radiograph of the abdomen in an upright position is a sovereign, dominant examination method, without competition when surgical conditions of the abdomen are concerned. Our professional experience tells us that the precision of radiological diagnostics of pathologic conditions of the abdomen largely depends on the technical quality of the radiograph and within reasonable limits, on the number of different projections used in the explorations of the abdomen. Today, in the

era of digitalization of the radiological images, the latter is reduced to a minimum and the acquired radiological images of the abdomen become relevant in setting the final diagnosis. One's knowledge and experience has significant importance in setting the diagnosis of pathologic conditions of the abdomen, as well as the compatibility of findings by radiologists, surgeons and doctors of other specializations. Practically, it is the axiom of overall diagnostics (radiological, surgical) of the sick abdomen.

### References

1. Babić RR. Dijagnostičke mogućnosti nativnog rendgenograma abdomena. *Acta Medica Medianae* 2001; 6:55-62.
2. Babić RR, Babić R. Rendgenološka slika anomalija gastrointestinalnog trakta. *Acta Medica Medianae* 1997; 5: 69-78.
3. Babić RR, Babić R, Babić D. Hirurška stanja abdomena prepoznatljiva rendgenskim pregledom abdomena. *Acta Medica Medianae* 1994; 6: 71-7.
4. Babić R. Sindroma chilaiditi. *Srpski arhiv* 1961; 97: 1399-404.
5. Lazić J, Ivković T, Babić R, Čikarić S, Milatović S. *Radiologija*. Beograd: Medicinska knjiga/ Medicinske komunikacije; 1997.
6. Milošević Z, Mijović Z, Stošić-Opinčal T, Goldner B, Kostić B, Menković N i sar. Diferencijalna dijagnoza kalcifikacija u slezini. *RAS* 1998; 1: 37-42.
7. Plavšić B. *Radiologija probavnog kanala*. Zagreb: Školska knjiga; 1989.
8. Raičević M, Albijanić D, Mijatović M, Sjekloća V, Vlahović B, Lončarević G. Radiološko vodjenje pregleda akutnog abdomena kod dece – malrotatio intestini, u: *Zbornik Pedijatrijski dani '92. Pedijatrijski arhiv Podružnice Srpskog lekarskog društva*. Niš; 1992: 46'47.
9. Živković R. *Gastroenterološka ultrasonografija*. Beograd/Zagreb: Medicinska knjiga; 1988.
10. Mills J, Ho TM, Trunkez DD. *Urgentna medicina. Savremena dijagnostika i lečenje*. Beograd: Savremena administracija; 1987.
11. Dragović M. *Urgentna hirurgija*. Beograd/Zagreb: Medicinska knjiga; 1988.
12. Merkaš Z. *Radiologija*. Beograd: Nova knjiga; 1978.

## HIRURŠKA STANJA ABDOMENA NA NATIVNOM RENDGENOGRAMU ABDOMENA U STOJEĆEM STAVU

Rade R Babić, Gordana Stanković-Babić, Mirko Krstić, Nataša Marković, Saša Živić i Zvonko Dinić

U radu se prikazuju hirurška stanja abdomena dijagnostikovana nativnim rendgenogramom abdomena u stojećem stavu: atrezija anusa, sindroma Chilaiditi, ileus, pneumoperitoneum, kalcifikovan pankreas. Zaključuje se da je nativni rendgenogram abdomena u stojećem stavu dominantna metoda pregleda u dijagnostici akutnog abdomena, opstrukcije, perforacije gastrointestinalnog trakta i dr. patoloških stanja i oboljenja abdomena. *Acta Medica Medianae* 2007;46(2):68-70.

**Ključne reči:** nativni rendgenogram abdomena, rendgenodijagnostika