

## ON THE OCCASION OF A RADIOLOGIC FINDING OF PRIMARIUS DR. VESELIN G. KRAJČIĆ

Rade R. Babić

Primarius Dr. Veselin G. Krajčić was the first radiologist in Niš. He was appointed in 1931 as the director of the Institute of Radiology in the State Hospital in Niš. He had his own private practice. The paper presents his radiologic finding. This paper was written as a contribution to the history of radiology in Serbia and Niš. *Acta Medica Medianae* 2009;48(2):55-56.

**Key words:** Primarius Dr. Veselin G. Krajčić, radiology, Niš, Serbia

Institute of Radiology, Clinical Center Niš

Contact: Rade R. Babić  
Institute of Radiology, Clinical Center Niš  
Bulevar dr Zorana Djindjića 48  
18 000 Niš, Serbia  
Phone: 018-202-040

### Introduction

Primarius Dr. Veselin G. Krajčić (Figure 1.) was born on July 23, 1895 in Niš (1,2). He completed primary school and began high school in Niš, which he left because of the World War I (1914).




Figure 1. Primarius Dr. Veselin G. Krajčić

As a pupil recruited for the Serbian army, he participated in the First World War. He crossed Albania on foot and survived Albania's Golgotha. He was recipient of the Albania Honor Memorial Badge.

Serbian government sent him to school to France, where he completed secondary school (1916, Verep). He graduated from the School of

Medicine in Bordeaux in 1922. After his work at the Department for Internal Medicine in Military Hospital in Niš and hospital in Urosevac, he specialized in radiology in Belgrade and Paris. In 1931, he was appointed the director of the Institute of Radiology in the State Hospital in Niš. During the Second World War and in the postwar period, he was the director of the hospital until July 1, 1958. His was a specialist in roentgen diagnostics of gastrointestinal tract and osteoarticular system and radiotherapy. One of his papers, "Planiography- taking images in layers", was published in 1947 in Serbian Archives, Record No. 10 (2).

Primarius Dr. Veselin G. Krajčić had his own private practice, which was on the ground floor of his family house. He had a German x-ray machine. That x-ray machine was sold to the Medical Institution in Vrnjacka Banja after the abolishment of private medical practice in country.

This is one of his numerous radiology findings (Figure 2).

Radiology finding was typed on the prescription with Cyrillic typewriter.

Memorandum of the prescription had Cyrillic printing.

The following was noted on the memorandum: Department head of the State hospital Dr. Veselin G. Krajčić, specialist in radiology

Open from 2-5 pm, except on Sundays.

At the bottom of the memorandum there was the address - Ulica Orlovića Pavla (Poenkareova Ulica) 20/a, and a phone number - 161.

Radiology finding was a diagnosis of a 41-year-old patient V. P. from Toponica and it read "He is complaining of pain in kidneys. However, an x-ray of the both kidneys and of the lumbar part of the vertebral column did not show any concretions in the kidneys part, neither the caries nor malformation of the vertebrae. Bacteriologist Dr Radosavljevic took the urine sample for tests".

At the bottom of the prescription was the date of the medical examination- February 29, 1944 and signature of Dr Veselin G. Krajcic.

This paper is a contribution to the history of radiology in Serbia and Niš.

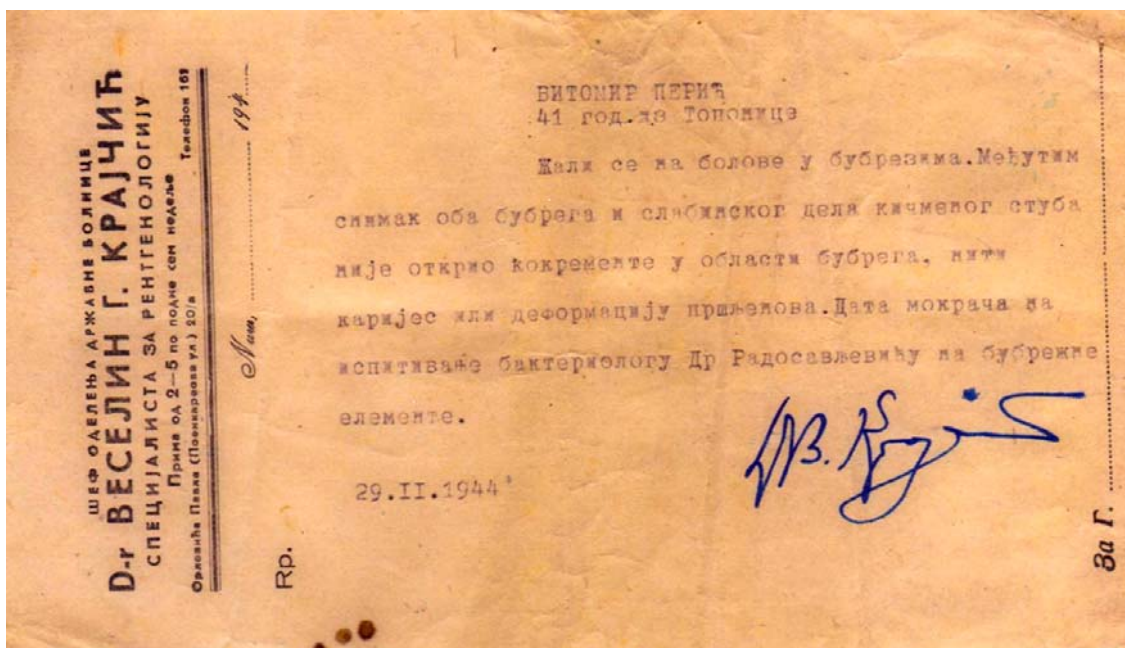


Figure 2. Radiologic finding of Dr. Veselin G. Krajčić from 1944

### References

1. Živić R. Enciklopedija. Niš. Niš: Gradina 1996.
2. Krajčić G. V. Planiografija – snimanje u slojevima. Srpski arhiv 1947:10;

## POVODOM JEDNOG RADIOLOŠKOG NALAZA PRIMARIJUSA DR VESELINA G. KRAJČIĆA

Rade R. Babić

Primarijus dr Veselin G. Krajčić prvi je radiolog u Nišu. Godine 1931. imenovan je i postavljen na mesto upravnika Zavoda za rendgenologiju Državne bolnice u Nišu. Imao je svoju privatnu praksu. U radu se prikazuje jedan njegov radiološki nalaz. Rad je napisan kao prilog za istoriju radiologije u Srbiji i Nišu. *Acta Medica Medianae* 2009;48(2):55-56.

**Ključne reči:** Primarijus dr Veselin G. Krajčić, radiologija, Niš, Srbija