

CORRELATION OF TUMOUR SUPPRESSOR GENE P53 EXPRESSION WITH MACROSCOPIC MANIFESTATION AND GROWTH PATTERN OF COLORECTAL CANCER

Dušica Petrović¹, Vesna Stanković², Miloš Milosavljević¹ and Vladimir Bulatović¹

Colon carcinoma is one of the most common malignant tumours and the second cause of cancer-related deaths in developed countries.

The objective of the research was to investigate the p53 expression in colorectal cancer and compare the expression levels of p53 with the macroscopic appearance and manner of growth of the tumours, followed by detection and identification of the expression levels of p53 as an important prognostic factor of the further course, outcome and data for the selection of appropriate therapy.

Research was implemented as a prospective, clinical and experimental study. We used a postoperative material obtained by resection of colorectal cancer from 63 patients of both sexes.

The results showed that the majority of tumours 36/63, i.e. 57.1% were manifested as infiltrative forms, 9/63, i.e. 14.3% as ulcerating form, and 18/63, i.e. 28.6% of tumours had a polypoid – exophytic form.

The results have shown that three tumours of infiltrative forms were p53 negative and 17 of them were p53 positive. In tumours with ulcerating form, eight were p53 negative, and 16 of them were no p53 positive tumours. In vegetative tumour forms, four were p53 negative, and 15 of the were p53 positive.

Positive p53 status was present in 52.4% of tumours. Expression of p53 was absent in 47.6% of the tumours and does not correlate with the macroscopic appearance and manner of tumour growth. Expression levels of p53 do not have a diagnostic, predictive and prognostic potential, while its importance is undeniable in the understanding of oncogenesis. *Acta Medica Medianae* 2011; 50(3):22-26.

Key words: colorectal cancer, p53, correlation, macroscopic appearance, growth pattern

Centre for Pathological-Anatomical Diagnosis, Clinical Centre
Kragujevac, Kragujevac, Serbia¹
University of Kragujevac, Faculty of Medicine, Kragujevac, Serbia²

Contact: Dušica Petrović
Center for Pathological-Anatomical diagnostics
Clinical Center Kragujevac
Zmaj Jovina 30, 34000 Kragujevac, Srbija
E-mail: dusica@euro-net.org

Introduction

Colon carcinoma is one of the most common malignant tumour and the second cause of cancer-related deaths in developed countries (1).

Processes of division, differentiation and cell death are strictly controlled, and a disorder in the regulation of any of them gives rise to clones of cells that independently and inappropriately breed and produce the tumour mass. The onset of tumour is a complex process involving many genetic and molecular mechanisms. Oncogenesis is the result of accumulation of disorder in the structure and function of genes regulating cell proliferation mechanisms, reparation of DNA molecule or programmed cell death. These genes

are: oncogenes, tumour suppressor genes, genes that are the matrix for the synthesis of the reparatory system enzymes, as well as genes that control apoptosis (2).

The main role of tumour suppressor genes is to stop the cell cycle in order to repair defects in the structure of DNA molecule (3). Mutation and inactivation of tumour suppressor genes results in uncontrolled cell division and blockage of programmed cell death-apoptosis. They are inherited recessively and their expression occurs after inactivation of both alleles.

p53 is the most common mutated gene in cancers, localized on chromosome 17, encodes p53 transcription factor that regulates cell cycle through the activation of genes transcription that stops the cycle in the G1 phase (when the gene is damaged) and activates apoptosis under certain conditions (4-6). Genes activated by p53 transcription factor are WAF1 (cell cycle control), MDM2 (inhibits expression of p53), GADD45 (DNA repair control), Bax (apoptosis control) cyclin G, while inhibiting myc and bcl-2.

The basic functions of p53 are participation in the reparation of DNA molecules (correcting

errors in the duplication of genetic material) as well as controlling the cell cycle, proliferation and differentiation. Also, when it comes to the accumulation of genetic errors, p53 allows apoptosis, which is why it is known as „guardian of the cell genome“.

The data obtained as a result of various clinical and basic studies suggest that damage or mutation of p53 leads to gene amplification of p53 and loss of control of cell cycle and apoptosis. The level of these changes has reflected the degree of unfavourable prognosis in patients, the very reason that tumours with over-expression of p53 have shown resistance to radiation and most chemotherapeutics (7).

The objective of this study was to determine the possible correlation between the morphological parameters and the expression levels of p53 and identification of possible prognostic significance of this correlation. In accordance with the basic objective, the following specific tasks have been set:

1. Examination of p53 expression at the operational material-resected segments from patients with colorectal carcinoma.
2. Correlation between p53 expression with the macroscopic appearance and manner of tumour growth.
3. Detection and identification of p53 tumour suppressor gene expression levels as an important prognostic factor for further progress and outcome of disease and the data for the choice of suitable, optimal, target, individual anti-tumour therapy.

Materials and methods

The study was implemented as a prospective, clinical and experimental study. We used a postoperative material obtained by resection of the colorectal tumours of 63 patients of both sexes, from the Surgery Clinic of Clinical Centre in Kragujevac. In order to obtain as much relevant histopathological data, the routine haematoxylin - eosin (HE) and immunohistochemical methods were performed at the Centre for Pathological-Anatomical Diagnosis of Clinical Centre "Kragujevac" in Kragujevac.

Routine HE method was used for pathohistological verification of tumours, and histopathological analysis. In the routine processing of products, tissue samples were fixed in 4% neutral buffer formalin solution, in 24 hours, at room temperature. Upon completion of fixation, they were dehydrated through a series of alcohols of increasing concentration (70%, 96% and 100%), stained in xylol and embedded in paraffin. Tissue sections, 4 µm thick, were cut with microtomes Leica SM 2000R and Leica Reinhart Austria.

After deparaffinization in xylol and hydration in decreasing order of alcohol, sections were stained with haematoxylin according to Mayer, stained in 2% eosin, then dehydrated, stained and mounted on a plate with Canada balsam (8-10).

Immunohistochemical methods were used to identify the expression of antigen in colorectal cancer resection sample. The procedure for immunohistochemical staining included the unmasking of antigens, blocking of endogenous peroxidase, incubation with primary antiserum preparation and the procedure of immuno-histochemical methods - LSAB+ - HRP (11).

For detection of p53 murine monoclonal antibody was applied (DAKO p53 DO-7 monoclonal mouse clone, 1:200) and highly sensitive specific streptavidin - biotin immunohistochemical method (LSAB+/HRP, DAKO, Denmark), in which the streptavidin is labelled with peroxidase and as a chromogen 1,3 - diaminobenzidine was used. As a general solvent of antiserum and rinsing solution between the different steps in the immunohistochemical staining procedure 0.1 M phosphate buffer pH 7.4 was used. Cell nuclei were stained with Mayer's haematoxylin.

Cut off is the selected threshold value to distinguish positive and negative expression of p53. Cut off in this study to assess positivity was > 30% (score of overexpression if more than 30% tumour cells showed immunoreactivity for p53). Scoring system is based on determination of the percentage of immunoreactive nuclei of tumour cells as well as the intensity of immunoreactive staining. Adding points for the percentage of immunoreactivity and intensity gives the total, maximum possible points for the evaluation of expression (Table 1).

Table 1. Total possible maximum points for the assessment of expression

% IMMUNOREACTIVE NUCLEI	INTENSITY OF IMMUNOREACTIVE STAINING
0 = <5% stained nuclei	0 = no nuclei stained
1 = 5 do 30% stained nuclei	1 = poor intensity of nuclei staining
2 = 30 do 50% stained nuclei	2 = moderate intensity of nuclei staining
3 = 50 do 70% stained nuclei	3 = very intensive staining
4 = 70 do 90% stained nuclei	
5 > 90% stained nuclei	

Immunohistochemical staining was carried out with the control of quality and specifics of staining, using positive and negative controls according to the propositions of UK NEQAS (UK National External Quality Assessment for immunocytochemistry). For statistical data processing SPSS software package and methods of descriptive statistics were used (frequencies, percentages, median, and percentiles). Testing according to two descriptive variables was carried out using Chi-square test and Fisher test. Investigation of

the effect of several variables on a binary variable was performed using binary logistic regression multivariate analysis.

Results

Nuclear expression of p53 was present in 33/63, i.e. in 52.4% (grade of positivity for more than 30% tumour cells showing immunoreactivity for p53). In 30/63 i.e. 47.6% had no expression of p53 (Table 2).

Table 2. Expression of p53

P53 expression	Frequency	Percentage (%)
Negative	33	52,4
Positive	30	47,6
Total	63	100,0

The largest number of tumours 36/63, i.e. 57.1% was manifested in the form of infiltrative forms, 9/63, i.e. 14.3% as ulcerating form, and 18/63, i.e. 28.6% of tumours had a polypoid - exophytic appearance (Table 3).

Table 3. Macroscopic manifestation of tumour

Macroscopic manifestation of tumour	Frequency	Percentage (%)
Exophytic	18	28,6
Ulcerating	9	14,3
Infiltration	36	57,1
Total	63	100,0

The results show that three tumours of infiltrative forms were p53 negative and 17 of them were p53 positive. In tumours with ulcerating form, eight were p53 negative, and 16 of them were no p53 positive tumours. In vegetative tumour forms, four tumours were p53 negative, and 15 of the were p53 positive (Table 4).

Table 4. Correlation of macroscopic manifestation and expression of p53

Macroscopic manifestation of tumour	P53-	P53+	Percentage (%) -	Percentage (%) +
Vegetative form	4	15	21.05	78.95
Ulcerating form	8	16	33.33	66.67
Infiltrative form	3	17	15	85

Macroscopic manifestation of the tumour and p53 are independent ($p=0.104$).

In order to obtain reliable parameters to examine the various factors that could affect the expression of p53, binary logistic regression was performed.

The presented results showed that p53 is not dependent on clinical and histological parameters (Figure 1-4).

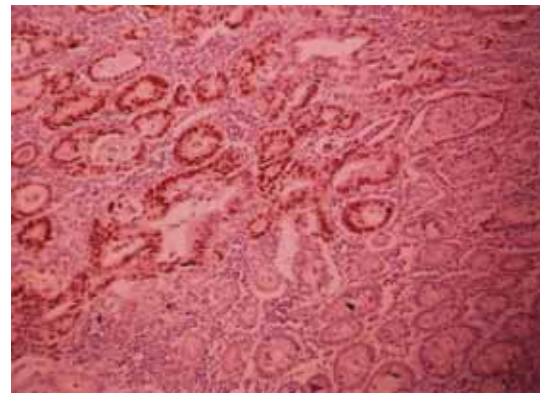


Figure 1. p53 - the internal negative control (IHH, x 100)

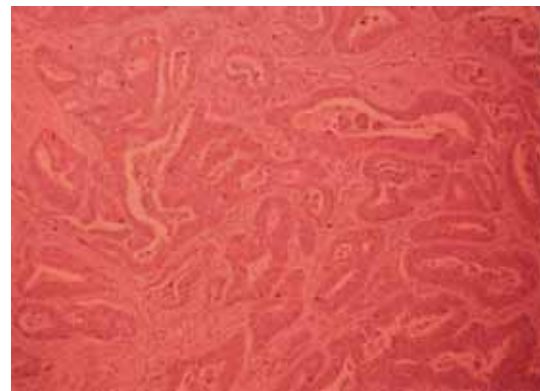


Figure 2. Tumour cells nuclei show no immunoreactivity to p53 (IHH, x 100)

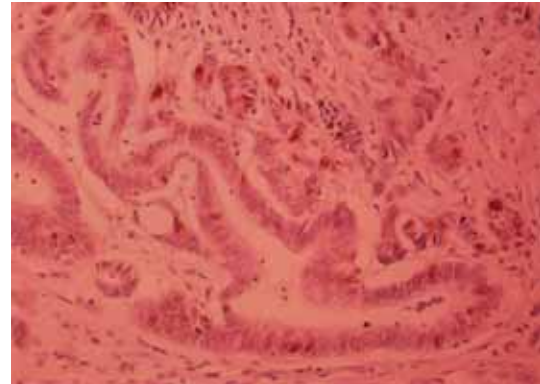


Figure 3. Tumour cells nuclei showed immunoreactivity of p53 to 30% (IHH, x 200)

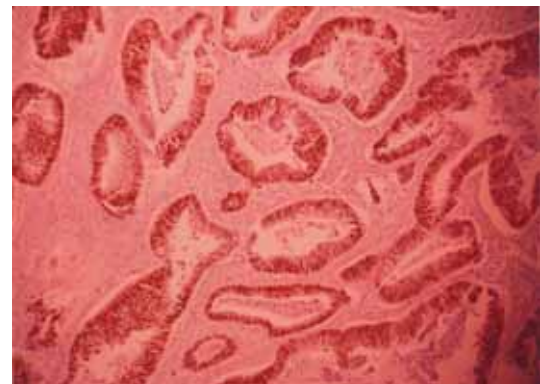

Figure 4. Tumour cells nuclei showed immunoreactivity of p53 over 30% (IHH, x 100)

Discussion

Colorectal cancer (CRC) is one of the most common causes of morbidity and mortality in both western world and our region. Classifications and established prognostic parameters, which are today used in the treatment of CRC, still only partially provide information about the course and outcome of this disease, hence there is a need to improve existing and identify new diagnostic and prognostic markers. In this regard it is especially important to identify molecular markers that would provide insight into the potential behaviour or aggressiveness of the tumour (12-14).

Since the current clinical and morphologic parameters (histological type of tumour, degree of differentiation, tumour stage, nodal status, invasion of vascular structures and surgical margins) still retain their dominant role in diagnostic procedures, molecular profiling would complement them, mostly in terms of recognizing the response to the therapy (genetic changes), or in terms of application in improving the screening of high-risk categories to allow for timely and successful treatment (15).

The largest number of tumours 36/63, i.e. 57.1% was manifested in the form of infiltrations, 9 / 63, i.e. 14.3% as ulcerating form, and 18/63, i.e. 28.6% of tumours had a polypoid – exophytic look.

The results of this study showed that nuclear expression of p53 was present in 33 cases or 52.4% of the total, with a rating of positivity evaluated as p53 expression in more than 30% of tumour cells. In 30 samples, or 47.6% of the total number of analyzed CRC there was no p53 expression. The data are consistent with data from the literature on the expression of p53 markers in colorectal cancer, according to which the normal p53 expression in all carcinomas

is 45-70%, while the expression of this marker in colorectal carcinomas is 42-67% (16, 17).

The results of various studies suggest that, in regards to prognosis, it is not sufficient to follow only the expression of p53, but it is necessary to monitor the expression of other tumour markers, whose behaviour can also lead to better therapeutic approaches for the treatment of malignant tumours (18-21).

P53 expression does not depend on the macroscopic manifestations of tumours and tumour growth pattern, i.e., there is no correlation between p53 expression and the macroscopic manifestation and manner of growth of CRC, which would serve as a prognostic factor in the further course and outcome of the illness.

Although the influence of macroscopic manifestation of the tumour on the p53 expression was not statistically significant ($p=0.124$), it was found that in ulcerating forms the possibility that p53 is positive is many times lower (odds ratio 0,032, $p=0,017$).

Conclusion

Expression of p53 was present in 52, 5% of the tumours and does not correlate with the macroscopic manifestation or the growth pattern of colorectal carcinoma.

Based on the aforesaid, it could be concluded that in previous studies the role of p53 as an important prognostic indicator has not been proven. Evaluation of the genes and molecular profiling can help identify groups of patients with overexpression of p53, which might imply a particular therapeutic intervention and an important therapeutic target for screening purposes.

Expression level of p53 does not have diagnostic, predictive and prognostic potentials, while its importance is undeniable in the understanding of oncogenesis.

References

1. Perraud A, Akil H, Nouaille M, Petit D, Labrousse F, Jauberteau MO, Mathonnet M. Expression of p53 and DR5 in normal and malignant tissues of colorectal cancer: Correlation with advanced stages. *Oncol Rep* 2011; 26(5): 1091-7. [[PubMed](#)]
2. Compton C. Colorectal carcinoma: Diagnostic, prognostic and molecular features. *Mod Pathol* 2003; 16(4): 376-81. [[CrossRef](#)] [[PubMed](#)]
3. Losi L, Ponti G, Gregorio CD, Marino M, Rossi G, Pedroni M, Benatti P, Roncucci L, de Leon MP. Prognostic significance of histological features and biological parameters in stage I (pT1 and pT2) colorectal adenocarcinoma. *Pathol Res Pract* 2006; 202(9): 663-70. [[CrossRef](#)] [[PubMed](#)]
4. Smith G, Carey F.A, Beattie J. Mutations in APC, Kirsten-ras, and p53-alternative genetic pathways to colorectal cancer. *PNAS* 2002; 14: 9433-38. [[CrossRef](#)] [[PubMed](#)]
5. Tada M, Furuuchi K, Kaneda M. Inactivate the remaining p53 allele or the alternate p73. Preferential selection of the Arg72 polymorphism in cancers with recessive p53 mutants but not trans dominant mutants. *Carcinogenesis* 2001; 3: 515-17. [[CrossRef](#)] [[PubMed](#)]
6. Matsuda K, Hotta T, Takifuji K, Kobayashi Y, Tsuji T, Nagai Y, Horiuchi T, Yamaue H. Lymph nodes ratio is associated with the survival of colorectal cancer patients with peritoneal carcinomatosis. *Am Surg* 2011; 77(5): 602-7. [[PubMed](#)]
7. Thirion A, Rouanet P, Thezenas S: Interest of investigating p53 status in breast cancer by four different methods. *Oncology Reports* 2002; 9: 1167-72. [[PubMed](#)]
8. Howlett CJ, Tweedie EJ, Driman DK. Use of an elastic stain to show venous invasion in colorectal carcinoma: a simple technique for detection of an important prognostic factor. *J Clin Pathol* 2009; 62(11): 1021-5. [[CrossRef](#)] [[PubMed](#)]
9. Bancroft JD and Gamble M, editors. *Theory and practice of histological techniques*. 5th edition. Churchill Livingstone: Edinburgh, London, New York, Oxford; 2002.

10. Totty AB. The Mucins. In: Bancroft JD, Gamble M, editors. Theory and practice of histological techniques. 5th ed. Churchill Livingstone: Edeinburgh, London, New York, Oxford; 2002.
11. Shiratsuchi I, Akagi Y, Kawahara A, Kinugasa T, Romeo K, Yoshida T, Ryu Y, Gotanda Y, Kage M, Shirouzu K. Expression of IGF-1 and IGF-1R and Their Relation to Clinicopathological Factors in Colorectal Cancer. *Anticancer Res* 2011; 31(7): 2541-5. [[PubMed](#)]
12. Soliani P, Ziegler S, Romani A, Corcione L, Campanini N, Dell'Abate P, Del Rio P, Sianesi M. Prognostic significance of nm23 gene product expression in patients with colorectal carcinoma treated with radical intent. *Oncology Reports* 2004; 11: 1193-1200. [[PubMed](#)]
13. Dan-ping Z, Xiao-wen D, Jia-ping P, Yi-xiong Z, Suzhan Z. Prognostic significance of bcl-2 and p53 expression in colorectal carcinoma. *J Zhejiang Univ Science B* 2005; 6(12): 1163-69. [[CrossRef](#)] [[PubMed](#)]
14. Torsello A, Garufi C, Cosimelli M, Diodoro MG, Zeuli M, Vanni B, Campanella C, D'Angelo C, Sperduti I, R.Donnors P, Cognetti F, Terzoli E, Mottolese M. P53 and bcl-2 in colorectal cancer arising in patients under 40 years of age: Distribution and prognostic relevance. *Eur J Canc* 2008; 44: 1217-22. [[CrossRef](#)] [[PubMed](#)]
15. Higashi D, Futami K, Ishibashi Y, Egawa Y, Maekawa T, Matsui T, Iwashita A, Kuroki M. Clinical course of colorectal cancer in patients with ulcerative colitis. *Anticancer Res* 2011; 31(7): 2499-504. [[PubMed](#)]
16. Verdú M, Román R, Calvo M, Rodón N, García B, González M, Vidal A, Puig X. Clinicopathological and molecular characterization of colorectal micropapillary carcinoma. *Mod Pathol* 2011; 24(5): 729-38. [[PubMed](#)]
17. Curtis Lj, Georgiades IB, White S, Bird CC, Harrison DJ, Wyllie AH. Specific patterns of chromosomal abnormalities are associated with HER status in sporadic colorectal cancer. *J Pathol* 2000; 192: 440-45. [[CrossRef](#)]
18. Claudio P. P, Zamparelli A, Garcia F. U, Claudio L. Expression of Cell-Cycle-regulated Proteins pRb2/p130, p107, p27kip1, p53, mdm-2, and Ki-67 (MIB-1) in Prostatic Gland Adenocarcinoma. *Clin Canc Res* 2002; 6: 1808-15.
19. Sasaki S, Yamamoto H, Kaneto H. Differential roles of alterations of p53, p16, and SMAD4 expression in the progression of intraductal papillary-mucinous tumors of the pancreas. *Oncol Rep* 2003; 10: 21-5. [[PubMed](#)]
20. Berge E, Thompson C, Messersmith W. Development of Novel Targeted Agents in the Treatment of Metastatic Colorectal Cancer. *Clin Colorectal Cancer* 2011; [Epub ahead of print]. [[PubMed](#)]
21. Blagosklonny M, p53 from complexity to simplicity: mutant p53 stabilization, gain-of-function, and dominant-negative effect. *FASEB J* 2000; 13: 1901-7. [[CrossRef](#)] [[PubMed](#)]

KORELACIJA EKSPRESIJE P53 TUMOR SUPRESOR GENA SA MAKROSKOPSKOM MANIFESTACIJOM I NAČINOM RASTA KOLOREKTALNIH KARCINOMA

Dušica Petrović, Vesna Stanković, Miloš Milosavljević i Vladimir Bulatović

Karcinom debelog creva jedan je od najčešćih malignih tumora i drugi po redu uzročnik smrti od karcinoma u razvijenim zemljama.

Cilj istraživanja bio je ispitivanje ekspresije p53 kod kolorektalnog karcinoma kao i komparacija nivoa ekspresije p53 sa makroskopskim izgledom i načinom rasta tumora, zatim detekcija i identifikacija nivoa ekspresije p53 kao značajnog prognostičkog faktora daljeg toka, ishoda bolesti i podatka za izbor adekvatne terapije.

Istraživanje je urađeno kao prospektivna, kliničko-eksperimentalna studija. Korišćen je postoperativni materijal dobijen resekcijom kolorektalnog karcinoma od 63 bolesnika oba pola.

Dobijeni rezultati su pokazali da se najveći broj tumora, 36/63, tj. 57.1%, manifestovao u vidu infiltrativne forme, 9/63, tj. 14.3% kao ulcerišuća forma, a 18/63, tj. 28.6% tumora imalo je polipoidni – egzofitičan izgled.

Rezultati su pokazali da je tri tumora infiltrativne forme bilo p53 negativno a 17 ih je bilo p53 pozitivno. Kod tumora ulcerišuće forme 8 je bilo p53 negativno, a 16 je bilo pozitivnih p53 tumora. Kod tumora vegetativne forme, četiri je bilo p53 negativno, a 15 tumora bilo je p53 pozitivno.

pozitivan p53 status bio je u 52,4% tumora. Ekspresija p53 izostala je u 47,6% tumora i ne korelira sa patohistološkim karakteristikama tumora. Nivo ekspresije p53 nema dijagnostički, prediktivni i prognostički potencijal, dok je neosporna njegova važnost u razumevanju onkogeneze. *Acta Medica Medianae* 2011;50(3):22-26.

Ključne reči: kolorektalni karcinom, p53, korelacija, makroskopski izgled, način rasta