

TEMPORARY PACEMAKER LEAD PLACEMENT IN PATIENT WITH PERSISTENT LEFT SUPERIOR VENA CAVAVladimir Mitov¹, Zoran Perišić², Aleksandar Jolić¹, Tomislav Kostić², Danijela Nikolić¹ and Aleksandar Aleksić¹

Persistent left superior vena cava represents a congenital vascular defect of the venous system, and is usually discovered accidentally. Temporary pacemaker lead placement should be performed under the fluoroscopy control, but also by using the ECG QRS morphology. Echocardiography also represents a reliable noninvasive diagnostic tool for the assessment of temporary pacemaker lead position. *Acta Medica Medianae* 2011; 50(3):54-57.

Key words: persistent left superior vena cava, temporary pacemaker lead

Department of Cardiology, Medical Center Zaječar, Serbia¹
Pacemaker Center, University Hospital Niš, Serbia²

Contact: Vladimir Mitov
Pacemaker Center, Department of Cardiology
Medical Center Zaječar
Rasadnicka bb, 19000 Zaječar
E-mail: mitov@ptt.rs

Introduction

Persistent left superior vena cava represents a congenital defect of the venous system.

In the early phase of embryogenesis, the venous system is bilateral - meaning that there are bilateral primitive venous vessels. An anomaly in this phase of embryogenesis is characterized by the existence of bilateral venous system. Usually, besides PLSVC, the right vena cava superior (VCS) is also present, with communication between them through the variable vena inominata, which can be absent in 70% of cases (1). In 65% of patients, the right VCS is small in diameter (2).

In the latter phases of embryogenesis, the bilateralism of the venous vessels disappears. The venous defect created in this phase is characterized with only one VCS. One percent of patients has only PLSVC (3-5).

Regarding the way of PLSVC joining the heart, two anatomic varieties are described:

- PLSVC joins the right atrium over the dilated coronary sinus; this variation is seen in over 90% of patients. It can exist by itself, or in conjunction with other cardiovascular system anomalies.

- Other variations mean PLSVC joining the left atrium in two ways:

- Through the coronary sinus, which has a wall defect and thus communicates with the left atrium;
- Directly through the upper part of the left atrium, between the upper left pulmonary vein

and left atrial appendage. This anomaly is always joined by (or with) other congenital heart defects (6, 7).

Case report

Our patient was a 76-year-old male. He was admitted to the Department of Cardiology, Medical Center Zaječar, due to vertigo and syncope, occurring in the same day. ECG presented with sinus bradycardia, heart rate was 35 beats per minute, with ventricular premature beats, and episodes of non-sustained ventricular tachycardia. Temporary pacemaker implantation was indicated due to severe bradycardia accompanied by malignant ventricular rhythm disorder and new onset of syncope.

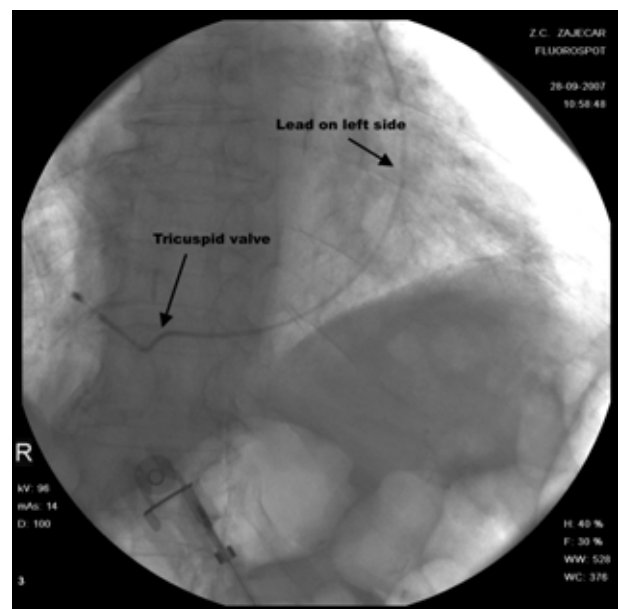


Figure 1. PA Chest fluoroscopy. Temporary pace maker lead atypical position

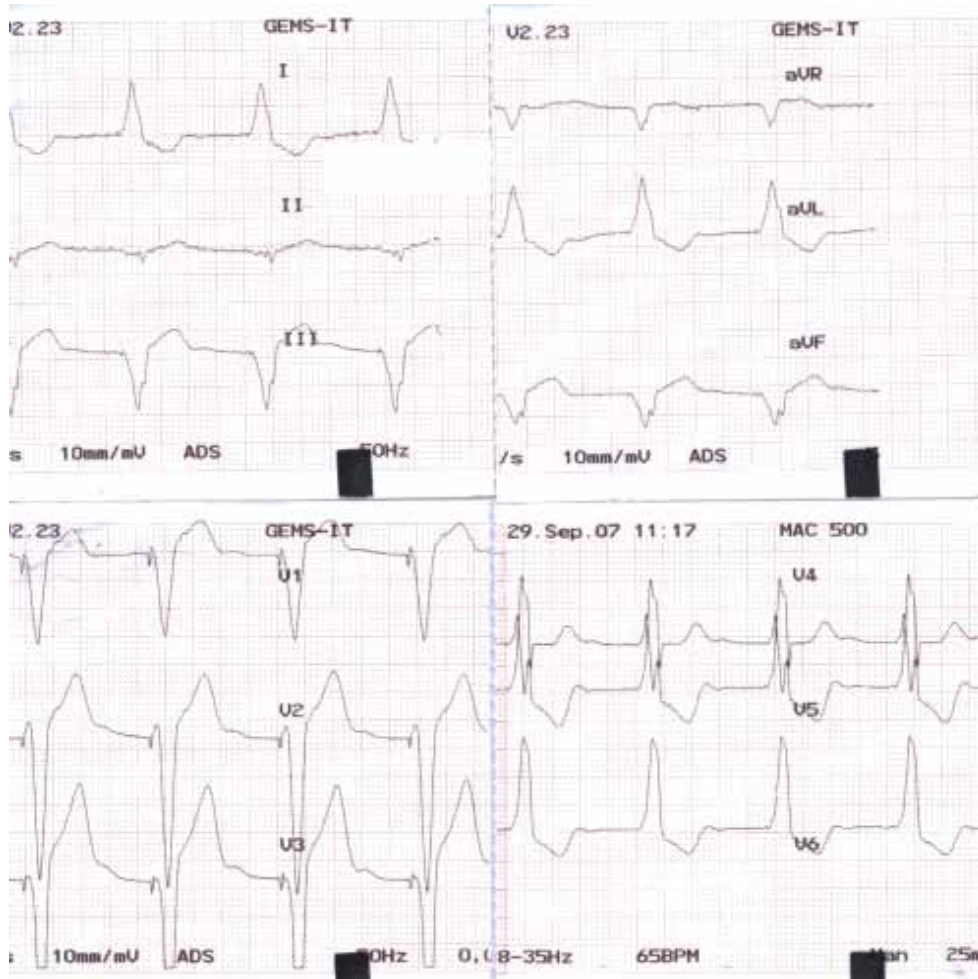


Figure 2. Standard 12 leads ECG. After temporary pace maker lead implantation

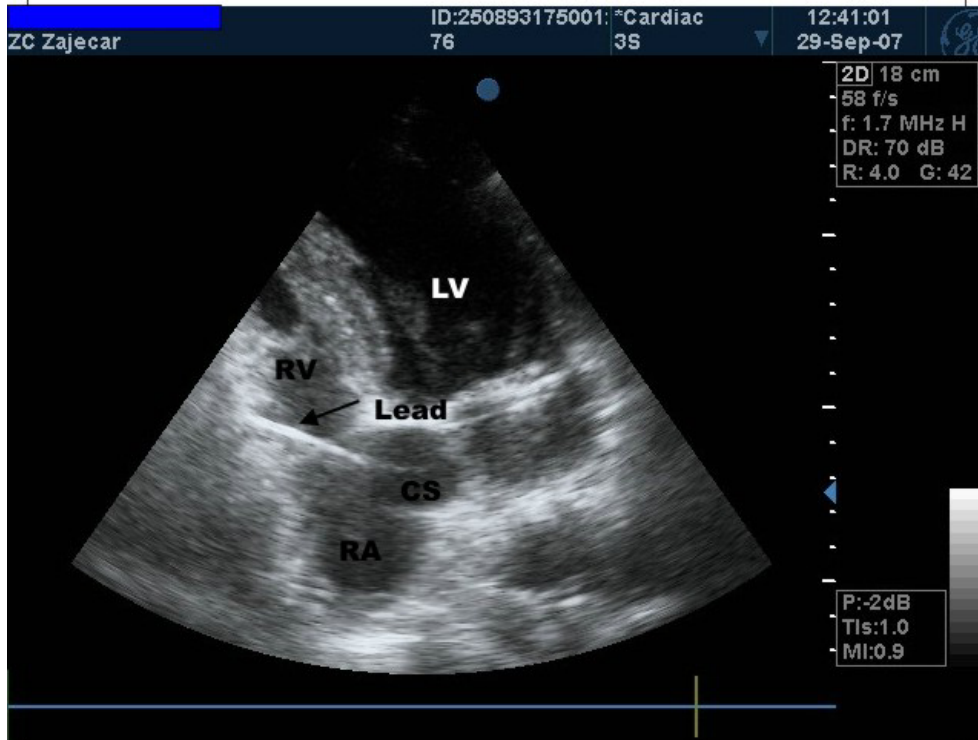


Figure 3. Echocardiography, four-chamber view. Temporary pace maker lead positioned in right ventricle. RV-right ventricle, LV-left ventricle, CS- coronary sinus, RA-right atrium

A right chamber approach by the right subclavial vein was undertaken, during which the expected approach through the VCS was not achieved. Therefore, the electrode placement was tried over the left subclavial vein. The lead had an unusual pathway on the left side of the heart and spine (Figure 1).

The lead was placed in the right heart structure, but it seemed not in the right ventricle according to the fluoroscopy control. However, based on the movement of the electrode, we concluded that the electrode passed the tricuspid valve (Figure 1). Recorded ECG showed the pacemaker rhythm, with wide QRS and dominant R in leads I, aVL, V4-6, and dominant S in leads II, III, aVF, V1-3, as in the left bundle branch block. This ECG morphology represented the pacemaker stimulation from the right ventricle (Figure 2). By means of echocardiography, it was found that the pacemaker lead passed through the dilated coronary sinus, then through the tricuspidal valve, and was positioned in the right ventricle free wall (Figure 3). Although the pacemaker lead had an unusual position, myocardial stimulation was adequate in the next two days and during the transportation of the patient to the Pacemaker Center in Niš for permanent pacemaker implantation.

Discussion

The overall incidence of PLSVC is 0,30 to 0,50% in general population, 4% of which have congenital defects (2, 7). The incidence is similar in patients that need pacemaker therapy, and is 0,47% (8). According to data from The National

Referral Register of the Pacemaker Center of the Clinical Center of Serbia, its incidence is 0,25% per year.

PLSVC is clinically insignificant for patients, and is usually discovered accidentally during the implantation of temporary or permanent pacemaker lead or central venous catheters. However, PLSVC is a great clinical problem and challenge for standard pacemaker lead placement. Coronary sinus lead can be used as a valid alternative approach for ventricular pacing since the coronary sinus is easily approachable (9). PLSVC presents itself as significant problem, especially for patients where ICD, CRT-P or CRT-D pace maker leads are implanted (10, 11).

Although vena cava superior has abnormal inflow into the right atrium, temporary pacemaker lead placement and stable myocardial stimulation is possible. In these patients, the control of pacemaker lead placement could be obtained by means of fluoroscopy and using the ECG QRS morphology at same time. Temporary pacemaker lead position can be confirmed by echocardiography, which is a simple, noninvasive diagnostic tool.

Conclusion

Persistent left superior vena cava represents a rare congenital vascular defect of the venous system, and is usually discovered accidentally. Temporary pacemaker lead placement should be and could be made under the fluoroscopy control and using the ECG QRS morphology. Echocardiography is also a reliable noninvasive diagnostic tool for the assessment of temporary pacemaker lead position.

References

- Pai RK, Cadman CS. Persistence with a persistent left and absent right superior vena cava. *Cardiol Rev.* 2005 ; 13(3): 163-4. [[CrossRef](#)] [[PubMed](#)]
- Demos TC, Posniak HV, Pierce KL, Olson MC, Muscato M. Venous Anomalies of the Thorax. *AJR.* 2004 ; 182(5): 1139-50. [[PubMed](#)]
- Ramos N, Fernandez-Pineda L, Tamariz-Martel A, Villagra F, Egurbide N, Maitre MJ. Absent Right Superior Vena Cava With Left Superior Vena Cava Draining to an Unroofed Coronary Sinus. *Rev Esp Cardiol.* 2005 ; 58(8): 984-7. [[CrossRef](#)] [[PubMed](#)]
- Ratliff HL, Yousufuddin M, Lieving WR, Watson BE, Malas A, Rosencrance G et al. Persistent left superior vena cava: case reports and clinical implications. *Int J Cardiol.* 2006 Nov 10; 113(2): 242-6. [[CrossRef](#)] [[PubMed](#)]
- Girerd N, Gressard A, Berthezene Y, Lantelme P. Persistent left superior vena cava with absent right superior vena cava: A difficult cardiac pacemaker implantation. *Int J Cardiol.* 2009 Mar 6; 132(3): e117-9. [[CrossRef](#)] [[PubMed](#)]
- Nedeljković S, Kanjuh V, Vukotić M. *Kardiologija.* Treće izdanje. Beograd: D.p. za izdavačko trgovinsku delatnost; 2000. p. 516-22.
- Paval J, Nayak S. A persistent left superior vena cava. *Singapore Med J.* 2007; 48(3): e90-e3.
- Biffi M, Boriani G, Frabetti L, Bronzetti G, Branzi A. Left superior vena cava persistence in patients undergoing pacemaker or cardioverter-defibrillator implantation: a 10-year experience. *Chest.* 2001 ; 120(1): 139-44. [[CrossRef](#)] [[PubMed](#)]
- Mitov V, Perišić Z, Kostić T, Stojković A, Jolić A, Aleksić A, Milašinović G. An Alternative Approach for Endocardial Pacemaker Lead Implantation in Patient with Persistent Left Superior Vena cava. *Srp Arh Celok Lek.* 2010; 138(1-2): 85-7. [[CrossRef](#)]
- Antonelli D, Rosenfeld T. Implantation of dual chamber pacemaker in a patient with persistent left superior vena cava. *Pacing Clin Electrophysiol.* 1997 Jun ; 20(6): 1737-8. [[CrossRef](#)] [[PubMed](#)]
- Moriña-Vázquez P, Barba-Pichardo R, Venegas Gamero J, Herrera Carranza M. [Cardiac resynchronization through a persistent left superior vena cava]. *Med Intensiva.* 2006 Dec ;30(9): 471-3. [[Spanish](#)] [[PubMed](#)]

PLASIRANJE ELEKTRODE PRIVREMENOG PEJSMEJKERA KOD BOLESNIKA SA PERZISTENTNOM LEVOM VENOM CAVOM SUPERIOR

*Vladimir Mitov, Zoran Perišić, Aleksandar Jolić, Tomislav Kostić, Danijela Nikolić
i Aleksandar Aleksić*

Perzistentna leva vena cava superior predstavlja kongenitalnu anomaliju venskog sistema koja se slučajno otkriva. Pozicioniranje elektrode privremenog pejsmejkera treba navoditi rendgenoskopijom, ali i pod kontrolom EKG morfologije QRS. Ehokardiografija predstavlja pouzdanu neinvazivnu dijagnostičku metodu za procenu položaja elektrode privremenog pejsmejkera. *Acta Medica Medianae 2011;50(3):54-57.*

Ključne reči: *perzistentna vena cava superior, elektroda privremenog pejsmejkera*