

## CONTEMPORARY PRINCIPLES FOR CHOLECYSTITIS TREATMENT WITH LAPAROSCOPIC TECHNIQUE

Slobodan Arandjelović<sup>1,2</sup>, Ljiljana Jeremić<sup>3,4</sup>, Milan Radojković<sup>3,4</sup>,  
Marko Gmijović<sup>3</sup>, Ilija Golubović<sup>3</sup>

The first laparoscopic cholecystectomy (LC) was performed in France in 1987 by a French surgeon (P. Mouret), and it rapidly became accepted until the end of the nineties in Europe and America as a "gold standard" in the treatment of the gallbladder.

"There are just a few examples in the history of surgery, where the advantage of some surgical techniques is so quickly imposed, as it is in the case of laparoscopic cholecystectomy" (Cusshieri). Assuming the present of a surgical skill and experience, well-trained team and the specific technical equipment, the main advantages of this surgical method are less operative trauma and postoperative pain, faster recovery and a shorter hospital stay. The percentage of conversion to open cholecystectomy is 2%-20% and it is caused by certain conditions, such as older age, morbid obesity, and expressed inflammation of gallbladder and biliary anatomical anomalies. Male gender, anatomical variations, previous abdominal operations and technical problems, were rarer causes of conversion. Non-compliance and non-recognition of these risk factors can lead to complications, most notably the common bile duct injuries. At the Surgical Clinic in Nis, in the period of 3 years (January 2010 to November 2013) 1.389 patients with symptomatic cholelithiasis underwent surgery, 626 (45,1%) using standard techniques of laparoscopic method. Most patients, 60,10%, were female and 39,90% were male. Chronic calculous cholecystitis was an indication of the 86,20%, 8,50% in the acute, gallbladder polyp 5,30%. Conversion was forced out in 28 patients (4.47%). There have been no lethal operative outcomes in observed period, intraoperative lesions of vascular structures were not notified, total specific morbidity was about 2,07%.

The technical aspect is still dominant at laparoscopic cholecystectomy (LC). Outstanding results at our clinic and in the world, impose the need for further development of this method, education of surgeons and staff, with the aim of reducing the percentage of contraindications and technical barriers to a minimum. *Acta Medica Medianae* 2016;55(1):5-13.

**Key words:** cholecystitis, laparoscopic cholecystectomy

Surgery Clinic, Clinical Hospital Center Priština, Gračanica, Srbija<sup>1</sup>  
Faculty of Medicine Priština, Kosovska Mitrovica, Serbia<sup>2</sup>  
Surgery Clinic, Clinical Center Niš, Srbija<sup>3</sup>  
University of Niš, Faculty of Medicine, Niš, Serbia<sup>4</sup>

Contact: Slobodan Arandjelović  
Medicinski fakultet u Prištini  
Kosovska Mitrovica, Srbija  
meil: slobodan.arandjelovic@med.pr.ac.rs

flammation of gallbladder and biliary anatomical anomalies. Male gender, anatomic variations, previous abdominal operations and technical problems, rarely are the causes of conversion. Failure to follow and non-recognition of these risk factors can lead to complications, most notably is the common bile duct injuries.

### Introduction

Laparoscopic cholecystectomy (LH) is the gold standard in surgical treatment of benign gallbladder. Assuming that the surgical skills and experience, well-trained team and the specific technical equipment are present, the main advantages of this surgical method are less operative trauma and postoperative pain, faster recovery and a shorter hospital retention. The percentage of conversion to open cholecystectomy (OC) is 2%-20% and is caused by certain conditions, such as older age, morbid obesity, and expressed in-

### History

The history of laparoscopic surgery, endoscopy begins in the early 19th century, when, in 1805, Bozzini constructed a cumbersome tube that had a candle as a light source and gasogene lamp (A.J. Desormeaux 1843). Using Edison's invention of the incandescent bulb (1879), which converted only 3% of the energy into light and the rest into heat, did not solve the most important problems of endoscopy: adequate lighting and open-cavity procedures.

The term "Laparoscopy" dates back to 1910, initially introduced by Hans Christian Jacobaeus who performed the endoscopic diagnostic examinations of peritoneal, pericardial and pleural cavities in humans, using the experience of Professor Georg Kelling who examined the peritoneal cavity of a dog. Further development of endoscopy in the diagnostic and therapeutic purposes, as well as laparoscopic surgery, was caused by technical and technological progress throughout the twentieth century, when together with the improvement of the system of optics, and image transfer, transfer technology and bright lighting were developed as well.

During the 1960's, the most significant contribution to endoscopy came from the British physicist Harold H. Hopkins with the invention of a rod-lens optical system and the fiber-optic cable which even today forms the basis of modern endoscope.

The introduction of strong external halogen and xenon light sources into clinical practice definitely solved the problem of the source and transmission of light, which in the second half of the 20th century allowed endoscopy to become dominant in internist diagnostic and therapeutic procedure.

Laparoscopic surgery, was long unable to win the status of a routine procedure, due to the problems of adequate exposure of intraperitoneal organs. This problem is solved by introducing techniques to create pneumoperitoneum, by injecting air into the abdominal cavity, making it possible to raise the anterior abdominal wall and secure access to intraperitoneal organs. Richard Zollikofer, a Swiss gynecologist, was one of the first to recognize the benefits of using carbon dioxide, as a non-flammable, non-toxic, colorless gas that can be easily eliminated from the body, optimal to create pneumoperitoneum in laparoscopies. CO<sub>2</sub> insufflation is performed through a special needle with a spring, which was introduced into clinical practice by Hungarians J. Veress-a (primarily used in the treatment of pulmonary tuberculosis). At the end of the last century, the appliance was designed for automatic gas insufflation according to the assigned pressure. However the most significant milestone in the development of modern laparoscopic surgery was a development of video-endoscopy. Fiber optic and video technology have enabled the use of both hands, conditions for active participation of assistants and rapid development of laparoscopic surgery and performance of increasingly complex operational procedures in the abdomen and thorax. Its full significance laparoscopy gets in biliary surgery, which very quickly becomes "gold standard" in the treatment of benign gallbladder diseases. "There are few examples in the history of surgery, where the advantage of some surgical techniques was so quickly imposed, as in the case of laparoscopic cholecystectomy" (Cusshieri). In 1981, Kurt Semm, a German gynecologist performed the first laparoscopic appendectomy. Inspired by the results, a German surgeon Enrich Muche came up with ideas about laparoscopic cholecystectomy.

Mucha created "galoscop", a laparoscope which performed the first laparoscopic cholecystectomy on 12. September 1985. Pleased with the success of the operation, perfecting this technique, he created new instruments, performing with or without pneumoperitoneum. On April 1986, he explained his experience at the annual congress of the German Surgeon Association, where he was accepted with reserve and ridicule. Only a decade later, surgical public recognized his work and marked him as a surgeon who performed the first laparoscopic cholecystectomy.

Until then, this significant recognition, belonged to a French surgeon Philippe Mouret, who almost at the same time (1987), also by using the experience of a gynecologist, performed the laparoscopic cholecystectomy. The patient was a woman of about 50 years. His work and enthusiasm very quickly supported Professors F. Dubois and J. Perissat. Thanks to their joint work and good results, but also to the development of video technology, LH was rapidly accepted by surgeons and patients in Europe and then in America. General surgeon B. Mc Kernan and gynecologist W. Saye first performed LH in America in 1988. At the beginning of the 90s, LH became an integral part of general education of surgeons. Laparoscopy is not only a new surgical technique, but also a new way of thinking and approaching to problems in general surgery.

### **Pathophysiology of laparoscopy**

Laparoscopy is a minimally invasive procedure, because of less surgical trauma and faster postoperative recovery.

However, this procedure is characterized by potentially serious pathophysiological consequences, mainly caused by the artificially created pneumoperitoneum or insufflation gas CO<sub>2</sub>, which inevitably develops bigger or smaller form of abdominal compartments syndrome (decrease venous inflow to the heart, depression of a systemic circulation, depression of ventilation, reduction in renal perfusion and increase in intracranial pressure). In addition, the position of the patient, and the anti-Trendelenburg position that facilitates performing of LH, can adversely affect the cardiovascular system, as well as the development of nerve compression syndromes.

In addition to the already existing previous conditions, which lead to an increase in intra-abdominal pressure (obesity, abdominal wall compliance, state solid and hollow intra-abdominal organs, the presence of adhesions or expansive process in the abdominal cavity), there is a development of possible complications affecting several etiological factors, which are closely related to this surgical technique.

Pathophysiological effects on the respiratory system are the result of two mechanisms of action: suppression diaphragm pneumoperitoneum and uptake of CO<sub>2</sub> by the peritoneum. During laparoscopy, decreasing lung compliance and vital lung capacity are occurring. On the other hand,

insufflated CO<sub>2</sub> is in his highest percentage delivered to the lungs, where it is eliminated in the alveoli and where it can cause the increase in pCO<sub>2</sub> in blood and acidosis. In healthy patients, hyperventilation is sufficient to regulate the present hypercapnia. The risk is present in patients with comorbid conditions, such as chronic obstructive lung disease - COLD, cardiomyopathy, septic patients.

Pathophysiological effects of laparoscopic surgery on cardiovascular system, usage of standard values of gas pressure in the abdomen (12-15mmHg), are largely tolerated by healthy individuals. However, in patients with compromised compensatory mechanisms, effects of pneumoperitoneum can cause serious problems and acute complications, such as an acute myocardial infarction. As a result of an increase in intra-abdominal pressure, there is an increase in CVP (central venous pressure), CP (capillary pressure), MAP (mean arterial pressure), SVR (systemic vascular resistance). Such patients require careful preoperative preparation and preoperative monitoring for quick correction of any disorder. In addition, the position of the patient, or the prolonged anti-Trendelenburg position, favoring venous stasis in the lower extremities, increase the risk of deep vein thrombosis. However, the rapid mobilization of patients after laparoscopy and the restore of life activities, less activation of the coagulation system due to less surgical trauma, greatly reduces the risk of thrombosis and pulmonary embolism, and anticoagulation prophylaxis, indicating the same risk groups, as well as in open surgery

Pathophysiological effects on the kidneys, are not permanent and are very tolerant. Due to intra-abdominal hypertension, there is hypoperfusion of the kidneys and transient oliguria. Adequate compensation of fluids and electrolytes are preventing any long-term consequences of these processes.

Pathophysiological effects on the intestine, are lower than in the open, conventional surgery, due to less surgical trauma and lower sympathetic response that suppresses intestinal motility.

Pathophysiological effects on the central nervous system, may be negative in patients with previous injuries or surgery on the brain due to increased intracranial pressure, qualifying pneumoperitoneum.

Pathophysiological effects on the immune system. In relation to open surgery, laparoscopy causes lower operating stress with a lower degree of activation of immune suppressive mechanisms.

Although laparoscopic procedure constitutes a surgical and anesthesiologist challenge, its pathophysiological effects to a large extent are annulled by postoperative effects: operative less trauma, less postoperative pain and complications, faster mobilization and rapid return of the patient's to the full of life activities.

## Technical aspects of laparoscopy

All laparoscopic surgeries, including LH, require specific surgical skill and experience, the experience of the team, and the technical equipment, which represents the dominant aspect of this procedure. Perfect or imperfect techniques during LH, make the difference between a safe and expeditious procedures and a long and difficult operation for the surgeon and for the patient, coupled with the risk of severe complications.

Operating room intended for laparoscopic procedures (so-called. "Endo hall"), has a mobile carrier of laparoscopic equipment and monitors which enable fast accommodation of the patient, type of surgery, and all team members. Placing the patient in an appropriate position, such as an anti-trendelenburg position, and a position-change, if necessary during the operation, is enabled thanks to modern, moving, operating table.

The basic equipment for performing laparoscopic LH includes:

- Optics, consisting of:
  - a laparoscope or a telescope, which is the basic laparoscopic instrument with Rod Lens System, which can be of various sizes (10mm, 5mm) and at different angles (0, 30 or 45 degrees)
  - source of the white light (xenon and halogen lamps) and a fiber optic cable, which conducts the light from the source, through the laparoscope, to the inside of the abdomen.
  - Video Camera (single chip or three-chip) and a TV monitor high resolution.
- gas-insufflation, which automatically injects CO<sub>2</sub> into the interior of the abdomen, to a set pressure which is 12 to 15 mmHg at a rate of about 2 L / min. Gas is injected into the abdominal cavity through a so called Veress's needle (needle with a retaining spring) . "Closed technique" which is reserved for patients with an intact stomach (without previous operations and possible adhesions).After placing the patient in the left lateral position of 20-30 degrees, through the incision of 10-12mm directly below the navel is placed the Veress needle, through which, after checking it is in the correct position, gas is inserted in the stomach. In patients with previous abdominal surgery, so-called. "Open" or Hasson's technique is used and it involves an incision of 15-20mm, all layers of the stomach to the peritoneum, which is opened under the control of the eye. After checking the digital presence of adhesions in the abdomen, Hasson's cannula or trocar with a rounded top is placed through which then performs the insufflation gas.
- Laparoscopic Instruments: The main instruments for LH are 30-40cm long, with a diameter of 5 to 10mm. These are atraumatic grasper (holders), for compliance with the gallbladder, then real or curved dissectors (basic for dissection and exposition of any vascular elements), curved or right scissors. Clip-applicators, automatic or semi-automatic instruments, which are used for application of titanium clips , used to ligate tubular structure apropos cisticus duct or cistic artery, after their careful identification and dissection , which is

the most delicate part of LH, during which can be injured the common biliar duct or artery of the region. In addition, the main group of instruments for performing LH includes monopolar electrocauter or "hook", an instrument which requires careful handling and is used (after ligation of biliar and vascular elements and after identifying elements of hepato-duodenal ligament), under the control of the eye, dissection ("separation") of gallbladder from its lodge from the liver parenchyma. Extractor, is also one of the basic instruments, (rinsing and aspiration), with extractor surgeon maintains visibility of the operative field.

In addition to these basic instruments, laparoscopic cholecystectomy set can contain and bipolar forceps and scissors, linear stapler, retractors for conformation liver, ultracision or harmonic scalpels (performing dissection and coagulation at the same time). The usage of this accessory depends largely on the financial possibilities of center, as well as the experience and affinities of the surgeon to certain instruments.

### **Advantages of laparoscopic cholecystectomy**

LH represents the minimum invasive method of choice in the surgical treatment of benign gallbladder diseases, fully accepted by surgeons and patients. The basic advantages of this procedure compared to traditional, are smaller operational stress and trauma:

- Minimum laparotomy or incision in the front abdominal wall are responsible for less post-operative pain and faster recovery of the patient.

- Smaller operative trauma and reduced immunosuppression are responsible for minimal use of drug therapy after surgery.

- Limited Exposure of the intra-abdominal organs to the external environment and possible contamination reduce the risk of systemic infections.

Also the percentage of infection of operative wound is kept to a minimum, and the esthetic results are excellent.

- The smaller Invasiveness of the procedure is causing minor bleeding, and intra and postoperative blood transfusion at this intervention is extremely rare (except in case of complications).

- Due to the reduced sympathetic response during the LH, postoperative bowel motility and per os feeding of the patient is established more quickly (in most cases, several hours after the surgery).

- The short time of hospitalization, in addition to the financial benefits, especially are important for the patient, who is very rapidly mobilized and returned to all of life's activities.

### **Incidents and complications of laparoscopic cholecystectomy**

During the last 30 years LH has replaced the classic-open cholecystectomy. However, despite the development of technology, significant and cumulative experience of surgical teams and their organization, LH is accompanied by a certain percentage of incidents and complications, some

of which are certain complications (such as injury of the biliar ducts), occurring at higher rates than in the open technique.

Strict compliance with the rules, as well as knowledge of risk factors prevent intra and post-operative complications. Early identification of "heavy" cholecystectomy, indicates conversion to an open technique, which is going to different batches of the 2% to 20% of cases.

### **Contraindications:**

Although it is now considered that there is no abdominal operation that we can not perform with laparoscopic technique, there are some contraindications to performing LH, such as advanced disease of the respiratory system and CVS (risk of decompensation due to pneumoperitoneum), followed by septic conditions and peritonitis, advanced pregnancy, as well as a proven malignant tumors of the gallbladder, which along with cholecystectomy, require extensive surgical resection of this region.

Gangrenous cholecystitis, micro gallbladder, pericholecystitis, fibrosis, curled gallbladder, liver chirosis (with strong regenerative nodules in the lodge of the gall bladder and / or portal hypertension), are relative contraindications, or conditions when LH is performed with difficulty and caution, with higher percentage of conversion to classic cholecystectomy. These are complex procedures, in which surgeons' experience and appropriate technical equipment play an important role.

Expressed obesity in some cases may be the cause of severe LH, (difficult dissection due to fatty infiltration, a lack of long laparoscopic instruments). According to some authors, isolated obesity in a patient does not constitute contraindications, however, associated with other risk factors such as previous surgery in the abdomen, expressed inflammation of the gall bladder, the presence of adhesions, can cause severe LH, with an increased risk for conversion to OH. However, comparing the results of post-operative laparoscopic cholecystectomy and classical, in relation to wound infection, dehiscence, and the subsequent appearance of ventral hernias, obese patients have a greater benefit than those of LH.

Cholelithiasis is not a contraindication for the performance of LH, but it is a pathological condition that requires a lot of experience of surgeons and appropriate technical support. First of all, Cholelithiasis need to be recognized preoperatively (history, jaundice, various diagnostic procedures) or intraoperatively, with exploration of common biliar duct, intraoperative cholangiography (IOH). IOH in LH is performed in the highest percentage with transcystical access, with specialized catheters, which are placed over the front abdominal wall of right hypochondrium, the millimeter ports. Exiting cholelithiasis is solved transcystically or through choledochotomy, with the help of choledochoscope, lavage of bile ducts, Dormia probes with "little basket" or if it is safe, pushing stones into the duodenum. In certain cases there is so-called running "Rendez vous" technique, dur-

ing which, at the same is performed LH and endoscopic papillotomy.

Complications of LH may be early or late.

Basic early complications in LH are the common biliar duct injuries, bleeding and abscess of subhepatic region. The emergency biloma, biliary peritonitis or biliary fistula, are the result of failure or falling clip from cystic duct (more often with LH than in open), non-recognition and not clamping a (Luchka) duct (present in 3-5% of the general population) or unrecognized lesions. Solving the treatment of biliary peritonitis or fistula, depends on the type of injury, its extent, the presence or absence of drainage, eventual rest stones in biliar duct and may be conservative, endoscopic or classical surgical reintervention.

The most serious problem in LH, is injury of main bilirad duct (1% vs 0.5%). It is believed that the two main causes higher percentage of these lesions during LH, unclear anatomy (which is especially present in acute cholecystitis) and lack of experience of the surgeon (the highest percentage of injuries occurs during the first 10-15 cholecystectomy one surgeon). Bleeding during the operation of the lodge of gallbladder or cystic artery were devised and hepatic artery, is one of the complications that can lead to conversion. Most often occurs in acute cholecystitis, fibrotic gallbladder and liver cirrhosis. Bleeding itself in the highest percentage, is not a serious problem, as far as it can result from uncontrolled reactions of surgeon: excessive and blind use of the clip or electrocautery, surgeon can affect biliary elements or deteriorate them, primarily minimal bleeding or injury.

Abscess collections in gallbladder lodge occur in a slightly higher percentage after the LH and result of bleeding or biliary fistula. Typically, the present 7-10 days after surgery, fever, high leukocyte count, pain below the right costal angle in the highest percentage can be solved by percutan drainage controlled by ultrasound or CT.

Due to the above, it is very important to:

- Recognize the risk in situation (difficult cholecystitis, fibrotic curled gall bladder, altered and unidentified anatomical elements);
- Respect the Rules in operation techniques (exposure Calot's triangle, without excessive traction fundus of the gallbladder, ligature of bilo-vascular elements, following the identification of all the elements and the common bile duct, section elements as close to the gallbladder);
  - IOH (if anatomy is unclear, and if our technical capability to allow);
  - Make the Conversion if the operation does not progress or if we can not identify all the anatomical features of this region.
  - Late complications described after LH are rest calculus of main biliar duct which is present in the same percentage as for open cholecystectomy. At the second place is the hernia at the site of the umbilical port, usually after infection in the region or after extraction of large stones transumbilical.

Besides the above mentioned complications related to LH, there are also complications that are specific to any laparoscopic procedure, and are related to risk entering the abdominal cavity, created pneumoperitoneum, limited visibility and difficulty in manipulating instruments (internal injuries, major blood vessels, pneumothorax, pneumomediastinum, gas embolism). They occur very rarely (0.02% to 0.3%) and to a large extent depend on the experience and prudence of surgeons, as well as careful preoperative patient.

### Laparoscopic cholecystectomy in the future

Laparoscopic cholecystectomy is accepted with good spirit by the surgeons and the patients, immediately after introduction into clinical practice at the 80s of the last century, LH constantly oversee the rapid development of science and technology in the direction as a minimal surgical trauma.

More recently, the results of new endoscopic surgical techniques, such as the SILS (Single Incision Surgery laparoscopic) NOTES (Natural Orifice transluminal endoscopic surgery) and robotic cholecystectomy (RH).

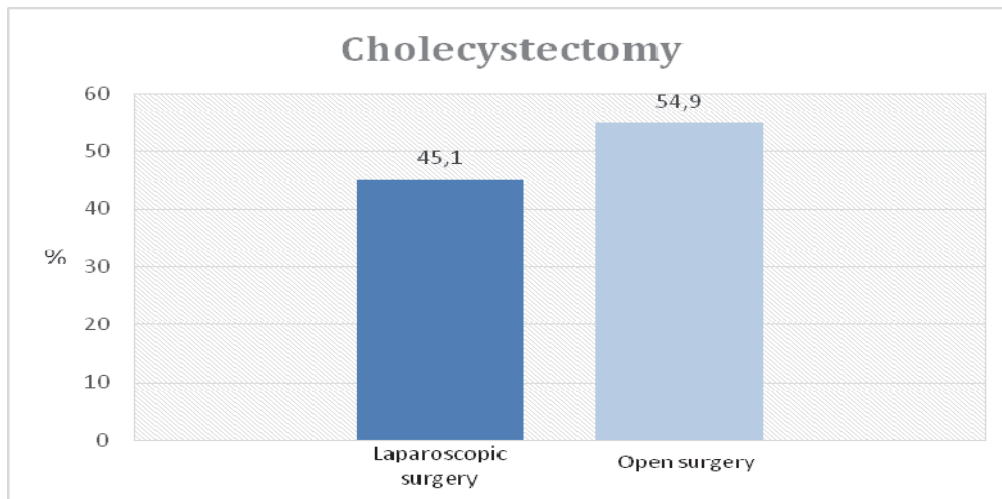
SILS represents LH, done with curved, flexible endoscop, through transumbilical port. The first attempt of cholecystectomy through a unique upper umbilical port was performed by Navarra et al. in 1997 year. Since then, until today, many authors have presented their experiences, suggesting that in addition to better cosmetic results, SILS shows no advantages compared to traditional (multi-port) LH, in terms of complications and postoperative course. Because it is more expensive and longer procedure than multi-port, for now it is accepted only by the individual centers, as a possible alternative to LH. (Sfieh, Muhmad and other ....)

NOTES cholecystectomy, made with flexible endoscop through natural cavities (transvaginal), although successfully implemented by some authors, is now a subject of scientific and ethical debate, with a view to determining clear indications, risks, benefits and the price of these new surgical techniques.

RH is one of modern minimally invasive approach to this pathology, whose main problem is price. Proponents of this operative technique believe that the further development of technology and the accumulation of knowledge and experience, the price of these methods will be closer to the price of classical LH, becoming its alternative in the near future.

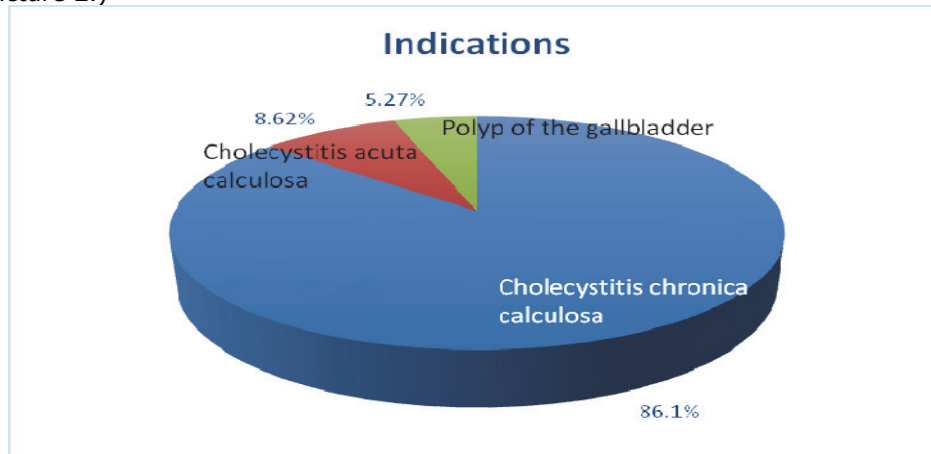
### Our results

Surgical Clinic in Nis, in the period of 3 years (from January 2010 to November 2013.) had 1,389 patient with cholecystitis who were operated, 626 patient (45.1%) underwent laparoscopic technique. (Picture 1)



Picture 1. Total number of cholecystectomies done during a 3 year period: comparison between laparoscopic and open technique

60.10% of the patients were females; 39.90% of the patients were males. Chronical cholecystitis was an indication of the 86.10% (539), and acute in 8.62% (54), gallbladder polyp was in 5.27% (33 patients). (Picture 2.)



Picture 2. Indications for laparoscopic cholecystectomy

All patients were operated by 5 surgeons, using the same set of laparoscopy, the same technique: blunt dissection bilo-vascular elements with curved dissector, ligation of the cystic duct and cystic artery with titanium clips, and dissection of the gallbladder from its Lodge with monopolar hook. In 79.52% (497) of the patients, the operation was completed with drainage of subhepatic space. IOH was never done, except in the cases where we converted operation to the open surgery. The operation lasted from 45 to 71min, significantly extended with the complex pathological substrates (expressed inflammation, adhesions) and in patient with solitary large stones (average 51.3 minutes).

The average duration of postoperative hospitalization was 27h.

Conversion is done in 28 patients (4.47%). The largest number of patients with LH should be converted into an open cholecystectomy, was in the group with chronic inflammation (21 patients, or 3:35% of total), or with complex pathomorphological substrate, as expressed inflammation and / or the presence of adhesions or fistula with the surrounding organs, without the possibility of secure identification and remediation of all anatomical structures in the region. At 7 (1.12%) patients, the conversion is done for extant acute inflammation, such as empyema, gangrene or perforation of the gall bladder. In benign tumors of the gallbladder (polyps), the conversion was not done.

Table 1. Percentage of conversion from laparoscopic to open cholecystectomy, related to indications

Diagnosis	Number of patients	Percentage(%)
Chronic cholecystit	21	3.35
Acute inflammation (empiem, gangrene, perforation of gallbladder)	7	1.12
Benign gallbladder tumors (polyps)	0	0.00

Creating pneumoperitoneum open Hesson's technique was performed in 31 patients (4.95%), due to the difficult access to the abdominal cavity. In 20 patients there was an expressed obesity, in 11 patients there was the previous laparotomy in lower parts of the abdomen. In all patients pneumoperitoneum was performed without incident and without conversion. There were no Intraoperative lesions of bilio-vascular structures, in the teeth existing variations of cistic artery at 15.00%, and hepatics artery in 3.00% of cases. Luchkin aceptor line was detected in 5 (0.79%) patients during the same LH, and than it is ligated.

In 11 patients (1.75%) was detected minimal postoperative biliary fistula, no free fluid in the abdomen and without disturbance of the general condition. All patients were treated conservatively to complete remediation. In 2 patients (0.32%), there was considerable productive biliary fistula, because the clip fell off the part of ductus cisticus. In both patients reintervention was performed, on 5th and 7th postoperative day, In one patient was found preoperatively unrecognized calculus in the distal parts of choledoch. Total specific morbidity rate reached 2.07%. Postoperative mortality was 0.00%.

Table 2. Total specific mortality and morbidity

Variables	Number of patients	Percentage (%)
Intraoperative lesions	0	0
Minimal billiary fistula	11	1.75
Productive billiary fistula	2	0.32
TOTAL SPECIFIC POSTOPERATIVE MORTALITY	13	2.07
TOTAL NONSPECIFIC POSTOPERATIVE MORTALITY	0	0.00

## Discussion

Cholecystectomy is one of the most common operations in digestive surgery. Laparoscopic technique is the gold standard in surgical treatment of gallbladder disease and accounts for about 90% of all derivative cholecystectomy in the world. It is a minimally invasive procedure, fully accepted by surgeons and patients; operative stress and trauma are lower with this technique.

The principal complications of LH are the common biliar duct injuries, bleeding and abscess of the liver region, appearance of biloma, biliary peritonitis and biliar fistula which occur to different batches, 0.5 to 6% of the cases (2.07% in our study). The most serious problem of LH is the injury of main biliar duct (1% vs 0.5%) which is higher than in open surgery .It is believed that the two main causes occur in slightly higher percentage of these lesions during the LH, the specificity of the vision of the operative field (lack of a third dimension and tactile sensation), and the lack of experience of the surgeon. The highest percentage of injuries occurs during the first 10-15 cholecystectomy one surgeon, while the percentage of conversion LH in OH down from 17% in the first 100 operations, at 4% after 500 and more LH. It was also determined that the smallest percentage of complications and conversions present in the surgeon, whose training in laparoscopic surgery started early, during the first days of specialist training.

Conversion LH in OH, according to data from literauture, ranges from 2% to 20% (in our study, 4.47%), depending on the seriousness of the operation, the surgeon experience and technical conditions. Identification of early and intraoperative risk factors for conversion, as well as the timely recognition of "heavy" cholecystectomy, is a fundamental requirement of preventing complications that can occur during surgery. The most common reason for conversion is impossibility of

anatomical orientation and secure identification of all elements of the region (50.0%), which is generally the case with the expressed inflammation of the gallbladder, with the presence of adhesions. In a smaller percentage, reason for conversion may be technical difficulties, and some authors have demonstrated that the number of conversion from LH to OH, more than 4 times greater in poorer societies, where the laparoscopy performed with older instruments and equipment. In our series, there was no conversion due to technical difficulties.

A larger number of authors deal with the creation of the scoring system in order to identify patients with risk of intraoperative complications and conversion from LH to OH. Mittalgodu et al.(2014) created a scoring system of 20 elements, where anomalies of biliar duct, adhesions, fibrotic or distended gallbladder and male gender, are the most important predictive factors, score more than 9 points predict difficult operation and it is risk of "serious" cholecystectomy. Nikihil et al.(2015) suggest that clinically palpable gallbladder, pericholecystitis, impacted large calculus, previous surgery, are strong factors for complicated LH, with the risk of complications and conversions.

## Conclusion

Since its introduction into clinical practice to date, LH is still being constantly developed and today in many centers in the world accounts for 90% of all derivative cholecystectomy. Some time ago, an experienced surgeon who was a rarity, is now an integral and mandatory part of the training of young surgeons from the beginning of specialization.

The technical aspect is still very important in LH. The development of laparoscopy instruments and equipment closely follow the develop-

ment of science and technology in order to provide safer performing of operational techniques.

Outstanding results at our clinic and in the world, impose the requisite for further develop-

ment of this method, modernization and education of surgeon and staff, with the aim of reducing the percentage of contraindications and technical barriers to a minimum.

## References

- Jeremić M. Hirurgija žučnih puteva. In: Jeremić M, editor. Specijalna hirurgija 1, dijagnostika i terapija. Niš. Univerzitet u Nišu, Medicinski fakultet; 2001. p.14/1-14/5.
- Brown TH, Irving MH, editors. Introduction to Minimal Access Surgery. London: BMJ Publishing Group; 1995.
- Cuschieri A, Buess G, Perissat J. Operative manual of Endoscopic surgery. 2nd ed. Berlin: Springer-Verlag; 1994.
- ME Arregui, Fitzgibbons RJJ, Katkhouda N, McKernan JB, Reich H, editors. Principles of laparoscopic Surgery. Basic and advanced techniques. Berlin: Springer-Verlag; 1995. [[CrossRef](#)]
- Čolović R. Operacije na bilijarnom traktu. In: Čolović R, editor. Hirurgija bilijarnog trakta. Beograd: Zavod za udzbenike i nastavna sredstva; 1998. p. 331-68.
- Čolović R. Sudskomedicinski aspekti operativnih povreda žučnih vodova. Vojnosanit Pregl 2010; 67(2): 176-9.
- Archer SB, Brown DW, Smith CD, Branum GD, Hunter JG. Bile Duct Injury During Laparoscopic Cholecystectomy: Results of a National Survey. Ann Surg 2001. 234(4): 549-58. [[CrossRef](#)] [[PubMed](#)]
- Spaner SJ, Warnock GL. A brief history of endoscopy, laparoscopy, and laparoscopic surgery. J Laparoendosc Adv S 1997;7(6):369-73. [[CrossRef](#)] [[PubMed](#)]
- Vecchio R, MacFayden BV, Palazzo F. History of laparoscopic surgery. Panminerva Med 2000;42(1):87-90. [[PubMed](#)]
- Nagy AG, Poulin EC, Girotti MJ, Litwin DE, Mamazza J. History of laparoscopic surgery. Can J Surg 1992; 35(3):271-4. [[PubMed](#)]
- Loder WA, Minnich M, Brotman S. Hemodynamic effects of laparoscopic cholecystectomy. Am Surg 1994; 60(5):322-5. [[PubMed](#)]
- Westebbring-van der Putten EP, Goossens RH, Jakimowicz JJ, Dankelman J. Haptics in Minimally Invasive Surgery – A Review. Minim Invasiv Ther 2008;17(1):3-16. [[CrossRef](#)] [[PubMed](#)]
- Beltramo M, Henussi G, Cazzaniga M, Fraquelli M. Cholecystectomy with laparoscopy and laparotomy. Analysis of the complications. Minerva-Chir 1995; 50(7-8): 627-31. [[PubMed](#)]
- Carey LC. Cholecystectomy-a new standard. Ann Surg 1992;216(6):617. [[CrossRef](#)] [[PubMed](#)]
- Constant E, Janssen P, Nys JM, el Fouly PE, Lemmens F, Hachez L, Hauters P. Prospective analysis of 192 consecutive cholecystectomies: a comparative study between laparoscopy and laparotomy. Acta Chir Belg 1995; 95(6): 254-60. [[PubMed](#)]
- Deziel DJ, Millikan KW, Economou SG, Doolas A, Ko ST, Airan MC. Complications of laparoscopic cholecystectomy: a national survey of 4292 hospitals and an analysis of 77 604 cases. Am J Surg 1993;165(1):9-14. [[CrossRef](#)] [[PubMed](#)]
- Tucker JJ, Yanagawa F, Grim R, Bell T, Ahuja V. Laparoscopic cholecystectomy is safe but underused in the elderly. Am Surg 2011;77(8):1014-20. [[PubMed](#)]
- Hussain A. Difficult laparoscopic cholecystectomy: current evidence and strategies of management. Surg Laparo Endo Per 2011;21(4):211-7. [[CrossRef](#)] [[PubMed](#)]
- Collet D, Edye M, Magne E, Perissat J. Laparoscopic cholecystectomy in the obese patient. Surg Endosc 1992;6(4):186-8. [[CrossRef](#)] [[PubMed](#)]
- Angrisani L, Lorenzo M, De Palma G, Sivero L, Cantanzano C, Tesauro B, Persico G. Laparoscopic cholecystectomy in obese patients compared with nonobese patients. Surg Laparosc Endosc 1995;5(3):197-201. [[PubMed](#)]
- Horwood J, Akbar F, Davis K, Morgan R. Prospective evaluation of a selective approach to cholangiography for suspected common bile duct stones. Ann Roy Coll Surg 2010;92(3):206-10. [[CrossRef](#)] [[PubMed](#)]
- Uragami A, Matsumoto H, Yamashita K, Hirai T, Tsunoda T. Results of questionnaire surveys at several affiliated institutions regarding intraoperative biliary tract injuries. Tando J Jpn Biliary Assoc 2005;19:299.
- Podolsky ER, Rottman SJ, Curcillo PG 2nd. Single Port Access (SPA) Cholecystectomy: Two Year Follow-up. JSLS 2009;13(4):528-35. [[CrossRef](#)] [[PubMed](#)]
- Navarra G, Pozza E, Occhionorelli S, Carcoforo P, Donini L. One-wound laparoscopic cholecystectomy. Br J Surg 1997;84(5):695. [[CrossRef](#)] [[PubMed](#)]
- Markar SR, Karthikesalingam A, Thrumurthy S, Muirhead L, Kinross J, Paraskeva P. Single-incision laparoscopic surgery (SILS) vs. conventional multiport cholecystectomy: systematic review and meta-analysis. Surg Endosc 2012;26(5):1205-13. [[CrossRef](#)] [[PubMed](#)]
- Arulampalam T, Paterson-Brown S, Morris AJ, Parker MC. Natural Orifice Transluminal Endoscopic Surgery. Ann Roy Coll Surg 2009; 91(6):456-9. [[CrossRef](#)] [[PubMed](#)]
- Breitenstein S, Nocito A, Puhan M, Held U, Weber M, Clavien PA. Robotic-assisted versus laparoscopic cholecystectomy: outcome and cost analyses of a case-matched control study. Ann Surg 2008;247(6):987-93. [[CrossRef](#)] [[PubMed](#)]
- Liu CL, Fan ST, Lai EC, Lo CM, Chu KM. Factors affecting conversion of laparoscopic cholecystectomy to open surgery. Arch Surg 1996; 131: 98-101. [[CrossRef](#)] [[PubMed](#)]
- Tang B, Cuschieri A. Conversions during laparoscopic cholecystectomy: risk factors and effects on patient outcome. J Gastrointest Surg 2006;10(7):1081-91. [[CrossRef](#)] [[PubMed](#)]
- Bohacek L, Pace DE. Advanced laparoscopic training and outcomes in laparoscopic cholecystectomy. Can J Surg 2009;52(4):291-4. [[PubMed](#)]
- Jaffary SA, Shamim MS, Razza SJ, Dastagir A. Instrument failure: A Preventable cause of conver-



- sion in laparoscopic cholecystectomy. Pak J Surg 2007;23:92-5.
32. Frazee RC, Roberts JW, Symmond R, Snyder SK, Hendricks J, Smith R, Custer MD. What are the contraindications for laparoscopic cholecystectomy? Am J Surg 1992;164(5):491-4. [\[CrossRef\]](#) [\[PubMed\]](#)
33. Agrawal N, Singh S, Khichy S. Preoperative Prediction of Difficult Laparoscopic Cholecystectomy: A Scoring Method. Niger J Surg 2015;21(2):130-3. [\[CrossRef\]](#) [\[PubMed\]](#)
34. Vivek MA, Augustine AJ, Rao R. A comprehensive predictive scoring method for difficult laparoscopic cholecystectomy. J Minim Access Surg 2014;10(2):62-7. [\[CrossRef\]](#) [\[PubMed\]](#)

**Originalni članak**

**UDC: 616.366-002-089.87(043.3)**  
**doi: 10.5633/amm.2016.0101**

## SAVREMENI PRINCIPJI LEČENJA HOLECISTITA LAPAROSKOPSKOM TEHNIKOM

*Slobodan Arandjelović<sup>1,2</sup>, Ljiljana Jeremić<sup>3,4</sup>, Milan Radojković<sup>3,4</sup>,  
Marko Gmijović<sup>3</sup>, Ilija Golubović<sup>3</sup>*

Hirurška klinika, Kliničko-bolnički centar Priština, Gračanica, Srbija<sup>1</sup>  
 Medicinski fakultet Priština, Kosovska Mitrovica, Srbija<sup>2</sup>  
 Hirurška klinika, Klinički centar Niš, Srbija<sup>3</sup>  
 Univerzitet u Nišu, Medicinski fakultet, Niš, Serbia<sup>4</sup>

Kontakt: Slobodan Arandjelović  
 Medicinski fakultet u Prištini  
 Kosovska Mitrovica, Srbija  
 mail: slobodan.arandjelovic@med.pr.ac.rs

Prva laparoskopjska holecistektomije (LH) izvedena je 1987. god. od strane francuskih hirurga (P. Mouret), od kada rapidno postaje prihvaćena do kraja devedestih godina u Evropi i Americi, te postaje "zlatni standard" u lečenju benignih bolesti žučne kese. "Malo je primera u istoriji hirurgije, gde se prednost jedne hirurške tehnike tako brzo nametnula, kao u slučaju laparoskopjske holecistektomije" (Cusshieri). Podrazumevajući hiruršku veštinu i iskustvo, uigranost tima i specifičnu tehničku opremu, osnovne prednosti ove hirurške metode su manja operativna trauma i postoperativni bolovi, brži oporavak i kraće trajanje hospitalizacije. Procenat konverzija, odnosno prevodjenja laparoskopjske u klasičnu, otvorenu holecistektomiju je 2% do 20% i uslovljen je odredjenim uslovima, kao što su starije životno doba, patološka gojaznost, kao i izražena inflamcija žučne kese i anatomske anomalije bilijarnog stabla. Muški pol, prethodne operacije u trbuhu i tehnički problemi, su redji uzroci konverzije. Nepoštovanje i neprepoznavanje ovih faktora rizika, može dovesti do komplikacija, od kojih je najznačajnija povreda glavnog žučnog voda.

Na Hirurškoj klinici u Nišu, u periodu od 3 godine (januar 2010. do novembar 2013. god.) operisano je 1389 pacijenta zbog holecistitisa, od čega je 626 (45.1%) uradjeno laparoskopjskom tehnikom. U 60,10% radilo se o pacijentima ženskog, 39,90% muškog pola. Hronični kalkulozni holecistitis je bio indikacija u 86,20%, akutni u 8,50%, polip žučne kese u 5,30%. Konverzija je iznudjena kod 28 pacijenta (4,47%). Smrtni slučajevi u posmatranom periodu nisu zabeleženi, intraoperativnih lezija biliovaskularnih struktura nije bilo, ukupan specifični postoperativni morbiditet je iznosio 2.07%.

Tehnički aspekt je i dalje dominantan kod LH. Izvanredni rezultati na našoj klinici kao i svetu, nameću potrebu daljeg razvoja ove metode, osavremenjavanja i edukacije hirurga i osoblja, sa ciljem smanjenja procenta kontraindikacija i tehničkih prepreka na minimum. *Acta Medica Medianae 2016;55(1):5-13.*

**Ključne reči:** Holecistitis, laparoskopjska holecistektomija