

ULTRASONOGRAPHIC AND SCINTIGRAPHIC PARAMETERS OF MALIGNANCY OF THE DOMINANT THYROID NODULE

Vesna Mitić-Lakušić¹, Miodrag Stojanović^{2,3},
Aleksandar Karanikolić^{2,4}, Aleksandar Filipović¹,
Dejan Stojanović⁵, Bobana Milojković^{2,4}, Zoran Milošević^{2,3}

An adequate approach to diagnosis and treatment of the dominant thyroid nodule is a matter of debate. The aim of the study is to determinate the most significant ultrasound and scintigraphic parameters of malignancy in dominant thyroid nodules.

The study involved 95 patients treated surgically for polynodous goiter with a dominant nodule for whom ultrasonographic and scintigraphic diagnosis was made prior to surgery. Echosonographic and scintigraphic findings were compared and analyzed against the operative and histopathologic findings of the dominant nodule.

Our male examinees were 59.4 ± 11.66 years, and female examinees 53.02 ± 12.78 old on the average. Of the total number of examinees, there were 74 with benign and 21 with malignant changes. Considering the ultrasound and scintigraphy parameters of malignancies, the following could be singled out as statistically significant: non-sharply delineated nodule change (OR = 0.765; 95% CI = 0.555-0.985); hypoechogenicity (OR = 2.152; 95% CI = 1.111-2.456); avascular nodule (OR = 2.156; 95% CI = 1.111-4.589); and hypofunctional nodule (OR = 2.154; 95% CI = 1.111-3.589). The sensitivity and specificity of ultrasound in dominant nodule detection were 80% and 90%, respectively, while for scintigraphy the percentages were 55% and 60%.

The most important diagnostic parameters of a malignancy of the dominant thyroid nodule are non-sharp delineation of the change, hypoechogenicity and nodule avascularization. Ultrasound has higher sensitivity and specificity than scintigraphy in the diagnosis of malignant dominant thyroid nodules. *Acta Medica Medianae 2016;55(1):14-20.*

Key words: thyroid nodule, parameters of malignancy, ultrasonographic

Clinical Center Montenegro, Podgorica, Montenegro¹
University of Niš, Faculty of Medicine, Niš, Serbia²
Public Health Institute Niš, Niš, Serbia³
Surgery Clinic, Niš, Serbia⁴
Primary Healthcare Center Bujanovac, Serbia⁵

Contact: Vesna Mitić-Lakušić
Ul. Plužinska br. 3. Podgorica, Montenegro
E-mail: vesnamitidakusic@gmail.com

Introduction

Most tumors of the thyroid gland is presented in the form of a dominant nodule. A palpable thyroid nodule is common in the general population, with the prevalence of 4-7% in women and 1% in men. In the form of a dominant nodule a carcinoma can be detected in 14-23% of cases. Adequate diagnostic approach and treatment of a dominant thyroid nodule is a matter of debate worldwide, our country included. Controversies exist as to the issues of significance of laboratory tests and imaging methods used to evaluate the patients with dominant thyroid nodules. The fundamental question concerning these controversies is the choice of an optimal diagnostic and therapeutic algorithm (1,2). The aim of the study was to establish the most relevant ultrasonographic and scintigraphic parameters of malignancy in the dominant thyroid nodule.

Material and methods

The study took place at the Surgical Clinic, Clinical Centre of Montenegro in Podgorica, in the period from January 1, 2010 to May 30, 2012. The study involved 95 patients surgically treated for polynodous goiter with a dominant nodule in whom diagnostic echosonography and scintigraphy were performed preoperatively. The findings obtained at echosonography and scintigraphy were compared and analyzed against the operative and histopathologic findings of the dominant nodule. The following factors were considered: patient gender, age, ultrasound verification of the site of the change, its boundaries/delineation, echogenicity, peripheral vascularity of the dominant nodule change in a polynodous thyroid gland, ultrasonographic verification of calcification in both benign and malignant dominant thyroid nodules, and findings of thyroid nodule scintigraphy.

Echotomographic examinations were done on an ultrasound machine using a linear 7.5 MHz probe, in the supine position with backward extension of the head. The gland was explored using longitudinal, oblique and transverse sections.

Scintigraphy was done using Tc99m (and in two cases J131) radiolabeling. After the procedure was completed, the changes were divided into hyper-, hypo-, and non-functional nodules based on

the uniformity of distribution and degree of accumulation of radiopharmaceuticals. We used lobectomy and total thyroidectomy to surgically treat the changes. The near total thyroidectomy technique was categorized under total thyroidectomies.

Echsonographic and scintigraphic findings were related to and analyzed against operative and histopathologic findings of the dominant nodule.

Statistical data processing; The results, in the form of categorical variables, were shown as contingency tables. The observed frequencies, if exceeding 5 units, were compared using the chi-square test; if any of them was below 5 units, the Fisher's test of exact probability of the null hypothesis was used. The obtained results were processed using the univariate logistic model. The results, in the form of numerical variables, were graphically represented using a boxplot, and if normal distribution was the case, they were arranged using the Student's t-test. The SPSS (version 20) statistical software was used for statistical analysis, with the level of statistical significance set at $p < 0.05$.

Results

The study involved 95 patients surgically treated for polynodous goiter with a dominant nodule. Male examinees were aged on the average 59.4 years ($SD \pm 11.66$), while female ones were 53.02 years old ($SD \pm 12.78$). Of the total number of examinees, there were 8 men (10.8%) and 66 women (89.2%) with benign changes, and 2 men (9.5%) and 19 women (90.5%) with malignancies.

Of the total number of examinees, 10 had papillary carcinoma, all of them being women. There were 5 cases of follicular carcinoma, all of whom were women too. An equal number of examinees, 1 male and 1 female, had medullary carcinoma; 2 male and 1 female examinees had anaplastic carcinoma, and in 2 women lymphoma was diagnosed.

Overall, only 3 men (9.1%) and 19 women (90.9%) had malignant changes of the thyroid gland, indicating a statistically significantly higher prevalence of malignant changes in female examinees ($\chi^2 = 33.689$; $p < 0.001$).

The minimum nodule size in those with benign changes was 1 cm, and maximum 15 cm. In those with diagnosed malignant changes, the mi-

nimum nodule size was 0.4 cm, and maximum 12 cm. Larger nodules, i.e. those measuring 11-15 cm, were more common with malignant changes, while the nodules below 5 cm in size and those in the range 6-10 cm were more common with benign changes of the thyroid.

There were 72 (87.8%) sharply delineated benign changes, while there were 10 (12.2%) similar malignant changes. There were 2 benign (15.4%) and 11 malignant (84.6%) non-sharply delineated changes.

A statistically significant higher percentage of sharply delineated benign changes, compared to malignant ones, could be observed ($\chi^2 = 34.178$; $p < 0.001$).

There were 21 (22.1%) benign isoechogetic changes, while similar malignant changes were not encountered. A hyperechogetic dominant nodule was found in those with benign changes in 23 (24.21%) cases. A hypoechogetic dominant nodule was found in 10 patients (1.52%) with benign changes and 15 patients (15.78%) with malignant disease. Benign changes with a heteroechogetic dominant nodule were present in 8 patients (8.42%), while similar malignant changes were present in 5 patients (5.26%). There were 12 patients (12.63%) with an anechogetic dominant nodule and benign disease.

In 52 patients with benign nodules, peripheral vascularity of the changes was described. Poor vascularity was detected in 10 benign (71.4%) and 4 malignant changes (28.6%). There were 2 benign (11.8%) and 15 malignant (88.2%) avascular changes. There were 10 (83.3%) intensely vascularized benign changes of the thyroid nodule and 2 (16.7%) strongly vascularized malignant changes.

Thyroid nodule scintigraphy revealed that most of them, 43, were hyperfunctional, 39 were hypofunctional, and 13 were afunctional.

Hyperfunctional nodules were most commonly found in those with benign changes, 41 (43.15%), while such nodules were identified in 2 cases (2.1%) among those with malignant disease. Hypofunctionality was scintigraphically detected in 21 examinees (22.1%) with benign changes and in 18 examinees (18.94%) with malignant changes in the thyroid (Table 1).

Table 1. Dominant thyroid nodule ultrasonographic and scintigraphic characteristics

	Benign N (%)	Malignant N (%)
Ultrasonographic nodule size verification		
<5 cm	71 (79.8)	18 (20.2)
6-10 cm	2 (66.7)	1 (3.3)
11-15 cm	1 (3.3)	2 (6.7)
Ultrasonographic nodule border delineation		
Sharply delineated	72 (87.8)	10 (12.2)
Non-sharply delineated	2 (15.4)	11 (84.6)
Ultrasonographic verification of nodule change echogenicity		
Isoechogetic	21(100.0)	0 (0.0)
Hypoechogetic	10 (40.0)	15 (60.0)
Heteroechogetic	8 (61.5)	5 (38.5)
Hyperechogetic	23(100.0)	0 (0.0)
Anechogetic	12 (92.3)	1 (7.7)

Ultrasonographic verification of peripheral vascularization		
Well vascularized	52 (100)	0
Poorly vascularized	10(71.4)	4(28.6)
Avascularized	2(11.8)	15(88.2)
Strongly vascularized	10(88.3)	2(16.7)
Thyroid nodule scintigraphy		
Afunctional	12 (92.3)	1 (7.7)
Hypofunctional	21 (53.8)	18 (46.2)
Hyperfunctional	41 (95.3)	2 (4.7)

Table 2. Echosonographic representation of echogenicity of malignant dominant nodules

Malignant nodule	Hypoechoogenic	Heteroechoogenic	Anechoogenic	Total
Ca papillare	10 (62.5)	0 (0.0)	0 (0.0)	10 (45.5)
Ca folliculare	4 (25.0)	0 (0.0)	1 (100)	5 (22.7)
Ca medulare	0 (0.0)	2 (40.0)	0 (0.0)	2 (9.1)
Anaplastic Ca	0 (0.0)	3 (60.0)	0 (0.0)	3 (13.6)
Lymphoma	2 (12.5)	0 (0.0)	0 (0.0)	2 (9.1)
	16 (100)	5 (100)	1 (100)	22 (100)

Papillary carcinomas were represented as solely hypoechoogenic. Follicular carcinomas were represented as hypoechoogenic, 4 of them, and 1 as anechoogenic. Echosonographically dominant nodules were represented as heterogenous in both 2 patients with medullary carcinoma, and in 3 patients with anaplastic carcinoma, while all lymphomas were hypoechoogenic (2 cases, or 12.5%) (Table 2).

Table 3. Benign nodule scintigraphy

Benign nodule	Afunctional	Hypofunctional	Hyperfunctional	Total
Adenoma	1 (1.05%)	7 (7.36%)	41 (43.15%)	49 (51.5%)
Cyst	11 (11.57%)	13 (13.68%)	0 (0.0)	24 (32.9%)
	12 (12.62%)	20 (21.04%)	41 (43.15%)	73 (84.45%)

The most afunctional nodules were cysts 11; (11.57%), while in 1 case (1.05%) such a nodule was adenoma. Cysts were represented as hypofunctional nodules as well in 13 cases (13.68%). There were no hyperfunctional cysts – all hyperfunctional nodules represented adenomas 41 (43.15%) (Table 3).

Table 4. Scintigraphy presentation of malignant dominant nodule.

	Afunctional	Hypofunctional	Hyperfunctional	Total
Ca papillare	0 (0.0)	9 (47.4)	1 (50.0)	10 (45.5)
Ca folliculare	1 (100.0)	3 (15.8)	1 (50.0)	5 (22.7)
Ca medullare	0 (0.0)	2 (10.5)	0 (0.0)	2 (9.1)
Ca anaplasticum	0 (0.0)	3 (15.8)	0 (0.0)	3 (13.6)
Lymphoma	0 (0.0)	2 (10.5)	0 (0.0)	2 (9.1)
	1 (100.0)	19 (100.0)	2 (100.0)	22 (100.0)

There was only one follicular carcinoma represented as an afunctional nodule. Most hypofunctional nodules could be seen among papillary carcinomas – 9 (47.4%); then 3 (15.8%) among follicular and anaplastic carcinomas each; and 2 (10.5%) among medullary carcinomas and lymphomas each. Among hyperfunctional nodules, there was one papillary and one follicular carcinoma (Table 4).

Table 5. Univariate logistic regression model of ultrasonographic and scintigraphic parameters of malignancy

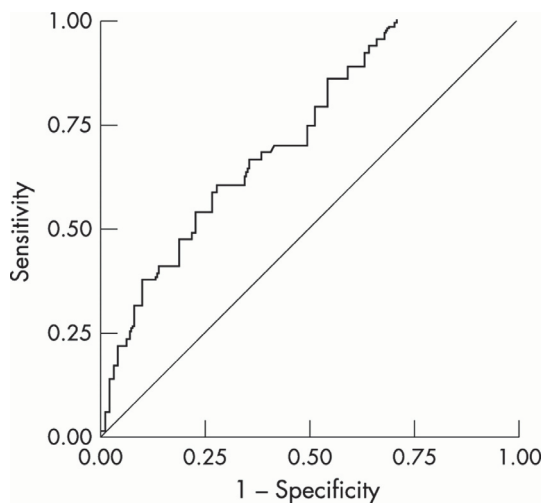
		OR	95% CI	P
Nodule change delineation	* Sharp	/	/	/
	* Non-sharp	0.765	0.555-0.985	<0.05
Echogenicity	Isoechoogenous	/	/	/
	Hypoechoogenous	2.152	1.111-2.456	<0.01
	Heteroechoogenous	1.195	0.965-1.111	0.123
	Hyperechoogenous	1.023	0.569-1.986	0.236
Vascularization	Anechoogenous	1.023	0.569-1.986	0.236
	* Peripheral	/	/	/
	Poor	1.611	0.855-1.999	0.421
	Avascularized	2.156	1.111-4.589	0.001
Highly vaskularisaed	Strongly vascularized	1.555	0.989-1.985	0.241
	Highly vaskularisaed	1.555	0.989-1.985	0.241
Scintigraphic functional imaging	Hypofunctional	2.154	1.111-3.589	<0.01

*reference category

Considering ultrasonographic and scintigraphic parameters of malignancy, the following were shown to be statistically significant: non-sharply delineated nodule change (OR = 0.765; 95% CI = 0.555-0.985), hypoechogenicity (OR = 2.152; 95% CI = 1.111-2.456), nodule avascularity (OR = 2.156; 95% CI = 1.111-4.589) and nodule hyperfunction (OR = 2.154; 95% CI = 1.111-3.589).

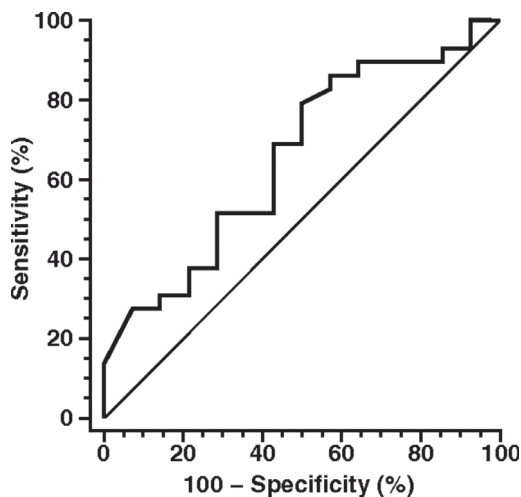
Univariate logistic regression of ultrasonographic and scintigraphic parameters of nodule benignity indicated the following as statistically significant: sharp delineation of nodule changes, hyperechogenicity, peripheral vascularity and hyperfunctional nodule (Table 5).

Graph 1 presents the ROC curve of sensitivity and specificity of ultrasound in dominant thyroid nodule detection. The method sensitivity was 80%, while specificity was 90%.



Graph 1. Ultrasonography ROC curve of sensitivity and specificity

Graph 2 presents the ROC curve of sensitivity and specificity of scintigraphy in dominant thyroid nodule detection. The sensitivity of the method was 55%, while specificity was 60%.



Graph 2. Scintigraphy ROC curve of sensitivity and specificity

Discussion

The study involved 95 patients surgically treated for polynodous goiter with a dominant nodule, in whom preoperative laboratory, echosonographic and scintigraphic diagnosis was done.

Echosonographic and scintigraphic findings were compared and analyzed against operative and histopathologic findings of the dominant nodule.

The average age of the enrolled patients was accounted for in the study. Male examinees were 59.4 years old, and female ones were 53.02 years old on the average, meaning that a statistically significant difference was not present ($t = 1.505$; $p = 0.136$) and suggesting homogeneity of the groups. The youngest patient was 18, and the oldest was 78 years old. The factor of age was very important, since younger age implied more aggressive forms, as suggested as well in a large study performed in the northwestern USA on 5.000 children aged 11-18 years, in whom a dominant palpable nodule was detected, malignant in nature in 20% of the cases (3).

Carcinoma papillare, carcinoma folliculare, carcinoma medullare, as well as anaplastic carcinoma and lymphoma, all presented as a malignant dominant nodule. Of all the examinees, 10 (9.5%) had papillary carcinoma, 5 (4.75%) had follicular carcinoma, one man and one woman had medullary carcinoma (1.9%), 3 (2.85%) had anaplastic carcinoma, and lymphoma was diagnosed in 2 women (1.9%). Lymphoma usually occurs in up to 2%, medullary carcinoma in 4%, follicular carcinoma in 5%, anaplastic carcinoma in 1%, and papillary carcinoma accounts for about 90% of cases of thyroid cancer (4). In our study as well, papillary carcinoma occurred with the highest prevalence, followed by follicular and anaplastic carcinoma (which did not match the above literature data), and only then by medullary carcinoma and lymphoma.

Liu et al. (5) have suggested a higher probability of malignant nodules in women. In their paper they stated that malignant nodules were more common in women below 50 years of age, occurring also in those over 50 as well, in contrast to men in whom malignant nodules were less common compared to women, and usually occurred in those below 50.

Summarizing all the data, only 3 men (9.1%) versus 19 women (90.9%) had malignant changes in the thyroid, indicating a statistically significantly higher prevalence of malignant changes in female examinees ($\chi^2 = 33.689$; $p < 0.001$).

The size of dominant nodules was determined at echosonography as well. Minimum nodule size in those with benign dominant nodule changes was 1 cm and maximum size was 15 cm. In those with diagnosed malignant changes, minimum nodule size was 0.4 cm and maximum 12 cm. Malignancy was most commonly identified in nodules below 5 cm and over 11 cm in size. We may conclude that the proportion of malignancies did not increase with increasing size, since

aggressive malignancies occurred even with the nodule size below 1 cm. In that regard, our study confirmed the remarks by Kim *et al.* (6), who had enrolled 1398 patients with dominant thyroid nodules and analyzed their size and degree of malignancy. In nodules of less than 1 cm in size, malignancies occurred in 169 patients (42.0%), and in nodules larger or equal to 1 cm in 15.9%. The total malignancy percentage was 23.4% in that study, versus 22.1% in our investigation.

In our study, echosonography was able to detect changes even below 1 cm in size – the smallest verified change was 0.4 cm in size, which was important since in that exact nodule papillary carcinoma was detected. Scintigraphy could not precisely and reliably identify the changes below 1 cm and over 5 cm in size.

Mihailescu *et al.* (7) in their study which enrolled 4293 patients, analyzed the correlation between nodule size and malignancy and stated that there was not any correlation for nodules of less than 0.5 cm in size, while a correlation existed for nodules over 1 cm (especially those exceeding 1.5 cm). These results were confirmed by Moon *et al.* (8), who analyzed nodules of 2.7-64 mm in size. There was not any correlation for nodules below 1 cm in size. In our study, lesion delineation was examined as well. In 72 (87.8%) dominant nodules, histopathologically confirmed as benign, delineation from the adjacent thyroid tissue was sharp, while malignant dominant nodules (11; 84.6%) appeared echosonographically as non-sharply delineated.

In our prevalence comparisons, we observed a statistically significantly higher percentage of sharply delineated benign changes compared to malignant ones ($\chi^2 = 34.178$; $p < 0.001$). A high degree of sensitivity (84.4%) and specificity (85.1%) was reported as well by Kim *et al.* (6) in their echosonographic verification of this characteristic. They also analyzed the precision of ultrasound related to nodule size for the same characteristic (delineation from the surrounding structures), obtaining the precision of 53.5% for dominant nodules below 1 cm in size, and 22.2% for those over 1 cm. In our investigation, the percentage was similar for all nodule dimensions.

Park *et al.* (9), studied the sample of 1029 patients in whom they analyzed echosonographical thyroid nodule characteristics, delineation included. They obtained higher sensitivity values – malignant nodules were visualized as non-sharply delineated changes in 81.3% ($p < 0.001$), while benign nodules were visualized as sharply delineated in 89.5% ($p < 0.001$).

We may conclude that in dominant nodule delineation assessment, sonography, as a diagnostic method, has greater value compared to scintigraphy, since it can precisely verify the same characteristic up to its intrinsic nodule size visualization limit; scintigraphy cannot decisively suggest the value of the examined dominant nodule characteristic.

Dominant nodule echogenicity was also studied against subsequently established final histopathology of the change. A conclusion may be

drawn that malignant dominant nodules in 15.78% of the cases gave the picture of hypoechogenic changes, which represented 60% of malignancies from all malignant nodules, and in (5,26%) 38,5% of the cases they presented as heteroechogenic changes (38.5% of malignancies). In his analysis, Kim stated that malignant nodules presented as hypoechogenic with 81% sensitivity (6).

Benign nodules presented as hyperechogenic changes in 24.21%, and as anechogenic or isoechogenic with peripheral halo in 23.15%. Similar results were obtained by Bonavita *et al.* (10) in their paper in 2009, in which they analyzed how to recognize benign thyroid nodules echosonographically.

The current standings that peripheral vascularity surrounding a nodular change indicates benignity is corroborated by this analysis as well. In all cases of peripheral vascularization of the change, its benign nature was confirmed (52 instances). A light halo surrounded isoechogenic and hyperechogenic nodules, as confirmed in a paper by Bonavita (10).

Other authors state that the „halo sign“ has been considered pathognomonic of benignity of a change until recently. After the introduction of CD in ultrasound diagnosis, a conception has been proposed that the sign actually represents a compressed blood vessel, that can be present in malignant nodules as well (11,12).

By way of thyroid nodule scintigraphy with Tc-99m we found out that most nodules were hyperfunctional – 43 – followed by 39 hypofunctional ones, and 13 afunctional nodules. Benign nodules represented as hyperfunctional were present in 41 patients (43.15%), in contrast to malignant ones in 2 (2.1%). Hypofunctionality was scintigraphically diagnosed in 21 (22.1%) of patients with benign changes, and in 18 (18.94%) of those with malignant changes in the thyroid.

There were 12 (12.63%) afunctional nodules with benign changes and only 1 such nodule (1.05%) with malignant alteration. Radović *et al.* (13) reported that the risk of malignancy in afunctional nodules ranged from 8% to 25%. Paurnović *et al.* (14) stated that the incidence of carcinoma in an afunctional nodule was 15% vs 9.5% in a hypofunctional one. Of all benign nodules, adenomas presented as hyperfunctional nodules in 43.15%, while cysts presented as both hypofunctional (13.68%) and afunctional nodules (in 11.57%).

In two patients of the same age from Podgorica, dominant nodules were confirmed, presenting echosonographically as hypoechoic nodules. Tc-99m scanning presented the nodules as hyperfunctional („hot“), which did not match the usual presentation of malignant nodules as „cold“, since histopathology confirmed one as papillary, and another as a medullary carcinoma. The issue required further testing to be undertaken. A new scintigraphy was done in both cases using J123, which then demonstrated dominant nodules as „cold“. A detailed analysis brought us to the conclusion that the only association between them

could be their nature as well differentiated early tumors, able to bind strongly the radiolabeling agent and to present as hyperfunctional nodules.

We may conclude that the presence of a hot nodule does not exclude the presence of malignancy and that additional ¹²³I scintigraphy is warranted in such cases. If in both instances dominant nodules present as hot ones, then the probability of cancer is very low.

Considering the ultrasonographic and scintigraphic parameters of malignancy, the following elements should be taken into account: non-sharply delineated nodule change (OR = 0.765; 95% CI = 0.555-0.985); hypoechogenicity (OR = 2.152; 95% CI = 1.111-2.456); an avascularized nodule (OR = 2.156; 95% CI = 1.111-4.589); and a hypofunctional nodule (OR = 2.154; 95% CI = 1.111-3.589). Univariate logistic regression model of ultrasonographic and scintigraphic parameters of benignity indicated the following factors as statistically significant: sharp delineation of nodule changes, hyperechogenicity, peripheral vascularization and hyperfunctional nodules.

The sensitivity and specificity of diagnostic echosonography were examined as well and found to be 80% and 90%, respectively.

Our findings of specificity and sensitivity match the findings by Kim (6), who reported in his paper that sensitivity was 97.2% and specificity 80.9% for dominant nodule echosonography, with positive predictive value of 59.6 and negative predictive value 97.3 ($p < 0.001$), and corroborates the findings by the American Association of Clinical

Endocrinologists, who reported the sensitivity of the method of 79.2% and specificity 90.8%. This does not agree with the report by the Society of Radiologists in Ultrasound (sensitivity, 35.5%) (15).

Wang found that echosonography demonstrated sensitivity of 75% and specificity of 52.17% for nodules <10 mm. The ability of ultrasound to detect even such small changes can have important implications, since scintigraphy cannot give any decisive information about this nodule characteristic (16).

A conclusion may be drawn that scintigraphy should be kept in the thyroid disease diagnostic protocols for the time being, since it can afford valuable functional-topographic information, while echosonography can contribute to thyroid diagnosis with morphological nodule characteristics.

Conclusion

In our statistical analysis, the following ultrasonographic and scintigraphic parameters were shown to be statistically significant: non-sharply delineated nodule change, hypoechogenicity, avascularized nodules and hypofunctional nodules. The sensitivity of echosonographic diagnosis was 80% in our study, while the specificity of the method was 90%. The sensitivity of scintigraphy in dominant thyroid nodule diagnosis was 55%, while the specificity of the method was 60%.

References

1. Paunović I, Diklić A, Krgović K, Zivaljević V, Tatić S, Havelka M, et al. Rational diagnosis and surgical treatment of solitary thyroid nodules. *Acta Chir Iugosl* 2003; 50(3):37-42. [[CrossRef](#)] [[PubMed](#)]
2. Filipović A. Lymphocytic infiltration as a prognostic factor in differentiated thyroid carcinoma. Doctoral dissertation. University of Belgrade: Faculty of Medicine, 2008.
3. Hung W. Solitary thyroid nodules in 93 children and adolescent. a 35-years experience. *Horm Res* 1999; 52(1):15-8. [[CrossRef](#)] [[PubMed](#)]
4. Norton JA, Levin B, Jensen RT. Cancer of the endocrine system. In: DeVita VT, Hellman S, Rosenberg SA, editors. *Cancer principles & Practice of oncology*. 4th ed. Philadelphia: J.B.Lippincott company; 1993. p. 1333-435.
5. Liu YI, Kamaya A, Desser TS, Rubin DL. A Bayesian classifier for differentiating benign versus malignant thyroid nodules using sonographic features. *AMIA Annu Symp Proc* 2008; 419-23. [[PubMed](#)]
6. Kim EK, Park CS, Chung WY, Oh KK, Kim DI, Lee JT, Yoo HS. New sonographic criteria for recommending fine-needle aspiration biopsy of non-palpable solid nodules of the thyroid. *Am J Roentgenol* 2002; 178(3):687-91. [[CrossRef](#)] [[PubMed](#)]
7. Mihăilescu D, Schneider A. Size, number and distribution of thyroid nodules and the risk of malignancy in radiation-exposed patients who underwent surgery. *J Clin Endocr Metab* 2008; 93(6):2188-93. [[CrossRef](#)] [[PubMed](#)]
8. Moon WJ, Jung SL, Lee JH, Na DG, Baek JH, Lee YH, et al. Benign and malignant thyroid nodules: US differentiation - multicenter retrospective study. *Radiology* 2008; 247(3):762-70. [[CrossRef](#)] [[PubMed](#)]
9. Park JM, Choi Y, Kwag HJ. Partially Cystic Thyroid Nodules: Ultrasound Findings of Malignancy. *Korean J Radiol* 2012; 13(5):530-35. [[CrossRef](#)] [[PubMed](#)]
10. Bonavita JA, Mayo J, Babb J, Bennett G, Oweity T, Macari M, Yee J. Pattern recognition of benign nodules at ultrasound of the thyroid: Which nodules can be left alone? *Am J Roentgenol* 2009; 193(1):207-13. [[CrossRef](#)] [[PubMed](#)]
11. Todorović-Djilas Lj. Thyroid ultrasonography. In: Marković A, editor. *Ultrasonography in Medicine*. Belgrade: Elit Medica; 1997.
12. Demirci H, Erdamar H, Bukan N, Dikmen K, Karakoç A, Arslan M. Biochemical and hormonal composition, cytological examination of thyroid cyst fluid, and comparison according to gender and color of cyst fluid. *Clin Chem Lab Med* 2007; 45(11):1517-22. [[PubMed](#)]
13. Radović B, Tatić S, Krajnović Jakšić E, Han R. Cytological analysis in scintigraphically nonfunctioning thyroid nodules. *Vojnosanit Pregl* 2010; 67(10):797-801. [[CrossRef](#)]

14. Paunović I, Krgović K, Todorović M. Carcinoma of thyroid gland in solitary and dominant nodule. *Acta Chir Jugosl* 1998; (1):268.
15. Ahn SS, Kim EK, Kang EK, Lim SK, Kwak JY, Kim MJ. Biopsy of thyroid nodules: comparison of three sets of guidelines. *Am J Roentgenol* 2010;194(1):31-7. [[CrossRef](#)] [[PubMed](#)]
16. Wang Y, Dan HJ, Dan HY, Li T, Hu B. Differential Diagnosis of Small Single Solid Thyroid Nodules using Real-Time Ultrasound Elastography. *J Int Med Res* 2010. 38(2):466-72. [[CrossRef](#)] [[PubMed](#)]

Originalni članak**UDC:616.441-006.04-073**
doi: 10.5633/amm.2016.0102**ULTRASONOGRAFSKI I SCINTIGRAFSKIH PARAMETRI
MALIGNITETA DOMINANTNOG TIREOIDNOG NODUSA**

Vesna Mitić-Lakušić ¹, Miodrag Stojanović ^{2,3},
Aleksandar Karanikolić ^{2,4}, Aleksandar Filipović ¹,
Dejan Stojanović ⁵, Bobana Milojković ^{2,4}, Zoran Milošević ^{2,3}

Clinical Center Montenegro, Podgorica, Montenegro ¹
University of Niš, Faculty of Medicine, Niš, Serbia ²
Public Health Institute Niš, Niš, Serbia ³
Surgery Clinic, Niš, Serbia ⁴
Primary Healthcare Center Bujanovac, Serbia ⁵

Contact: Vesna Mitić-Lakušić
Ul. Plužinska br. 3. Podgorica, Montenegro
E-mail: vesnamitidakusic@gmail.com

Adekvatni pristup dijagnozi i lečenju dominantnog nodusa štitaste žlezde predmet je sukobljavanja različitih stavova. Cilj ovog rada bio je da odredi najznačajnije ultrazvučne i scintigrafske parametre maligniteta dominantnog tireoidnog nodusa.

Ispitivanje je obuhvatilo 95 bolesnika operisanih od polinodozno izmenjene strume sa dominantnim nodusom kod kojih je preoperativno urađena ehosonografska i scintigrafska dijagnostika. Ehosonografski i scintigrafski nalazi upoređeni su i analizirani sa operativnim i patohistološkim nalazom dominantnog nodusa.

Ispitanici muškog pola imali su prosečnu starost od 59,4±11,66 godine, a ženskog pola 53,02±12,78 godine. Od ukupnog broja ispitanika, sa benignim promenama bilo je 74 bolesnika, a sa malignim promenama 21 bolesnik. Posmatrajući ultrazvučne i scintigrafske parametre maligniteta, kao statistički signifikantni izdvojili su se: neoštro ograničena nodusna promena (OR=0,765;95%, CI=0,555-0,985), hipoehogenost (OR=2,152; 95%CI=1,111-2,456), avaskularizovani nodus (OR=2,156; 95%CI=1,111-4,589) i hipofunkcionalni nodus (OR=2,154; 95%CI=1,111-3,589). Senzitivnosti i specifičnosti ultrazvučne metode u detekciji dominantnog nodusa iznosila je 80%, tj. 90%, dok je kod scintigrafije iznosila 55%, tj. 60%.

Najznačajniji dijagnostički parametri maligniteta dominantnog tireoidnog nodusa su neoštra ograničenost promene, hipoehogenost i avaskularizacija nodusa. Ultrazvuk ima veću senzitivnost i specifičnost u odnosu na scintigrafiju u dijagnostici maligniteta dominantnog tireoidnog nodusa. *Acta Medica Medianae* 2016;55(1):14-20.

Ključne reči: tireoidni nodus, parametri maligniteta, ultrasonografija