

MACULAR THICKNESS IN HLA B-27 POSITIVE PATIENTS WITH ACUTE ANTERIOR UVEITIS

Maja Živković¹, Marko Zlatanović¹, Gordana Zlatanović^{1,4},
Aleksandra Hristov², Vesna Jakšić³,
Marija Radenković¹, Jasmina Đorđević-Jocić^{1,4},
Gordana Stanković-Babić¹, Marija Trenkić-Božinović¹

Uveitis is the inflammation of the uveal tract. According to the localization of pathological processes in the affected eyes, uveitis can be classified as anterior, intermediate, posterior and as panuveitis. Acute anterior uveitis (AAU) is the most common form of uveitis. Almost half of all the patients with AAU are HLA-B27 positive.

The aim of the paper was to analyze the changes in macular thickness in HLA B-27 positive patients with unilateral acute anterior uveitis.

The study enrolled 15 patients aged 30-60 years with unilateral acute anterior uveitis, without clinically recognized macular edema and without any other ocular diseases. Both the affected and healthy eyes were monitored. The control group consisted of 15 individuals without systemic or ocular diseases. Macular thickness was measured using Cirrus SD-OCT-a (Carl Zeiss Meditec, Dublin, CA, USA). The measurements were performed at days 1, 3 and 7 after the onset of the disease. The values of macular thickness were compared between the affected and healthy eye, as well as in relation to the controls.

In the group of patients with acute anterior uveitis, 8 patients were diagnosed with Bechterew's disease, 5 patients with Reiter's syndrome and 2 patients had psoriatic arthritis. The highest value of mean macular thickness was registered on day 7 after the onset of the disease. At this point, a statistically significant difference in macular thickness between the affected and healthy eye was also registered, while in comparison to the controls it was noted from the first day of follow-up.

HLA B-27 positive patients with unilateral acute anterior uveitis showed the signs of macular thickening. *Acta Medica Medianae* 2016;55(4):46-51.

Key words: acute anterior uveitis, HLA B-27, macular thickness

Ophthalmology Clinic, Clinical Center Niš, Niš, Serbia 1
Eye Vision Center "Maja", Niš, Serbia 2
Ophthalmology Clinic "Prof. Dr Ivan Stanković", Clinical Hospital
Center Zvezdara, Beograd, Serbia 3
University of Niš, Medical Faculty, Niš, Serbia 4

Contact: Maja Živković
Radoja Dakića 47A/28, Niš, Serbia
E-mail: drzivkovicmaja@gmail.com

Introduction

Uveitis is the inflammation of the uveal tract. According to the localization of pathological processes in the affected eyes, uveitis can be classified as anterior, intermediate, posterior and as panuveitis. Acute anterior uveitis (AAU) is the most common form of uveitis. Almost half of all the patients with AAU are HLA-B27 positive.

Involvement of the posterior segment in patients with HLA-B27 AU rarely occurs, but it has still been described in the literature. The most common posterior segment changes are vitritis, retinal vasculitis, papillitis and CME (cystoid macular edema).

The term "macular thickening" has often been mentioned in recent literature, implying that a macular swelling can only be seen on OCT (optical coherence tomography), that it shows no clinically recognized macular edema, no changes on the FA, and no cysts on OCT.

The mechanism of onset of noncystoid macular edema - "macular thickening" - has not yet been fully understood. Many authors believe that the causal factors are the same as in cystoid macular edema. Prostaglandins, inflammatory cytokines and VEGF cause increased blood vessel permeability, leukocyte migration, and macular edema (1-3).

Macular edema is caused by the breakdown of the blood-ocular and blood-retinal barrier: the outer, when the retinal pigment epithelium (RPE)

is compromised, and inner, when the endothelial cells of retinal blood vessels are affected. There are occluding junctions between the endothelial and RPE cells. Macular edema in acute anterior uveitis should be suspected when visual acuity damage persists for more than a few weeks after the onset of acute uveitis. CME can be seen in about 30% of patients with HLA-B27 positive arthritis. The same applies to the patients with ankylosing spondylitis, psoriatic arthritis and Reiter's syndrome. The breakdown of blood-retinal barrier in anterior uveitis is the result of endogenous secretion of inflammatory mediators (4).

The prevalence of HLA-B27 antigen, its polymorphism, and association with AAU vary in different populations, probably as the consequence of a combination of genetic and environmental factors (5-7).

Aim

The aim of the paper was to analyze the changes in macular thickness in HLA-B27 positive patients with unilateral acute anterior uveitis.

Methods

The study enrolled 15 patients with unilateral acute anterior uveitis, aged between 30-60 years. The patients did not present clinically visible macular edema, nor the evidence of other ocular diseases. Both the affected and healthy eyes were monitored. The control group consisted of 15 patients with no evidence of systemic or ocular diseases.

All the patients underwent a complete ophthalmic examination, the best corrected visual acuity was determined (BCVA), the values of intraocular pressure were measured by Goldmann applanation tonometry, biomicroscopic examination of the anterior segment was performed, as well as gonioscopy and examination of the ocular fundus in mydriasis. Mydriasis was performed instilling one or two drops of 1% tropicamide solution.

Macular thickness was measured using Cirrus SD-OCT (Carl Zeiss Meditec, Dublin, CA, USA). The measurements were done at days 1, 3 and 7 after the onset of the disease. The values of macular thickness between the affected and healthy eye, as well as in relation to the control group, were compared.

The exclusion criteria were as follows: patients with all other forms of uveitis, any ocular or systemic disease suspected of causing macular thickness, blurriness of the refractive media that may compromise precise OCT measurements, already present macular damage (including epiretinal membranes and diabetic maculopathy), as well as previous ocular surgeries.

The therapy of AU included intensive topical corticosteroid treatment, administration of cycloplegics, NSAIDs, and in some cases systemic corticosteroid administration.

All the patients were monitored and examined. i.e. took part in the study on their own free will, signing the informed written consent for their participation in the study. They were fully informed of the study examinations, what is in accordance with the Declaration of Helsinki. None of the applied methods were harmful to the health of enrolled patients, they were neither aggressive nor painful, and the patients personally benefited from having a complete ophthalmic examination.

Results

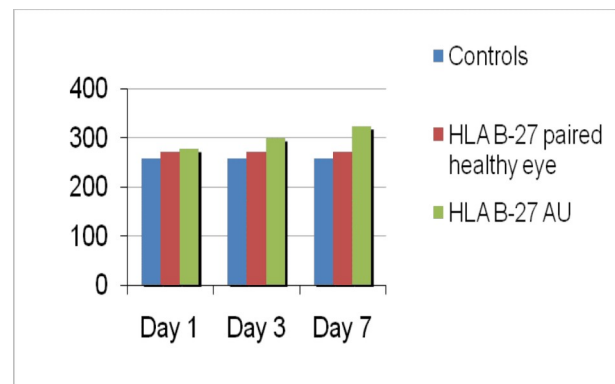
In the group of patients with acute anterior uveitis there were:

- 8 patients with the diagnosis of M. Bechterew

- 5 patients diagnosed with M. Reiter

- 2 patients with psoriatic arthritis

The independent samples t-test was used to analyze the differences in mean macular thickness between the healthy controls and patients with HLA-B27, both in the eye affected by AAU and the



Graph 1. Macular thickness monitoring at days 1, 3 and 7 from the onset of the disease in the control group, HLA B-27 AAU and HLA B-27 of the healthy eye

Table 1. Mean value of macular thickness at days 1, 3, 7 from the onset of the disease in the control group, HLA B-27 AAU and HLA B-27 of healthy eye

	Control group		HLA B-27 AAU		HLA B-27 healthy paired eye	
	Mean	SD	Mean	SD	Mean	SD
1 st day	257	37	277	15	271	13
3 rd day	257	37	299	14	275	20
7 th day	257	37	323	23	279	17

*Mean- mean value of macular thickness expressed in microns

**SD- standard deviation

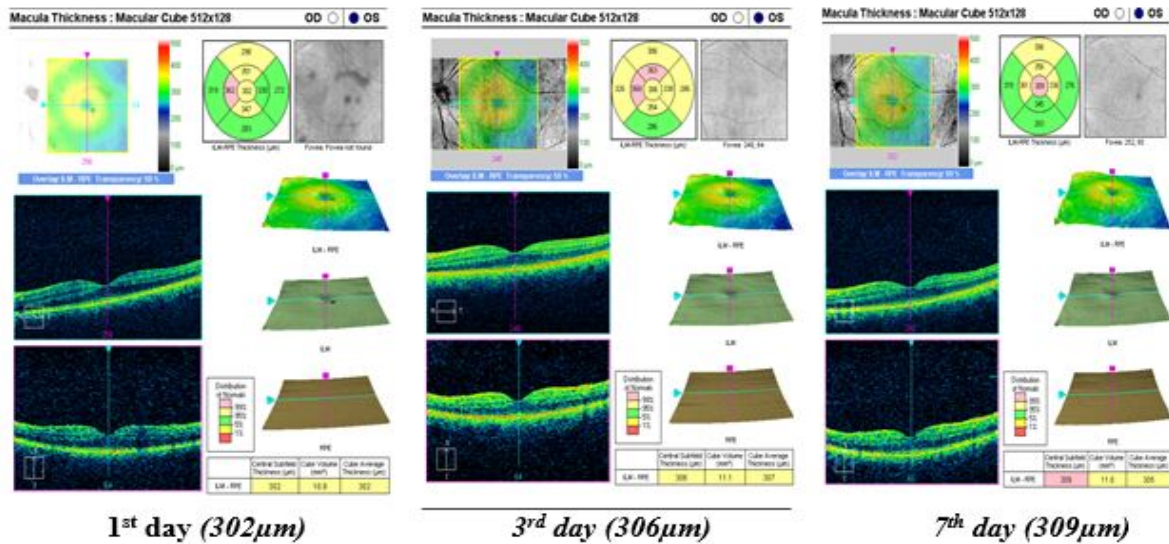


Figure 1. OCT of the macula at days 1, 3 and 7 from the onset of the disease in AAU affected eye in HLA B-27 positive patient

healthy paired eye, and the difference between the affected and healthy paired eye. The results are shown in the following graphs, tables and figures (Graph 1, Table 1, Figure 1).

Significant differences between the eyes in the healthy controls and affected HLA-B27 AAU

Table 2. Statistical analysis of macular thickness in patients of the control group and HLA B-27 AAU group

	Control group		HLA B-27 AAU		p
	Mean	SD	Mean	SD	
1 st day	257	37	277	15	0,0312
3 rd day	257	37	299	14	0,0003
7 th day	257	37	323	23	0,0000

Table 3. Statistical analysis of macular thickness in patients from the group HLA B-27 of healthy paired eye and HLA B-27 AAU of the affected eye

	HLA B-27 paired healthy eye		HLA B-27 AAU		p
	Mean	SD	Mean	SD	
1 st day	271	13	277	15	0,1258
3 rd day	275	20	299	14	0.0004
7 th day	279	17	323	23	0

Table 4. Statistical analysis of macular thickness in patients from the group HLA B-27 of healthy paired eye and the control group

	HLA B-27 healthy paired eye		Control group		p
	Mean	SD	Mean	SD	
1 st day	271	13	257	37	0.0889
3 rd day	275	20	257	37	0.0543
7 th day	279	17	257	37	0.0228

eyes in the experimental group were registered on days 1, 3, and 7. The differences increased with time (Table 2).

Significant differences between the HLA-B27 healthy paired eye and HLA-B27 AAU affected eye were registered on days 3 and 7, but the difference increased on day 7 (Table 3)

Significant differences between the healthy HLA-B27 paired eye in experimental and control groups were observed on day 7 (Table 4).

Cystoid macular edema was seen in one patient – the patient was excluded from the study and was treated with triamcinolone acetonide.

Discussion

The mechanism of onset of non-cystoid macular edema – “macular thickening”- has not yet been fully understood. Many authors believe that the causal factors are the same as in cystoid macular edema. Prostaglandins, inflammatory cytokines and VEGF cause the increase of blood vessel permeability, leukocyte migration, and macular thickness (1, 8).

The results of our study show a statistically significant difference in macular thickness in HLA-B27 positive patients with unilateral acute anterior uveitis in comparison to controls from the very beginning of the period of observation.

Balaskas et al. (2012) (1) in their study “Retinal Thickening in HLA-B27–Associated Acute Anterior Uveitis: Evolution with Time and Association with Severity of Inflammatory Activity” pointed out a sudden increase in macular thickness in HLA B-27 positive patients with unilateral acute anterior uveitis over 3 to 4 weeks from the onset of the disease, followed by a progressive decrease. The severity of the inflammation correlates with macular thickness of the affected eye.

Castellano et al. (2009) (9) analyzed the incidence of retinal thickening in patients with iridocyclitis and they also examined the correlation between anterior chamber changes, retinal thickening and visual acuity. The results showed a high correlation between iridocyclitis and retinal thickening.

Shulman et al. (2012) (10) went even further; in addition to the examination of morphological macular changes, they also analyzed peripapillary retinal nerve fiber layer thickness in patients with acute anterior uveitis. They concluded that the eyes affected by anterior uveitis showed macular thickening, as well as peripapillary retinal fiber layer (RNFL) thickening. Their study also suggested that even milder anterior uveitis might be associated with morphology changes in the posterior segment, as visible on OCT.

Moreno-Arrones et al. (2010) (11) obtained similar results and drew the same conclusion that patients suffering from acute uveitis showed macular thickening and peripapillary RNFL thickening as well.

Wexler et al. (2012) (12) in their study "Bilateral macular thickening in mild unilateral anterior uveitis: is HLA-B27 involved?" assessed macular thickness in HLA positive and HLA negative patients with AAU. They concluded that there was a larger increase in macular thickness in

HLA positive than in HLA negative patients with AAU. The data from their study revealed that macular thickening was also present in quiet fellow-eyes unaffected by AAU and that it was rather the rule than the exception, even in phakic eyes with excellent visual acuity. "Macular thickening" probably reflects a systemic immunemediated response to the inflammatory disorder in AAU, and it is possible that HLA-B27 is involved in the pathogenesis of AAU (12,13).

Markomichelakis et al. (2007) (14) demonstrated a complete resolution of uveitic edema in 47% of eyes in their 12-month follow-up with medical treatment. They implied that diffuse "macular thickening" carries a negative prognostic significance because it was not treated due to good visual acuity.

However, diffuse "macular thickening" may negatively affect visual acuity if persistent or during an inflammatory relapse.

Conclusion

"Macular thickening" means macular swelling without cystic changes shown clearly on OCT only.

HLA-B27 positive patients with unilateral acute anterior uveitis show the signs of macular thickening in the affected eye.

References

1. Balaskas K, Ballabeni P, Guex-Crosier Y. Retinal thickening in HLA-B27-associated acute anterior uveitis: evolution with time and association with severity of inflammatory activity. *Invest Ophthalmol Vis Sci* 2012; 53(10):6171–7. [[CrossRef](#)] [[PubMed](#)]
2. Iannetti L, Spinucci G, Abbouda A, De Geronimo D, Tortorella P, Accorinti M. Spectral-domain optical coherence tomography in uveitic macular edema: morphological features and prognostic factors. *Ophthalmologica* 2012; 228(1):13–8. [[CrossRef](#)] [[PubMed](#)]
3. Estafanous MF, Lowder CY, Kaiser PK. Patterns of macular edema in uveitis patients. *Ophthalmology* 2005; 112(2):360. [[CrossRef](#)] [[PubMed](#)]
4. Chang JH, McCluskey PJ, Wakefield D. Acute anterior uveitis and HLA-B27. *Surv Ophthalmol* 2005; 50(4):364–88. [[CrossRef](#)] [[PubMed](#)]
5. Traill A, Stawell R, Hall A, Zamir E. Macular thickening in acute anterior uveitis. *Ophthalmology* 2007; 114:402. [[CrossRef](#)] [[PubMed](#)]
6. Rothova A. Inflammatory cystoid macular edema. *Curr Opin Ophthalmol* 2007; 18(6):487–92. [[CrossRef](#)] [[PubMed](#)]
7. Lardenoye CW, van Kooij B, Rothova A. Impact of macular edema on visual acuity in uveitis. *Ophthalmology* 2006; 113(8):1446–9. [[CrossRef](#)] [[PubMed](#)]
8. Uy HS, Christen WG, Foster CS. HLA-B27-associated uveitis and cystoids macular edema. *Ocul Immunol Inflamm* 2001; 9(3):177–83. [[CrossRef](#)] [[PubMed](#)]
9. Castellano CG, Stinnett SS, Mettu PS, McCallum RM, Jaffe GJ. Retinal thickening in iridocyclitis. *Am J Ophthalmol* 2009; 148(3):341–9. [[CrossRef](#)] [[PubMed](#)]
10. Shulman S, Goldenberg D, Habet-Wilner Z, Goldstein M, Neudorfer M. Optical coherence tomography characteristics of eyes with acute anterior uveitis. *Isr Med Assoc J* 2012; 14(9):543–6. [[PubMed](#)]
11. Moreno-Arrones JP, Gorrone-Echebarria MB, Teus-Guezala MA. Macular thickening in acute anterior uveitis with a 6-month remission period. *Can J* 2010; 45(1):91–2. [[CrossRef](#)] [[PubMed](#)]
12. Wexler A, Sand T, Elsas TB. Bilateral macular thickening in mild unilateral anterior uveitis: is HLA-B27 involved? *BMC Ophthalmol* 2012; 12:30. [[CrossRef](#)] [[PubMed](#)]
13. Wexler A, Sand T, Elsas TB. Macular thickness measurements in healthy Norwegian volunteers: an optical coherence tomography study. *BMC Ophthalmol* 2010; 10:13. [[CrossRef](#)] [[PubMed](#)]
14. Markomichelakis NN, Halkiadakis I, Pantelia E, Georgalas E, Chrysanthi K, Theodossiadis P, et al. Course of macular edema in uveitis under medical treatment. *Ocul Immunol Inflamm* 2007; 15(2):71–9. [[CrossRef](#)] [[PubMed](#)]

Originalni rad

UDC: UDC: 617.72-002:616-097
doi:10.5633/amm.2016.0406**DEBLJINA MAKULE KOD HLA B-27 POZITIVNIH
BOLESNIKA SA AKUTNIM PREDNJIM UVEITISOM**

Maja Živković¹, Marko Zlatanović¹, Gordana Zlatanović^{1,4},
Aleksandra Hristov², Vesna Jakšić³,
Marija Radenković¹, Jasmina Đorđević-Jocić^{1,4},
Gordana Stanković-Babić¹, Marija Trenkić-Božinović¹

Očna klinika, Klinički centar Niš, Niš, Srbija¹Centar za vid Maja, Niš, Srbija²Klinika za očne bolesti "Prof. dr Ivan Stanković", Kliničko-bolnički centar Zvezdara, Beograd, Srbija³Univerzitet u Nišu, Medicinski fakultet, Niš, Srbija⁴

Kontakt : Maja Živković

Radoja Dakića 47A/28, 18 000 Niš, Srbija

E-mail: drzivkovicmaja@gmail.com

Uveitisi predstavljaju zapaljenja uvealnog trakta koja se prema lokalizaciji patološkog procesa u uveji dele na: prednje, intermedijalne, zadnje i panuveitise. Akutni prednji uveitis (AAU) je najčešća manifestacija uveitisa. Skoro polovina od ukupnog broja bolesnika sa AAU je pozitivna na HLA-B27.

Cilj rada bio je ispitati promene u debljini makule kod HLA-B27 pozitivnih bolesnika sa unilateralnim akutnim prednjim uveitisom.

U studiju je bilo uključeno 15 bolesnika, starosti 30-60 godina, sa unilateralnim akutnim prednjim uveitisom, bez klinički vidljivog makularnog edema i bez dodatnih očnih oboljenja. Praćeno je kako zahvaćeno tako i drugo, zdravo oko. U kontrolnoj grupi bilo je 15 osoba bez sistemskih i očnih bolesti. Debljina makule je merena uz pomoć Cirrus SD-OCT-a (Carl Zeiss Meditec, Dublin, CA, USA). Merenje je vršeno prvog, trećeg i sedmog dana od početka bolesti. Upoređivane su vrednosti debljine makule između zahvaćenog i zdravog oka, kao i u odnosu na kontrolnu grupu.

U grupi bolesnika sa akutnim prednjim uveitisom, osam bolesnika je imalo dijagnozu M. Bechterew, petoro je bilo sa dijagnozom M. Reiter i dvoje sa psorijatičnim artritisom. Najveća prosečna debljina makule kod zahvaćenog oka registrovana je sedmog dana od početka bolesti. Tada je registrovana i statistički značajna razlika u debljini makule između zahvaćenog oka i drugog, zdravog oka, dok je u odnosu na kontrolnu grupu registrovana od prvog dana praćenja.

Pozitivni HLA-B27 kod bolesnika sa unilateralnim akutnim prednjim uveitisom pokazuju znake zadebljanja makule. *Acta Medica Medianae 2016;55(4):46-51.*

Ključne reči: akutni prednji uveitis, HLA-B27, debljina makule