

THE IMPORTANCE OF STUDYING THE PROLIFERATION MARKER KI-67 IN PRECANCEROUS CONDITIONS AND EARLY LARYNGEAL CANCER

Slaviša Radosavljević¹, Miško Živić^{2,3}, Boris Đinđić^{2,4},
Milan Stanković^{2,3}, Dragan Mihailović^{2,5}, Marija Conić-Miletić³

The incidence of malignant tumors and therewith malignant laryngeal tumors necessitates the study of pathogenesis, histology and diagnostic methods for early laryngeal cancer with the aim of eradication and treatment, and especially early detection of lesions that give rise to laryngeal cancers. The estimation of Ki-67 proliferation in biopsies of precancerous lesions in the larynx is potentially useful to determine the advancement of these lesions into laryngeal carcinoma.

The subjects of this research were patients of the ENT Clinic, Clinical Center Niš. Prospective investigation included 121 patients with precancerous conditions and laryngeal cancer.

The mean age of all examinees was 64.90 ± 10.28 years, with age range from 48 to 87. No statistically significant difference in age between female and male examinees was found ($p = 0.608$).

There was a statistically significant difference in the values of Ki-67 index in the examined groups ($p < 0.001$). A further analysis found a statistically significant difference between the normal mucosa and dysplasia grade II ($p = 0.05$), the normal mucosa and dysplasia grade III ($p < 0.001$), and the normal mucosa and laryngeal cancer ($p < 0.001$). In addition, statistically significant differences between laryngeal papillomatosis and laryngeal cancer was determined ($p = 0.05$).

The study of Ki-67 as a marker of proliferation in precancerous conditions and early laryngeal cancer is a relevant method for: a) planning therapeutic strategies b) prognosis c) evaluation of therapeutic results d) exchange of information e) continuous research and follow-up of the nature of the human laryngeal cancer.

There were statistically significant differences in Ki-67 as a marker of proliferation between the normal mucosa and dysplasia grade II, the normal mucosa and dysplasia grade III, and the normal mucosa and laryngeal cancer. *Acta Medica Medianae* 2017;56(1):24-30.

Key words: Ki-67, cancer, larynx

Primary Healthcare Center Obilić, Obilić, Serbia¹
University of Niš, Faculty of Medicine, Niš, Serbia²
ENT Clinic, Clinical Center Niš, Niš, Serbia³
Internal Clinic Clinical Center Niš, Niš, Serbia⁴
Center for Pathology and Pathological Anatomy, Clinical Center Niš, Niš, Serbia⁵

Contact: Slaviša Radosavljević
Primary Healthcare Center Obilić, 15 000 Obilić, Serbia
E-mail: radosavljevicslavisa@yahoo.com

Introduction

The incidence of malignant tumors and therewith malignant laryngeal tumors necessitates the study of pathogenesis, histology and diagnos-

tic methods for early laryngeal cancer with the aim of eradication and treatment, and especially early detection of lesions that give rise to laryngeal cancers (1).

The estimation of Ki-67 proliferation in biopsies of precancerous lesions in the larynx is potentially useful to determine the advancement of these lesions into laryngeal carcinoma (2).

The interest in the aforementioned problems is considerable. In spite of the current achievements in the detection of precancerous conditions and early laryngeal cancer, a large number of cases remain unresolved, commonly due to the ignorance of morphological and histological elements necessary for establishing the diagnoses of precancerous conditions and early laryngeal cancer.

Precancerous conditions are abnormalities of the epithelial tissue that may give rise to the development of carcinoma. The distinction between

benign and malignant tumors is not quite clear, which is why the term "precancerous condition" has been introduced.

Development of disease

Squamous intraepithelial neoplasms grade 1 can be classified as precancerous lesions. Inadequately treated carcinoma in situ almost always develops into infiltrating carcinoma. After 5-7 years, grade 3 lesions develop into carcinoma. No one can exactly predict when carcinoma in situ will transform into cancer. Small carcinoma in situ can be destroyed by performing biopsy which is necessary for making the diagnosis.

Clinical aspects

Precancerous conditions of the larynx commonly develop on the vocal cords, and rarely on other sites in the larynx. These conditions are more frequent in men aged between 50 and 70. Carcinoma in situ as microcarcinoma can be easily removed from the surface of the vocal cords. Commonly, precancerous lesions spread along the free edge of the vocal cord up to the surface of the subglottis. It should be emphasized that every precancerous lesion cannot be seen as keratinization of the surface. One third of carcinomas in situ present as erythroplakias. All erythroplakias are carcinoma in situ. The development of carcinoma during chronic laryngitis is accompanied by the appearance of fine nodules or multiple warty growths. Malignant degeneration in chronic laryngitis differs from the superficial carcinoma. The appearance and development of precancerous lesions in the larynx are not defined, and can last for months and years. The chief symptoms following the appearance of precancerous lesions are changes in the voice, dysphagia, cough, scratchy throat, soar throat, and hoarseness.

Clinical examination of the larynx requires taking a history from a patient, inspection and palpation. Indirect and direct laryngoscopy as well as laryngomicroscopy are applied as additional diagnostic methods. Laryngoscopy is used for the detection of changes. Laryngomicroscopy is performed with the aim of determining the size of the pathological process and taking a sample for histopathological examination. Also, it is applied for the removal of benign tumors.

Treatment

After setting the histopathological diagnoses of the changes in the larynx, it is necessary to perform surgery in order to remove lesions and lymph nodes in the neck. In the case of limited lesions with low-grade dysplasia, it is possible to achieve complete healing with obligatory cessation of smoking and alcohol use, voice rest, and prevention of infections. In more severe cases and the occurrence of metastases, the application of radiation therapy and chemotherapy is indicated.

Research subjects

The subjects of this research were patients of the ENT Clinic, Clinical Center Niš. Prospective investigation, including 121 patients with precancerous conditions and laryngeal cancer, was carried out from 2012 to 2014. Pathohistological verification was done in the Center for Pathology and Pathological Anatomy.

Methods

During the research, the following methods were used:

1. Clinical examination (history taking, indirect laryngoscopy)
2. Laryngeal videostroboscopy
3. Laryngomicroscopy
4. Pathology diagnostics of precancerous conditions and laryngeal carcinoma in correlation with nuclear antigen Ki-67 as a marker of proliferation.

Stroboscopy stands for an optical method for observing fast successive movements. An image is an illusion of the object visualized so that it appears to be motionless.

Laryngomicroscopy is the examination of larynx using a surgical microscope. Today, it is performed under general endotracheal anesthesia.

If it is not possible to introduce the patient into the endotracheal anesthesia due to the tumor size, then tracheotomy should be performed.

Laryngomicroscopy is the most reliable method to determine the mucosal spread of the tumor. At the same time, it is the safest method for taking a sample of tumor tissue for the histological examination. This is the only method used for observing the Morgagni's sinus by lifting and moving aside the ventricular fold.

Pathohistological diagnostics of precancerous conditions and laryngeal cancer is done by staining, usually utilizing some of the standard methods: a) hematoxylin-eosin (where nuclei stain blue, while cytoplasm stains pink); b) trichromatic staining by Mallory or Gieson; c) silver impregnation by Gomori; d) Sudan, Congo, mucicarmine stains and others.

Aims

By performing a prospective analysis of the clinical material of the ENT Clinic in Niš and biopsy specimens from the Center for Pathology and Pathological Anatomy Niš, the aims of the research were to determine:

1. The incidence of precancerous conditions and laryngeal cancer.
2. Age and gender distribution of patients with precancerous conditions and laryngeal cancer.
3. The nuclear antigen Ki-67 as a marker of proliferation in precancerous conditions and early laryngeal cancer.

4. The importance of Ki-67 proliferation marker in biopsy materials for further therapy (laryngectomy, radiation therapy, chemotherapy).

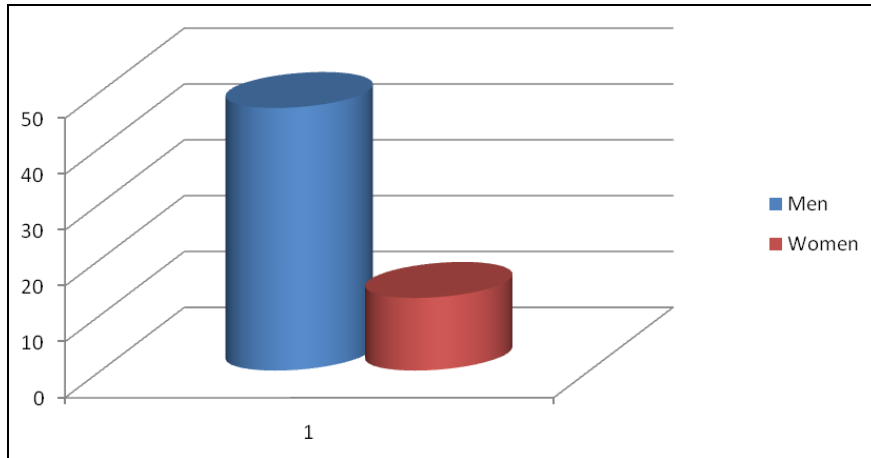
which 7 (11.5 %) women and 54 (88.5%) men (Graph 1).

The mean age of all examinees was 64.90 ± 10.28 years, with age range from 48 to 87. The mean age of female examinees was 67.00 ± 11.13 years, whereas the mean age of male examinees was 64.63 ± 10.25 years. No statistically significant difference in age between female and male examinees was found ($p = 0.608$).

Results

Demographic characteristics of patients

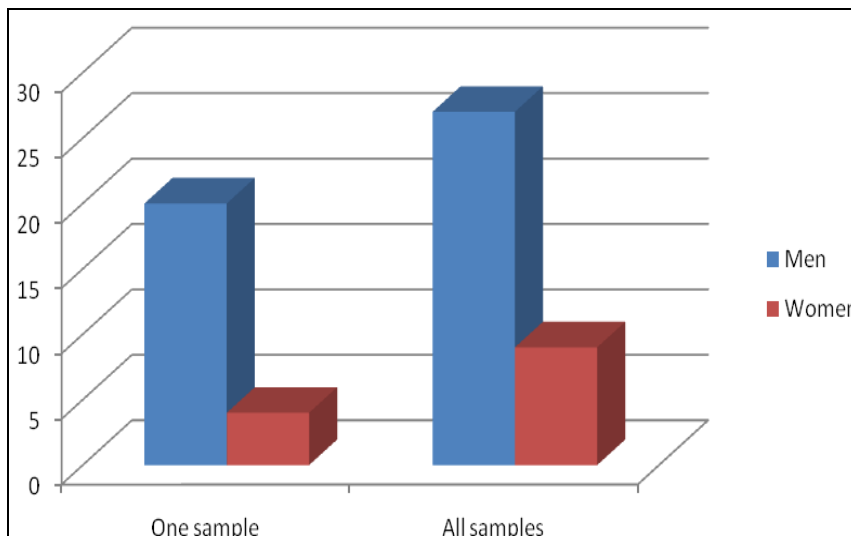
The research included 61 examinees, of



Graph 1. Distribution of examinees by gender

Table 1. Distribution of patients with regard to duration of smoking

Duration of smoking											
Sex	Non-smokers	15 years	20 years	25 years	30 years	35 years	40 years	45 years	50 years	55 years	60 years
Men	1	1	3	3	15	3	16	3	4	3	1
n(%)	(50,0)	(100,0)	(60,0)	(100,0)	(88,2)	(75,0)	(94,1)	(75,0)	(100,0)	(100,0)	(100,0)
Women	1	0	2	0	2	1	1	1	0	0	0
n(%)	(50,0)	(0,0)	(40,0)	(0,0)	(21,8)	(25,0)	(5,9)	(25,0)	(0,0)	(0,0)	(0,0)
Total	2	1	5	3	17	4	17	4	4	3	1
n(%)	(100,0)	(100,0)	(100,0)	(100,0)	(100,0)	(100,0)	(100,0)	(100,0)	(100,0)	(100,0)	(100,0)



Graph 2. Graphic presentation of dysplasias according to sex

Duration of smoking

Of all the examinees, there were only 2 (3.3%) smokers – one man and one woman. There was no statistically significant difference between smokers and non-smokers with regard to sex ($\chi^2 = 3.02$, $p = 0.082$).

The largest number of patients smoked between 30 and 40 years. There was no statistically significant difference in the length of smoking experience with respect to gender ($\chi^2 = 7.30$, $p = 0.504$) (Table 1) (Graph 2).

Dysplasias

Out of 60 subjects in total diagnosed with precancerous lesions of the larynx, there were 47 (78.3%) males and 13 (21.7%) females (Table 2).

The table shows the distribution of dysplasias in biopsy samples according to the sex. The number of males diagnosed with dysplasias was higher compared to the number of females. There were 20 males with dysplasia in one sample i.e. 42.55% with regard to the analyzed male group, and 33.33% with respect to the total number of patients (60). It was found that there were 27 men with dysplasia in all the samples, i.e. 57.45% with regard to the analyzed group of male patients, and 45% with regard to the total number of examinees. There were 4 females with dysplasia in one sample, i.e. 30.77% with regard to the analyzed group of female patients, and 6.7% with regard to the total number of the examinees. It was determined that there were 9 females with dysplasia in all the samples, i.e. 69.23% in regard to the female population, i.e. 15% in regard to the total number of the examinees. Statistically significant difference in the distribution of dysplasias

Table 2. Distribution of dysplasias of samples according to sex

Sex	Samples		Total n(%)
	One sample	All samples	
Men n (%)	20 (83,3)	27 (75,0)	47 (78,3)
Women n(%)	4 (16,7)	9 (25,0)	13 (32,7)
Total n (%)	24 (100,0)	36 (100,0)	60 (100,0)

Table 3. The values of Ki-67 index in the examined groups

Groups	KI67* (AS±SD)
Normal mucosa	14.0±1.7
Laryngeal papillomatosis	22.1±1.4
Dysplasia gr.I	29.5± 1.1
Dysplasia gr.II	32.6± 6.5
Dysplasia gr.III	37.3±7.1
Laryngeal cancer	44.5±8.0

*Values of KI 67 expressed in %

as was not found ($\chi^2 = 0.59$, $p = 0.442$) (Graph 2).

There was a statistically significant difference in the values of Ki-67 index in the examinee groups ($p < 0.001$). A further analysis found a statistically significant difference between the normal mucosa and dysplasia grade II ($p = 0.05$), the normal mucosa and dysplasia grade III ($p < 0.001$), and the normal mucosa and laryngeal cancer ($p < 0.001$). In addition, statistically significant differences between laryngeal papillomatosis and laryngeal cancer was determined ($p = 0.05$) (Table 3) (Graph 3) (Figures 1 and 2).

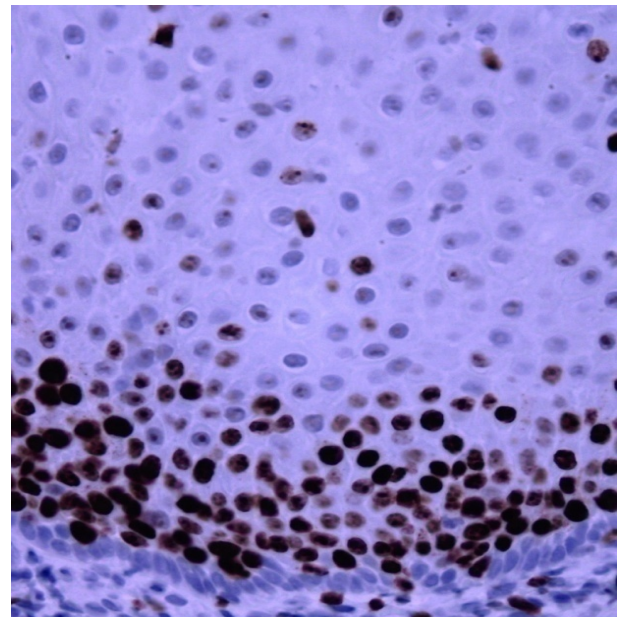


Figure 1. Dysplasia grade I and Ki-67 obj x 20, Ki-67 = 29.5% (±1.1)

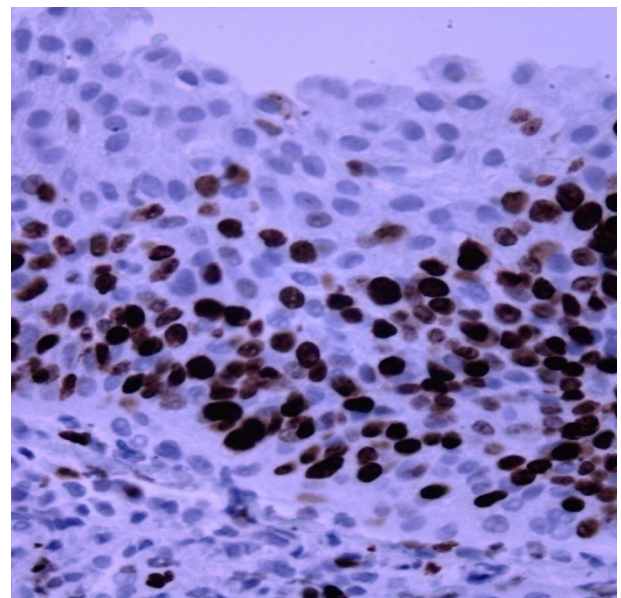
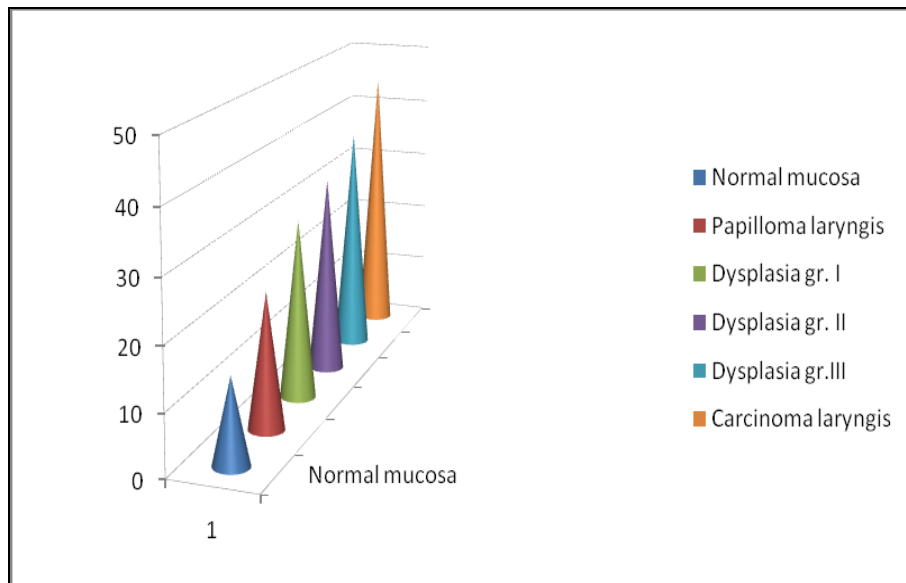


Figure 2. Dysplasia grade II and Ki-67 obj x 20, Ki-67=32% (±6.5)



Graph 3. The values of Ki-67 index in the examined groups

Discussion

Precancerous conditions and early laryngeal cancers are common in people who consume alcohol and tobacco. Industrial pollution and unhealthy foods also contribute to the occurrence of laryngeal cancer. Precancerous conditions precede cancer and can be recognized microscopically. For this reason, a detailed study of pathogenesis, histology of early diagnosis of laryngeal lesions and timely treatment is necessary (1). Histological diagnosis of precancerous conditions and laryngeal cancer is set on the basis of cytological changes in the biopsy tissue (3). A direct laryngoscopy and tumor biopsy or excision were essential for establishing a correct diagnosis (4, 5). Diagnosis was possible only after resection of representative material from the center of tumor, so that reactive changes in the neighborhood of another process (carcinoma) were definitely ruled out (6). Correlation of differential biomarker expression with diverse biological behavior in head and neck cancers need further investigations (7). Interest in identifying biomarkers capable of predicting the likelihood of cervical lymph node metastasis from a primary tumor specimen is being developed to enable the separation of patients at high risk for occult metastases from those at low risk (8).

Precancerous lesions are defined as epithelial abnormalities which can give rise to the development of carcinoma. A naked eye examination is not very reliable to confirm the diagnosis; therefore, histological examination of the biopsy tissue is necessary in order to verify the diagnosis. Our research involved 61 examinees with the verified diagnosis of laryngeal cancer, of which 7 (11.5%) examinees were female and 54 (88.5%) examinees were male. The mean age of all examinees was 64.90 years, with age range from 48 to 87 years. The mean age of the female examinees was 67 years, and 64.63 years for the male examinees.

Smoking was one of the high-risk factors responsible for the development of laryngeal cancer. Duration of smoking was presented according to the sex of examinees. In the table presenting the distribution of examinees with regard to duration of smoking, there were only 2 (3.3%) non-smokers – one man and one woman. In the research, a statistically significant difference between smokers and non-smokers in regard to the sex of examinees was not found ($p = 0.082$). The largest number of males was smokers. Chemical irritation is very important, and besides smoking, air pollution and harmful irritating gasses in mines, laboratories and factories vastly contribute to this problem. Chemical agents are the cause of metaplastic and hyperplastic changes on the laryngeal mucosa.

Alcohol consumption also exerts negative effects on the laryngeal mucosa, not directly but via the consequent hyperemia. Chronic infection is the etiological factor. Chronic inflammatory conditions, supported by professional factors, are considered to play a significant role in the etiology of precancerous conditions and early laryngeal cancer. Our participants smoked for 30 and 40 years.

Local tumor spread with regard to the sex, which is shown in Table 1, shows that the largest number of male examinees was in stages T2 and T3. The largest number of women were in stage T1 of the local tumor spread. Statistically significant differences in the local tumor spread in regard to the sex were found ($X^2 = 33.07$; $p < 0.001$).

The estimation of Ki-67 proliferation in biopsy specimens with precancerous lesions of the larynx is potentially useful for predicting the advancement towards laryngeal cancer (2). In laryngeal cancer, the presence of possible regional metastases denoted as N0, N1, N2 and N3 is expected, which depends on the tumor size i.e. the

size of the lymph gland. The relapse-free survival is even better predicted than by Ki-67 staining (9).

Early diagnosis is an important precondition in the treatment of precancerous conditions and early laryngeal cancer (10).

There was a statistically significant difference in the values of Ki-67 index in the examined groups ($p < 0.001$). A further analysis found a statistically significant difference between the normal mucosa and dysplasia grade II ($p = 0.05$), the normal mucosa and dysplasia grade III ($p < 0.001$), and the normal mucosa and laryngeal cancer ($p < 0.001$) (11). In addition, statistically significant differences between laryngeal papillomatosis and laryngeal cancer was determined ($p = 0.05$). Ki-67 is a known cancer cell proliferation antigen currently used in prognostic evaluation (12).

Conclusion

The study of Ki-67 as a marker of proliferation in precancerous conditions and early laryngeal

cancer is a relevant method for: a) planning therapeutic strategies; b) prognosis; c) evaluation of therapeutic results; d) exchange of information; e) continuous research, and follow-up of the nature of the human laryngeal cancer.

There were statistically significant differences in Ki-67 as a marker of proliferation between the normal mucosa and dysplasia grade II, the normal mucosa and dysplasia grade III, and the normal mucosa and laryngeal cancer.

The difference in Ki-67 as marker of proliferation between laryngeal papillomatosis and laryngeal cancer was statistically significant.

There is an increasing trend in the number of diseased males in whom benign conditions of the larynx turn into cancerous changes, as well as a decreasing trend in the number of females whose benign changes of the larynx turn into laryngeal cancer.

The largest number of examinees smoked for 30-40 years. There was no statistically significant difference in duration of smoking with respect to the sex of examinees ($\chi^2 = 7.30$, $p = 0.504$).

References

1. de Oliveira Semenzati G, de Souza Salgado B, Rocha NS, Michelin Matheus SM, de Carvalho LR, Garcia Martins RH. Histological and immunohistochemical study of the expression of p53 and ki-67 proteins in the mucosa of the tongue, pharynx and larynx of rats exposed to cigarette smoke. *Inhal Toxicol* 2012; 24(11):723-31. [[CrossRef](#)] [[PubMed](#)]
2. Ashraf MJ, Maghbul M, Azarpira N, Khademi B. Expression of Ki67 and P53 in primary squamous cell carcinoma of the larynx. *Indian J Pathol Microbiol* 2010; 53(4):661-5. [[CrossRef](#)] [[PubMed](#)]
3. Calli C, Calli A, Pinar E, Oncel S, Tatar B. Prognostic significance of p63, p53 and ki67 expression in laryngeal basaloid squamous cell carcinomas. *B-ENT* 2011; 7(1):37-42. [[PubMed](#)]
4. Anghelina F, Ioniță E, Chiuțu L, Mogoantă CA, Ciolofan S, Iosif C, Ceaușu M. Malignant fibrous histiocytoma of larynx with giant cell: case report and histological-clinical considerations. *Rom J Morphol Embryo* 2009; 50(3):481-5. [[PubMed](#)]
5. Rodrigues RB, Motta Rda R, Machado SM, Cambruzzi E, Zettler EW, Zettler CG, et al. Prognostic value of the immunohistochemistry correlation of Ki-67 and p53 in squamous cell carcinomas of the larynx. *Braz J Otorhinolaryngol* 2008; 74(6):855-9. [[CrossRef](#)] [[PubMed](#)]
6. Völker HU, Scheich M, Zettl A, Hagen R, Müller-Hermelink HK, Gattenlöhner S. Laryngeal inflammatory myofibroblastic tumors: Different clinical appearance and histomorphologic presentation of one entity. *Head Neck* 2010; 32(11):1573-8. [[CrossRef](#)] [[PubMed](#)]
7. Tamás L, Szentkúti G, Eros M, Dános K, Brauswetter D, Szende B, et al. Differential biomarker expression in head and neck cancer correlates with anatomical localization. *Pathol Oncol Res* 2011; 17(3):721-7. [[CrossRef](#)] [[PubMed](#)]
8. Boonkitticharoen V, Kulapaditharom B, Leopairut J, Kraiphikul P, Larbcharoensub N, Cheewaruangroj W, et al. Vascular endothelial growth factor a and proliferation marker in prediction of lymph node metastasis in oral and pharyngeal squamous cell carcinoma. *Arch Otolaryngol* 2008; 134(12):1305-11. [[CrossRef](#)] [[PubMed](#)]
9. Cordes C, Münzel AK, Görögh T, Leuschner I, Ambrosch P, Gottschlich S, et al. Prognostic relevance of the proliferation marker REPP86 for laryngeal cancer. *Anticancer Res* 2010; 30(9):3541-7. [[PubMed](#)]
10. Cordes C, Münzel AK, Rudolph P, Hoffmann M, Leuschner I, Gottschlich S. Immunohistochemical staining of Ki-67 using the monoclonal antibody Ki-67 is a prognostic indicator for laryngeal squamous cell carcinoma. *Anticancer Res* 2009; 29(4):1459-65. [[PubMed](#)]
11. Bai Y, Shao Y, Li H, Xue W, Quan F, Wu S. Ki-67 is overexpressed in human laryngeal carcinoma and contributes to the proliferation of Hep2 cells. *Oncol Lett* 2016; 12(4):2641-7. [[CrossRef](#)] [[PubMed](#)]
12. Nowinska K, Chmielewska M, Piotrowska A, Pula B, Pastuszewski W, Krecicki T, et al. Correlation between levels of expression of minichromosome maintenance proteins, Ki-67 proliferation antigen and metallothionein I/II in laryngeal squamous cell cancer. *Int J Oncol* 2015; 48(2):635-45. [[CrossRef](#)] [[PubMed](#)]

Originalni rad

UDC: 616.22-006.6
doi:10.5633/amm.2017.0104**ZNAČAJ IZUČAVANJA KI-67 MARKERA
PROLIFERACIJE KOD PREKANCEROZA I
RANOG KARCINOMA LARINKSA***Slaviša Radosavljević¹, Miško Živić^{2,3}, Boris Đinđić^{2,4},
Milan Stanković^{2,3}, Dragan Mihailović^{2,5}, Marija Conić-Miletić³*

Dom zdravlja Obilić, Obilić, Srbija¹
Univerzitet u Nišu, Medicinski fakultet, Niš, Srbija²
Klinika za uho, grlo i nos, Klinički centar Niš, Srbija³
Interna klinika, Klinički centar Niš, Srbija⁴
Centar za patologiju i patološku anatomiju, Klinički centar Niš, Srbija⁵

Kontakt: Slaviša Radosavljević
Dom zdravlja Obilić, Obilić, 15 000 Obilić, Srbija
E-mail: radosavljevicslavisa@yahoo.com

Učestalost malignih tumora, pa samim tim i malignih tumora larinksa, ukazuje na potrebu izučavanja patogeneze, histologije i metoda dijagnoze raznih lezija larinksa u cilju efikasnijeg suzbijanja i lečenja, a naročito ranog otkrivanja lezija iz kojih se razvijaju karcinomi larinksa. Procena proliferacije Ki-67 u biopsijama prekanceroze larinksa je potencijalno korisna za predviđanje napredovanja karcinoma larinksa.

Predmet istraživanja su bolesnici Kliničkog centra Niš ORL klinike. Prospektivnim ispitivanjem obuhvaćen je 121 bolesnik sa prekanceroznim stanjima i karcinomom larinksa. Prosečna starost svih ispitanika iznosila je 64,90±10,28 godina, sa rasponom od 48 do 87 godina. Nije utvrđena statistički značajna razlika u starosti između pripadnika muškog i ženskog pola ($p = 0,608$). Utvrđeno je postojanje statistički značajne razlike u vrednostima Ki-67 indeksa u ispitivanim grupama ($p < 0,001$). Daljom analizom utvrđeno je postojanje statistički značajne razlike između normalne mukoze i displazije gradusa II ($p = 0,05$), normalne mukoze i displazije gradusa III ($p < 0,001$) i normalne mukoze i karcinoma larinksa ($p < 0,001$). Takođe je utvrđeno postojanje statistički značajne razlike između papiloma larinksa i karcinoma larinksa ($p = 0,05$).

Izučavanje Ki-67 markera proliferacije kod prekanceroza i ranog karcinoma larinksa je značajan metod u: a) planiranju terapijske strategije b) prognozi c) evaluaciji terapijskih rezultata d) razmeni informacija e) kontinuiranom istraživanju i praćenju prirode humanog karcinoma larinksa. Statistički značajna razlika postoji u Ki-67 markeru proliferacije između normalne mukoze i displazije larinksa gradusa II i normalne mukoze i displazije gradusa III i normalne mukoze i karcinoma larinksa. *Acta Medica Medianae* 2017;56(1):24-30.

Ključne reči: Ki-67, karcinom, larinks

This work is licensed under a Creative Commons Attribution 4.0 International (CC BY 4.0) Licence