

## IMPORTANCE OF COMPUTED TOMOGRAPHY IN THE DIAGNOSIS OF HEAD AND NECK INFECTIONS

*Slađana Petrović<sup>1,2</sup>, Aleksandra Milenković<sup>3</sup>, Milan Stojanović<sup>3</sup>,*

*Maja Jocić<sup>1</sup>, Filip Petrović<sup>2</sup>, Dragan Stojanov<sup>1,2</sup>*

Head and neck infections are a group of disorders that can be accompanied by serious complications with an extent that is hard to estimate. Although their occurrence has significantly decreased due to the use of antibiotic and improvements in oral hygiene in modern times, there still exists a high rate of morbidity and mortality of these infections. A complex anatomy and communications between spaces in this region favor the spread of these processes and can lead to life-threatening conditions such as airway obstruction, empyema, mediastinitis, thrombophlebitis, pericarditis and septic shock.

Computerized tomography (CT), as a method of choice in emergency conditions of the head and neck region, allows a fast and accurate diagnosis, estimation of the disease spread and potential complications. *Acta Medica Medianae 2017;56(2):70-77.*

**Key words:** head and neck infections, complications, CT

---

Clinical Center Niš, Institute of Radiology, Niš, Serbia<sup>1</sup>  
University of Niš, Faculty of Medicine, Niš, Serbia<sup>2</sup>  
University of Priština, Faculty of Medicine, temporarily seated in  
Kosovska Mitrovica<sup>3</sup>

Contact: Slađana Petrović  
Faculty of Medicine, University of Niš,  
Boulevard Dr Zorana Đinđića 81, 18000 Niš  
e-mail: sladjana-petrovic@hotmail.com

### Introduction

Head and neck infections are a group of disorders that can be accompanied by serious life-threatening complications such as airway obstruction, empyema, mediastinitis, thrombophlebitis, pericarditis and septic shock. Although their occurrence has significantly decreased due to the use of antibiotics and better oral hygiene of modern men, there are still high rates of morbidity and mortality of these infections (1).

These infections are most often odontogenic or oropharyngeal by origin, with polymicrobial etiology. Less frequent causes include suppurative lymphadenitis, salivary gland infections, penetrating injuries of the pharynx or neck segments of the esophagus and spondylodiscitis. Clinical manifestations of these infections can be in the form of a fever, pain, edema, sore throat, dysphagia, odynophagia, trismus or stridor (2).

A thorough knowledge of the anatomical regions of head and neck is a necessary prerequisite for an adequate assessment of the infective conditions affecting these regions. Due to its complexity, it represents a huge challenge for a diagnostic radiologist, requiring the knowledge of radiological ana-

tomy, common pathology and usual disease spread routes in this region.

The use of computerized tomography (CT) as the imaging technique/method of choice in emergency conditions and knowledge of the radiological signs of acute conditions affecting this region are of immense importance for a fast and accurate diagnosis, estimation of the extent of the disease, potential complications and further therapeutic planning. Magnetic resonance imaging examination has a secondary role in the diagnosis of head and neck infections (3).

### Anatomy and classification of the head and neck

The complex anatomy and communications between fascial spaces of the head and neck region potentiate the spread of pathological processes and can ultimately lead to life-threatening conditions. The knowledge of the anatomy of this region has a crucial role in the understanding and diagnosis of the infections in the region.

The superficial cervical fascia (fascia cervicalis superficialis) is a connective tissue layer, filled with fatty tissue, which surrounds the neck and contains the platysma muscle, lymph nodes, nerves and blood vessels.

The deep cervical fascia (fascia cervicalis profunda) consists of three layers: superficial, medial and deep. The superficial layer is located below the platysma and spreads from the base of the skull to the sternum, clavicle and scapula. It involves the sternocleidomastoid and trapezius muscles, surrounds the parotid and masseteric spaces, forms a fascia from the omohyoid muscle, while at the anterolateral edge it is

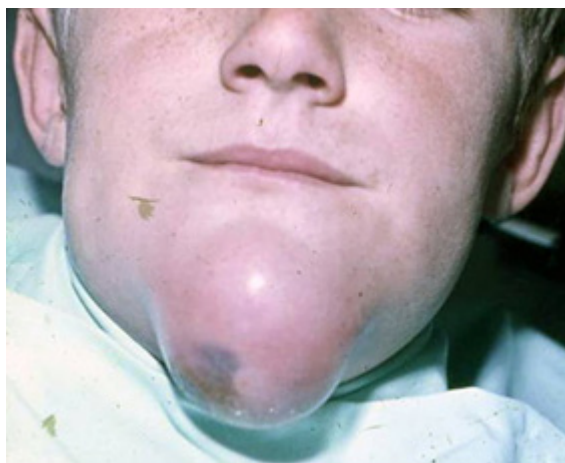involved in the formation of the carotid sheath. The middle or buccopharyngeal (visceral) layer of the deep cervical fascia spreads medially from the base of the skull towards and continues with the pericardium. Its muscle part surrounds the infrahyoid muscles, while the visceral part of this layer encloses the thyroid gland, parathyroid glands, larynx, trachea, pharynx, forming the visceral neck space. At the same time, it is the anterior border of the retropharyngeal space and a part of the carotid sheath laterally. Deep or prevertebral layer of the deep cervical fascia spreads from the base of the skull towards its medial layer in the inferior direction, where they fuse and continue towards the mediastinum. It surrounds the prevertebral muscles, brachial plexus, phrenic nerve and vertebral blood vessels. It leans upon the transversal processes of the cervical vertebrae forming the anterior boundary of the prevertebral space, while on the lateral side it limits the retropharyngeal and carotid spaces (4).

Based on the boundaries of these fascial layers and their position in respect to the hyoid bone, all spaces of this region can be divided into supra and infrahyoid ones. The suprahyoid cervical space, the area above the hyoid bone, encompasses two parapharyngeal, pharyngeal mucosal, masticatory, parotid, carotid, buccal, retropharyngeal and perivertebral spaces. These spaces are the spaces from the base of the skull to the hyoid bone, excluding the orbit, sinonasal complex and oral cavity.

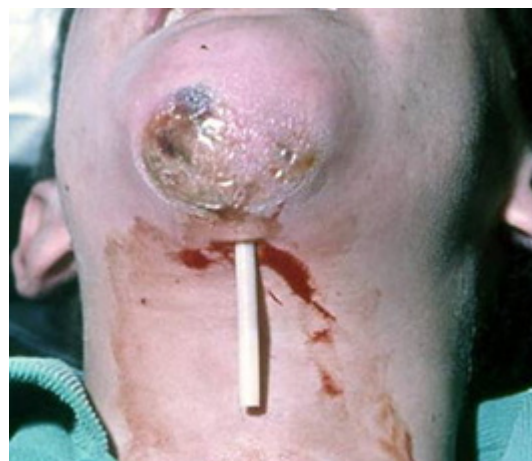The infrahyoid space of the neck is mostly located below the hyoid bone, including some areas that propagate to the mediastinum and suprahyoid space. It encloses the visceral neck space, anterior and posterior cervical, carotid, retropharyngeal and perivertebral spaces (4, 5).

### Infections of the oral cavity, masticatory and parotid spaces

These infections are most often odontogenic by origin. They arise from tooth decay with the affected pulp or root, and are associated with the risk of forming a periapical abscess.



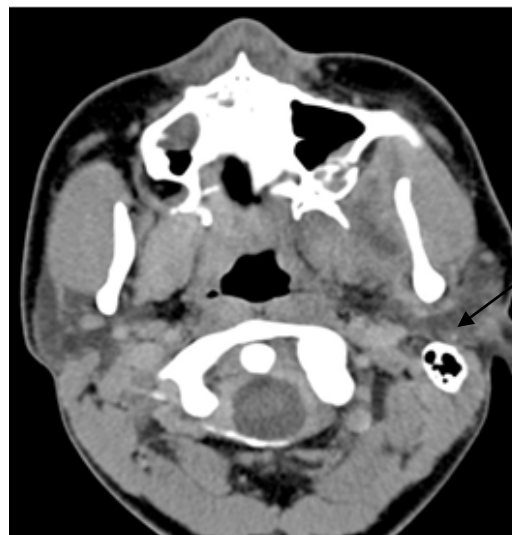**Figure 1. a)** Clinical aspect of a patient with submental abscess



**Figure 1. b)** The condition after incision

When the infection arises from the second or third molars, it can spread to the submandibular space, since the roots reach below the connection of the mylohyoid muscle, while the ones originating from the front teeth are spreading to the sublingual space (3) (Figure 1). Additionally, these infections can spread to the masticatory and parapharyngeal spaces.

Postcontrast CT examination is most frequently used for the evaluation of these regions and in situations when a periodontal abscess is suspected, because there is a clear postcontrast edge increase in the liquid collection. The process can be localized inside the mandible and can cause osteomyelitis or can expand to extraosseal spaces in the form of an abscess or diffuse cellulitis. In the bone window of a CT examination, cortical bone defects of the mandible can be observed. The signs of mandibular osteomyelitis, such as bone destruction and periosteal reaction, can also be seen.



**Figure 2.** Phlegmon of the left pterygomandibular space Axial CT view, hypodense liquid collection of the left pterygomandibular space (arrow) without postcontrast increase, with a muscle edema on the same side and a compression of the left lateral wall of the pharynx can be seen

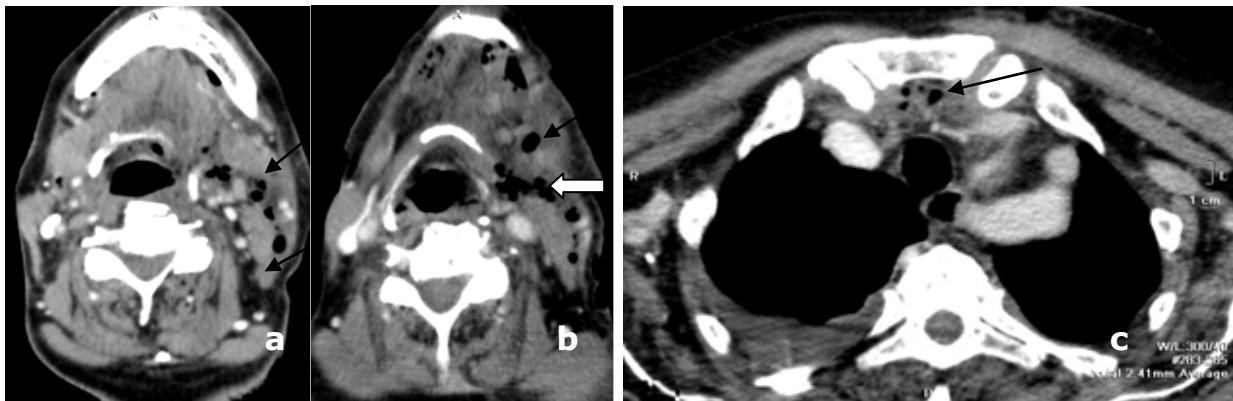
A cellulitis may present as a postcontrast increase in the density of the skin and fascias and alterations in fatty tissue morphology as a consequence of the infection. If the process, along with the skin and subcutaneous fatty tissues, affects the muscles in the form of a diffuse inflammation, the term phlegmon is used (2, 3, 4) (Figure 2).

An abscess is a localized collection with suppurative content, formed after tissue destruction in the presence of an infection; postcontrast imaging reveals an increase in capsular density, while the contents remain hypodense.

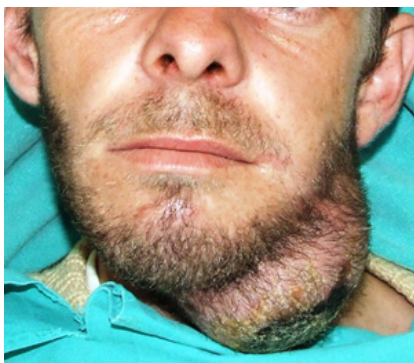Ludwig's angina is a serious, potentially life-threatening infection of the floor of the mouth which spreads fast on both sides. This is the form of a phlegmonous diffuse suppurative inflammation, most frequently occurring after a lower jaw molar streptococcal infection which rapidly spreads to the submandibular and sublingual spaces. Upon CT examination, a diffuse and intense postcontrast density increase can be seen, affecting the skin and subcutaneous tissues, with an increase of the subcutaneous fatty tissue attenuation in this region. Since submandibular spaces communicate in the posterior direction with the para-

pharyngeal region, an aggressive infection can spread caudally, leading to a compromised airway. Additionally, complications such as venous thrombosis, osteomyelitis, etc., can occur (Figure 3). Sialadenitis of the oral cavity salivary glands most frequently affects the submandibular gland and represents the inflammation of this gland with stenosis or calculosis of its excretory ducts. The process is most commonly unilateral and caused by *Staphylococcus aureus*. In the case of an acute inflammation, the gland is enlarged and a postcontrast density increase with an excretory duct dilatation, accompanied by stenosis or calculosis, can usually be observed. A chronic process presents as a unilateral atrophy and fatty infiltration of the submandibular gland, with an excretory duct dilatation. Accompanying these processes, the cellulitis and myositis of the submandibular and sublingual spaces could occur as well. (Figure 4).

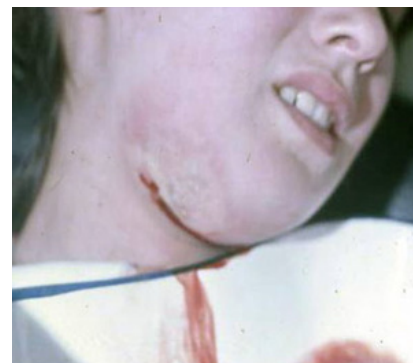The most common infective condition of the parotid region is the parotid gland sialadenitis. Acute suppurative parotitis is predominantly unilateral and is caused by *S.aureus*, representing a localized infection. It affects the elderly, frail and exhausted patient and newborns. In contrast to this form, viral parotitis is a systemic condition,



**Figure 3.** Phlegmon and abscesses of the submandibular region and the carotid space Postcontrast axial CT view, multiple abscesses with gas inclusions in the left submandibular region (black arrow) and an obliteration of the subcutaneous fatty tissues (white arrow) after incision (a,b); process expansion into the superior part of the frontal mediastinum (c)

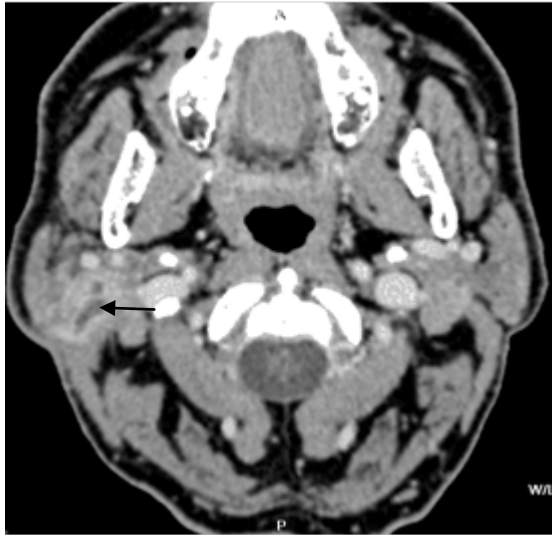


**Figure 4.** a) Clinical aspect of a patient with submandibular abscess



b) the condition after incision

most often caused by mumps, Paramyxovirus, and it affects both glands. It is predominantly encountered in children. Depending on the cause, the parotid glands can be both uni and bilaterally enlarged, with poorly defined edges and with a postcontrast density increase (Figure 5).



**Figure 5.** Parotid gland abscess

Axial CT view, inside the right parotid gland a presence of a hypodense liquid accumulation with an edge post contrast density increase (arrow) can be seen

The low attenuation values inside the gland point to a complication of the parotitis, an abscess with a potential to rupture into the deep neck spaces.

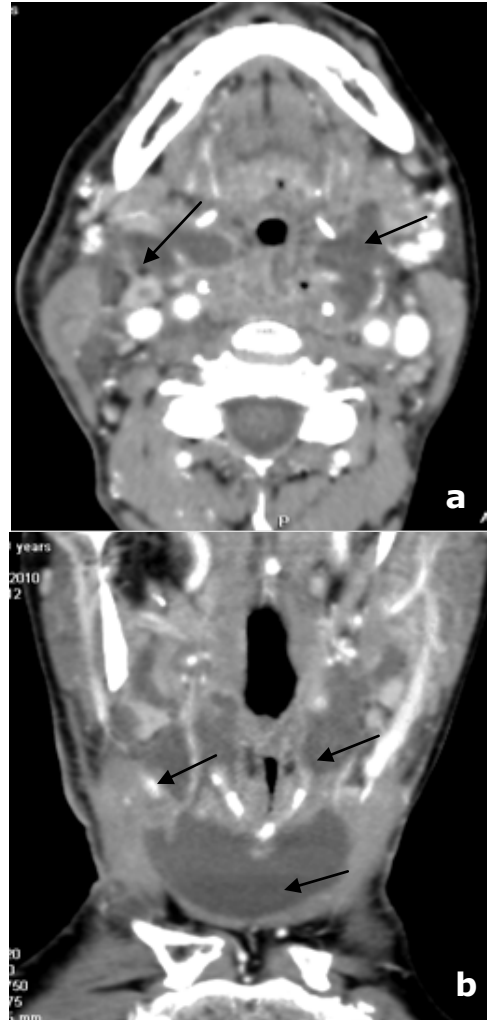
Other complications of this region include thrombosis or thrombophlebitis of the retromandibular vein, dysfunction of the VII cranial nerve, etc. (3).

On CT examination, the abscess presents as an ovoid mass with liquid density, most commonly smaller than 3 cm, localized in the sublingual space with a postcontrast increase of the surrounding soft tissues.

### Infections of the pharyngeal mucosal space

Centrally situated, parapharyngeal spaces are in close contact with most of the neck regions, representing a place for the potential spread of an infection; for this reason, a thorough examination of this region is required. Infective processes frequently extend from the pharyngeal wall and palatine tonsils to this space, in a similar way as odontogenic processes from the oral cavity. Other sources of the infections include the parotid glands, mastoid, or middle ear. A peritonsillar abscess is formed by an abscess spreading from the tonsils through the fibrous capsule to the peritonsillar space. Affecting the superior pharyngeal constrictor muscle, the process expands to involve the parapharyngeal region, which pre-

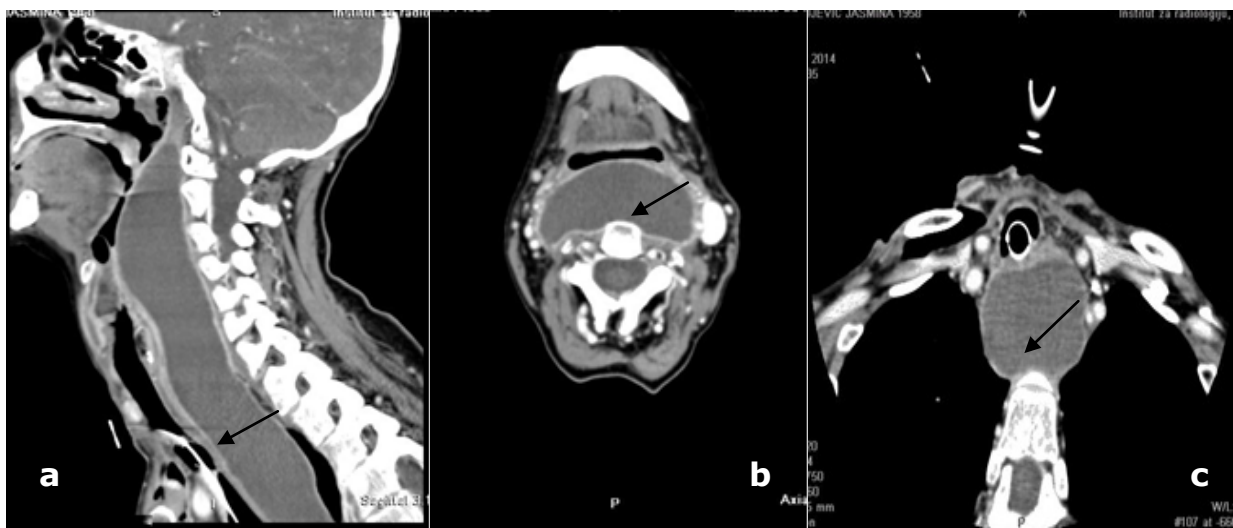
sents on a CT image as a hypodense, well-defined lesion which represses the surrounding fatty tissues, shifting the pharyngeal wall and tonsils medially and with regional lymphadenopathy. After contrast administration, the abscess shows an edge density increase. (Figure 6)



**Figure 6.** Axial (a) and coronal (b) CT views, in the parapharyngeal, carotid and anterior neck spaces multiple liquid collections, with an edge postcontrast density increase, could be seen

Tonsillar and peritonsillar abscesses can also spread directly along the upper aerodigestive tract (visceral space).

Carotid space is the fascia-surrounded space and infections involving this space are uncommon. However, an infectious process from the parapharyngeal region can pierce the carotid sheath and cause thrombophlebitis of the internal jugular vein. Upon imaging, in acute cases, the extended internal jugular vein occluded with a blood clot, with the inflammation of the surrounding soft tissues and blood vessel wall, is seen as a post-contrast density increase. In the chronic phase, the blood clot is seen without the surrounding inflammation. Venous collaterals could be seen as well.



**Figure 7.** Retropharyngeal abscess

Sagittal (a) and axial (b,c) CT views, in the retropharyngeal space, a hypodense liquid collection with an edge postcontrast density increase and spreading to the anterior mediastinum can be observed

Lemierre's syndrome is a rare but life threatening condition which is characterized by an oropharyngeal infection, septic thrombophlebitis of the internal jugular vein and multiple metastatic abscesses. It can be seen mostly in healthy children and young persons and the disease is caused by *Fusobacterium necrophorum*. A metastatic infection generally affects the lungs (septic emboli) and large joints and causes the formation of hepatic and splenic abscesses (2, 6).

#### Infections of the retropharyngeal space

Infections of this space are commonly the result of an infection spreading from the regions the lymph drainage of which occurs through the retropharyngeal lymph nodes and they include tonsillitis, pharyngitis, otitis, sinusitis, or oral cavity infections. In adults, secondary infections caused by foreign objects or trauma are common. Lymph nodes are reactively enlarged and can be seen in the form of an abscess.

Acute suppurative lymphadenitis is most common in pediatric populations. A postcontrast CT scan shows central areas of the node with low attenuation, with a peripheral density increase. Inflammation of the surrounding tissues may present as cellulitis (Figure 7).

If treated inadequately, suppurative lymph nodes can rupture into the retropharyngeal space and cause a retropharyngeal abscess, which in the end may be a life-treating condition for the affected patient. In addition, a direct spread from the locally occurring discitis or osteomyelitis can lead to this complication. The process progresses rapidly and can cause airway compromise and mediastinitis.

Postcontrast CT or MRI can precisely localize the infection and they could be used to differentiate between suppurative lymphadenitis, retropharyngeal edema and real abscesses.

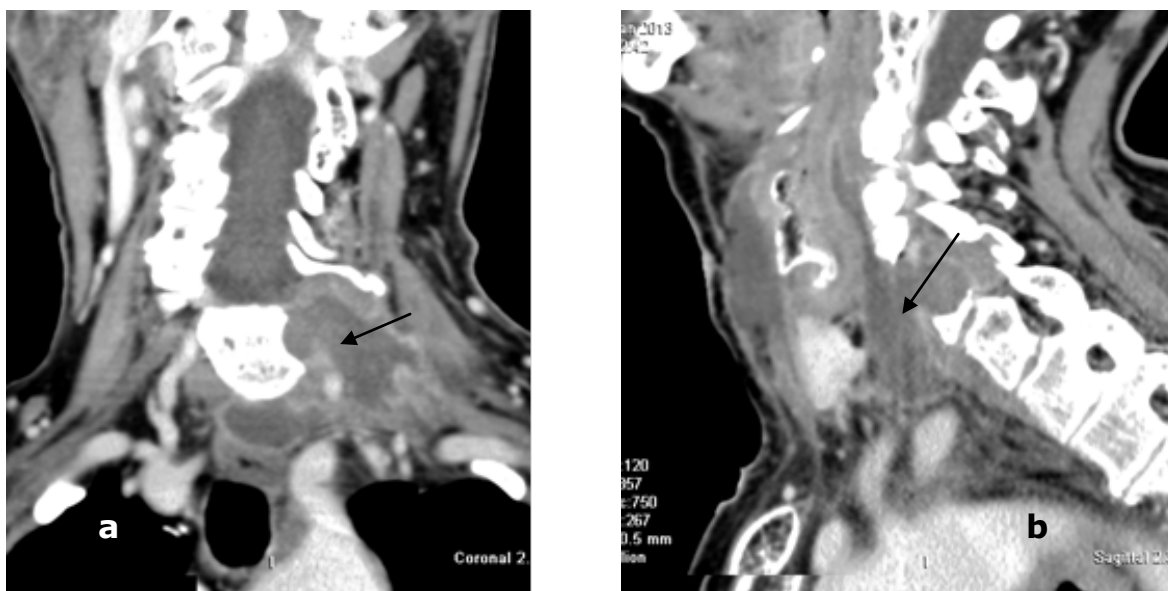
A retropharyngeal abscess presents as a hypodense fluid collection which expands this

space and shows a variable edge density increase. Imaging methods, especially CT, are useful in the monitoring of complications such as distal spread of the processes through the so-called "dangerous space" into the mediastinum, airway compromise, direct abscess spread into the epidural space, affecting the carotid space, causing a pseudoaneurysm of the internal carotid artery or jugular vein thrombosis (3, 5, 7).

#### Infections of the perivertebral space

These are the infections originating mostly from the spinal column, such as pyogenic or tuberculous discitis, vertebral osteomyelitis or epidural abscesses. On postcontrast CT tomograms, it presents as an irregular liquid accumulation with an edge postcontrast density increase (Figure 8). Considering the fact that CT is a rapid and readily available method, postcontrast MRI examination with fat suppression is the method of choice for the monitoring of pathology of this region.

Bacterial spondylodiscitis represents a bacterial suppurative infection of the vertebrae and the intervertebral disc occurring most frequently in the lumbar part of the spinal column. It can occur as the result of a direct pathogen inoculation during a surgical intervention, direct spread from the adjacent regions or via a hematogenous route. The most common microorganism causing the infections is *S. aureus*. The infection develops in the anterior part of the vertebral body, followed by spreading to the remaining parts. An infection of the disc space allows a spread of the process to the next vertebrae. On a MRI examination, the irregularity and destruction of end plates and narrowing of the disc space could be seen. The affected vertebra is seen as hypo (T1W) and hyperintense (T2W), with an intense postcontrast increase. The intervertebral disc is hyperintense in T2W with an intense edge signal increase. Paraspinal and epidural soft tissue masses can be observed as well (8).



**Figure 8.** Coronal(a) and sigittal (b) CT views, in the left paravertebral space an irregular liquid accumulation with an edge postcontrast density increase can be observed,the condition after a vertebrae operation

Epidural abscesses occur in persons in their sixth decade of life and predisposing factors include immunodeficiency, diabetes and cirrhosis. The most common cause is a *S. aureus* infection and it is localized in the lower thoracic segment and in the posterior epidural space. T1W and T2W MRI examinations reveal hypo and hyper signals, respectively, with two types of postcontrast signal intensity increases: homogenous, corresponding to the cellulitis (phlegmon) and peripheral, seen in an abscess with suppurative content.

Tuberculous spondylitis occurs via hematogenous dissemination, rarely per continuitatem, where the bacteria gather in the anterior parts of the vascularized bone marrow of the end plates. Thoracolumbar area is the one most commonly affected and the images where every other vertebra is affected could be seen. In the beginning, the anteroinferior part of the vertebral body is affected, but the infection can spread to the next vertebra, forming an abscess and vascular necrosis. A characteristic MRI image shows end plate irregularities and osteolysis of the vertebral bodies, which are hyperintense (T2W) with an intraosteal abscess edge postcontrast intensity increase. The gibbus deformity can develop, while the IV disc remains intact for a long time. Paraspinal abscesses are isointense, with the muscles on T1W images, and hyperintense with the altered signal of the paravertebral fatty tissue on T2W, while at the same time the ipsilateral psoas muscle is enlarged. Postcontrast images show an edge signal intensity increase (8,9).

### Infections of the visceral space

Epiglottitis is a life-threatening condition which

most commonly requires emergency intubation, especially in children. The etiology can be both bacterial and viral. The most common causal microorganism among children is *H. influenzae* and the infection is rapid and progressive, with a high risk for airway obstruction. On postcontrast CT imaging, an acute epiglottitis is seen as an enlarged, edematous epiglottis with a density increase of the mucosa. The entire supraglottis, the base of the tongue and tonsils can also be edematous, while the phlegmonous collections could be spotted in the surrounding soft tissues. The complications of this process can be in the form of necrotizing epiglottitis and epiglottic abscesses which can spread to the deep neck structures and mediastinum.

Pyolaryngoceles represent the internal (simple) or external (mixed) laryngoceles which are infected and contain pus. They are visualized as cystic structures surrounded with a thick wall which shows a postcontrast density/signal intensity increase.

### Conclusions

Head and neck infections are the conditions that can be associated with life-threatening complications. Based on their most common etiology, a clinical follow up and tracking of the disease signs and symptoms are necessary, especially the causal tooth infections.

The use of imaging methods, above all CT, is irreplaceable in a thorough patient evaluation, including a fast and accurate diagnosis, as well as for the estimation of disease extent, potential complications and further therapeutic treatment.

## References

1. Alotaibi N, Cloutier L, Khaldoun E, Bois E, Chirat M, Salvan D. Criteria for admission of odontogenic infections at high risk of deep neck space infection. *Eur Ann Otorhinolaryngol Head Neck Dis*. 2015; 132(5): 261-4. [[CrossRef](#)][[PubMed](#)]
2. Lyle N, Rutherford E, Batty V. A pain in the neck-imaging in neck sepsis. *Clin Radiol* 2011; 66(9): 876-85. [[CrossRef](#)][[PubMed](#)]
3. Capps E, Kinsella J, Gupta M, Bhatki A, Opatowski M. Emergency imaging assessment of acute, nontraumatic conditions of the head and neck. *Radiographics*. 2010; 30(5): 1335-52. [[CrossRef](#)][[PubMed](#)]
4. Prokop M, Galanski M, Van der Molen AJ, Schaefer-Prokop CM, Spiral and Multislice Computed Tomography of the Body. Stuttgart - New York: Thieme, 2003. [[CrossRef](#)]
5. Harnsberger HR, Wiggins RH, Huggins P. Diagnostic imaging Head and neck. Oral Cavity. Salt Lake City: Amirsys, 2004. [[CrossRef](#)]
6. Maroldi R, Farina D, Ravanelli M, Lombardi D, Nicolai P. Emergency imaging assessment of deep neck space infections. *Semin Ultrasound CT MR* 2012; 33(5): 432-42. [[CrossRef](#)][[PubMed](#)]
7. Harnsberger HR. Diagnostic imaging Head and neck. Oral Cavity. Salt Lake City: Amirsys, 2004.
8. Semnić R. Magnetna rezonanca kičme. Sremska Kamenica: Institut za Onkologiju, 2009.
9. Yousem DM, Grossman RI. *Neuroradiology: the requisites*, 3ed. Philadelphia: Mosby, 2010.

## ZNAČAJ KOMPJUTERIZOVANE TOMOGRAFIJE U DIJAGNOSTICI INFEKCIJA GLAVE I VRATA

*Sladana Petrović<sup>1,2</sup>, Aleksandra Milenković<sup>3</sup>, Milan Stojanović<sup>3</sup>, Maja Jocić<sup>1</sup>,  
Filip Petrović<sup>2</sup>, Dragan Stojanov<sup>1,2</sup>*

Centar za radiologiju, Klinički centar Niš, Srbija<sup>1</sup>  
Univerzitet u Nišu, Medicinski fakultet, Niš, Srbija<sup>2</sup>  
Univerzitet u Prištini, Medicinski fakultet sa trenutnim sedištem u Kosovskoj Mitrovici<sup>3</sup>

*Kontakt:* Sladana Petrović  
Medicinski fakultet u Nišu, Univerzitet u Nišu, Srbija  
Bul. Dr Zorana Đinđića 81, 18000 Niš  
E-mail: sladjana-petrovic@hotmail.com

Infekcije glave i vrata predstavljaju grupu oboljenja koja mogu biti udružena sa ozbiljnim komplikacijama i čiji je obim teško klinički proceniti. Iako je njihova učestalost znatno opala sa upotrebom modernih antibiotika i poboljšanjem oralne higijene, i dalje imaju visoku stopu morbiditeta i mortaliteta. Kompleksna anatomija i komunikacija između prostora ove regije potencira širenje procesa i može dovesti do životno ugrožavajućih stanja kao što su: opstrukcija disajnih puteva, empijem, medijastinitis, tromboflebitis, perikarditis, septički šok.

Upotreba kompjuterizovane tomografije (CT) kao metode izbora u urgentnim stanjima regije glave i vrata omogućava brzo donošenje tačne dijagnoze, procenu obima bolesti i potencijalnih komplikacija. *Acta Medica Medianae* 2017;56(2):70-77.

***Ključne reči:*** infekcije glave i vrata, komplikacije, CT