

Case report

UDC:616.12-005.4-008.311:616.8-009.832
doi: 10.5633/amm.2017.0206**SYNCOPE CAUSED BY VENTRICULAR TACHYCARDIA AS A
CONSEQUENCE MYOCARDIAL ISCHEMIA – THE CASE REPORT**Saša Ignjatijević¹, Miomir Randjelović²

Syncope, one of the forms of loss of consciousness, occurs because of the general hypoperfusion of the cerebral cortex caused by reduced arterial pressure. Cardiogenic syncopes occur due to structural heart changes or dysrhythmia.

An elderly man experienced syncope in the street. Due to a previous loss of consciousness he was wearing a holter. Medical emergency team found him conscious with normal ECG and vital parameters.

After observation at the Emergency Centre he was referred to a cardiologist with normal physical examination results and without any complaints. Cardiologist admitted him to hospital because of the ECG changes.

Coronography performed next day showed a significant stricture in the branches of the left coronary artery and four stents were placed. Holter monitoring after the stent placement did not show any rhythm disorders. Holter monitoring that patient was wearing at the moment of his loss of consciousness, showed episodes of ventricular tachycardia preceded by myocardial ischemia. After revascularization, patient was referred to the Institute for Treatment and Rehabilitation „Niška Banja“.

Timely diagnosis and adequate therapy for syncope of cardiogenic origin could prevent severe consequences, the most serious of which is sudden death. *Acta Medica Medianae* 2017;56(2) :38-44.

Key words: Syncope, Myocardial Ischemia, Tachycardia, Ventricular

Emergency Medical Centre, Niš, Serbia¹
Cardiology Clinic, Clinical Centre Niš, Serbia²

Contact: Saša Ignjatijević
Emergency Medical Center, Niš
Vojislava Ilića b.b., 18000 Niš, Serbia
E-mail: siscrat@gmail.com

Introduction

Consciousness of a person shows that the person is conscious of themselves and their surroundings and that he/she responds to stimuli from the outside world. According to this, the consciousness of a person can be said to be determined by two aspects of consciousness: qualitative awareness or psychic life at a certain moment and quantitative awareness or vigilance (1).

Awareness is usually considered as the state of vigilance in everyday work. Therefore, when a disorder of the consciousness is discussed, it is usually mistaken with vigilance disorder if it is not particularly emphasized. These disorders can be of different degrees and they vary from short losses of consciousness to the state of coma, as the most difficult form.

The loss of consciousness is defined as a transient loss of consciousness, which occurs suddenly and lasts short and after which the patient spontaneously recovers. It is usually followed by a fall due

to the loss of muscular tonus and with various movements of the motoric system. Revulsive and sudden occurrence of these disorders demands a fast and adequate medical treatment. Therefore, it is important to make a distinction between diagnostic and therapeutic treatment of the real loss of consciousness from other disorders in which the loss of consciousness can be illusion and also followed by motoric demonstration (2).

When the loss of consciousness is confirmed, then it is necessary to make a distinction if it is the consequence of traumatic or non-traumatic event. After the exclusion of trauma as the cause, it is necessary to confirm if the loss of consciousness is connected to syncope, epilepsy, psychogenic pseudosyncope or to the rare forms of various causes (3).

The most frequent forms of a real transient loss of consciousness are syncope and epilepsy. Syncope is defined as a transient global cerebral state of hypoperfusion, characterized by a rapid onset, short duration and complete spontaneous recovery. It usually turns up without any prodromal events, although in some of its forms (reflexive-neural mediated) there is a preceding prodromal period. Its duration is usually short up to 20 seconds when reflexive syncope is concerned. Other forms of syncope can last even longer, up to a couple of minutes (4).

In the base of syncope there is a diffusion hypoperfusion of the cerebral structures responsible for vigilance due to reduced cerebral blood supply caused by a systemic blood pressure drop. The systemic blood pressure drop is caused by the reduced heart minute volume and/or total peripheral vascular resistance. The cerebral blood perfusion drop occurs during the systolic blood pressure drop below 60 mm Hg or when the cerebral supply is reduced for longer than 6-10 seconds.

According to the causes that can initiate systemic blood pressure drop, syncopes can be divided into the following groups (3):

A) Reflexive (neurally-mediated) syncope refers to various groups of conditions in which cardiovascular reflex, which is used to control cardiovascular system responses to different stimuli, reacts inadequately, leading to vasodilatation and/or bradycardia, arterial blood pressure drop and diffusional cerebral perfusion (5).

B) Syncope caused by orthostatic hypotension occurs due to the impossibility of autonomic nervous system to maintain the necessary values of blood pressure in the upright position the blood is retained in the venous bed of the lower extremities. This leads to a reduction of venous blood return, reduced minute volume, and to cerebral hypoperfusion (6).

C) Cardiogenic

The cause of cardiogenic syncope can be rhythm disorders or structural cardiac diseases.

Arrhythmias are the most frequent cause

of syncope. The deviation in the correct heart rhythm caused by arrhythmias lead to the reduced minute volume of the heart and consequently reduces cerebral perfusions. The cause can be either bradycardia or tachycardia. Synoatrial block and ventricular tachycardia can initiate the minute volume drop and consequently lead to syncope (7). Atrioventricular blocks (Mobitz II and complete atrioventricular block) belong to the group of more frequent causes of cardiac syncope.

Structural heart damage is the cause of syncope in the situations when the damaged heart has got reduced functional abilities and thus can not increase its minute volume demanded by an increased circulation.

Early diagnosis of syncope of cardiogenic origin is relevant because it can be the symptom of sudden cardiac death. People who have syncope of this type belong to the group of patients at high risk for early death of cardiovascular origin (8).

The purpose of this study is to point out how significant it is to recognize and consider syncope apart from other losses of consciousness and to stress correct diagnosis and treatment of the disorders leading to its onset.

That is important because the syncopes of cardiologic origin are particularly risky since they originate from rhythm disorders or structural heart diseases, and if neglected or failed to recognize can consequently lead to a stream of unwanted events and even to a sudden cardiac death.

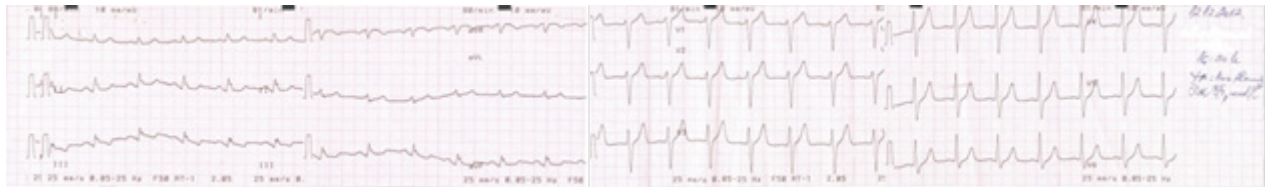

Figure 1. ECG in the field

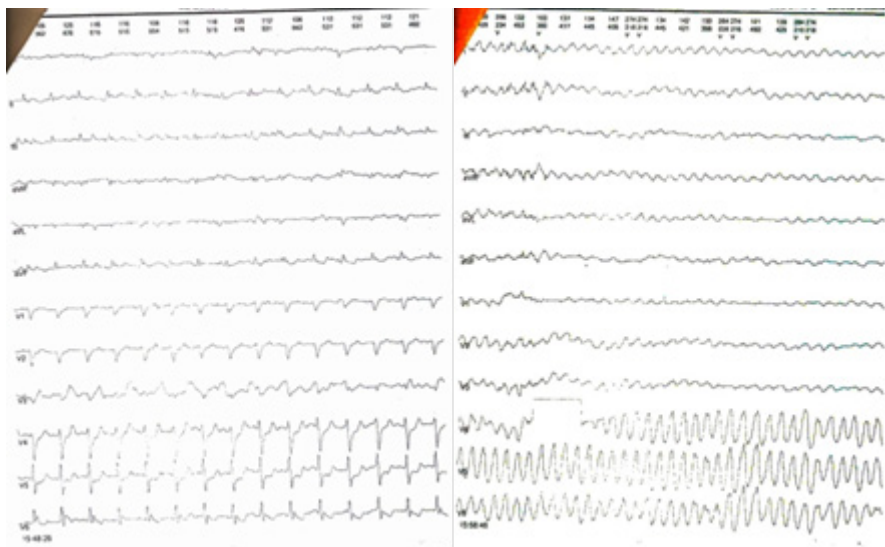


Figure 2. Holterchart before the loss of consciousness

Case description

A 59-year-old man experienced a short loss of consciousness day before in the street at 4 pm. Emergency team found him conscious. He felt irregular heart rhythm and dizziness before that. The loss of consciousness was not followed by extremity twitching or mouth foam, according to the witnesses' statements. On examination the doctor confirms normal vital parameters and negative T wave in D3 on his ECG (Figure 1). He is

taken to the observation unit of the Emergency Medical Centre in Niš. Patient gives the information that he has had another loss of consciousness, when he was checked by a neurologist and cardiologist who recommended him to do heart holter monitoring too. For this reason, patient had an ECG holter with him at the moment of the loss of consciousness. The ECG holter was examined after the hospital release and it showed episode of ventricular tachycardia which were preceded by ischemia (Figure 2).

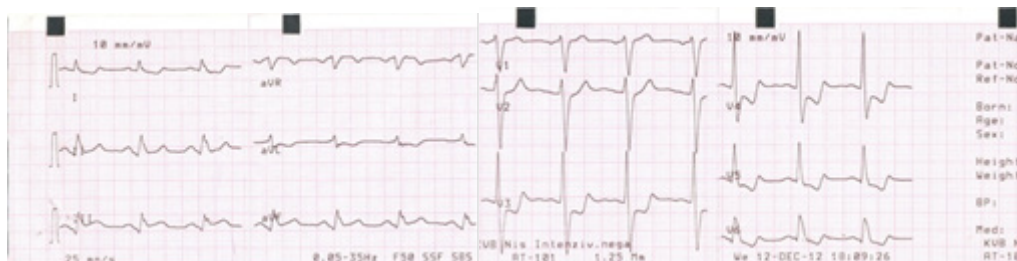

Figure 3. ECG in emergency ward

The report shows that in the period, when the patient had prodromal symptoms and eventually loss of consciousness, the depression of ST segment was at its highest at 4 pm. From the observation unit he was referred to a cardiologist with normal vital parameters and ECG which did not show any changes in relation to the previous one and without any subjective complaints.

In the admission ward of Cardiology Clinic patient does not have any subjective complaints, but there are changes on his ECG (ST segment elevation in D2, D3 and AVf leads with the depression of ST segment in V3 – V6), and patient is admitted (Figure 3). The next day, the additional diagnosis is done. Echocardiography shows dilated and globulized ventricles, hyper trophically

changed, with the ejection fraction of 43%. Inferoposterior walls, anterior septum and anterior wall in the lower two thirds are akinetic. Laboratory analysis is normal, except for an increased cholesterol level (5,61 mmol/L) and creatine kinase (215 mmol/L). The values of troponin are also normal. According to the anamnestic information, it is obvious that the patient takes ischemic therapy (Preductal MR, Mollicor, Isosorb R, Nebilet, Cardyopirin 100), because two years before the actual event he had undergone coronography, which showed a 50% stenosis of the anterior descending artery and 90% of the left circumflex artery. Neurosclerosis of the right kidney was diagnosed 6 years ago. Risk factors: a smoker and increased level of cholesterol.

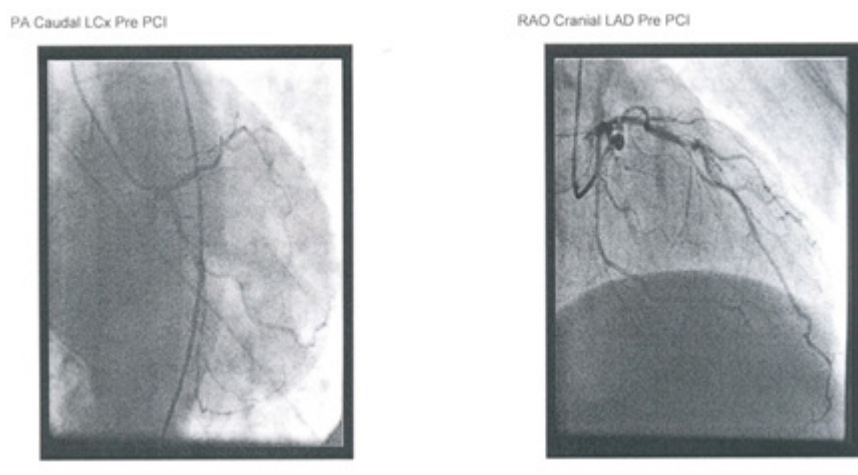


Figure 4. Branches of the left coronary artery before intervention

Coronography was done the next day and it showed stenosis of 99% at the proximal segment of the left circumflex artery and 70% at the anterior descending on the longer medial segment (Figure 4). The main stem of the left coronary is without

changes as well as the right coronary which is the dominant one. Three stents were placed in the stenosed part of circumflex artery and one in the anterior descending (Figure 5). The whole intervention procedure was without any complications

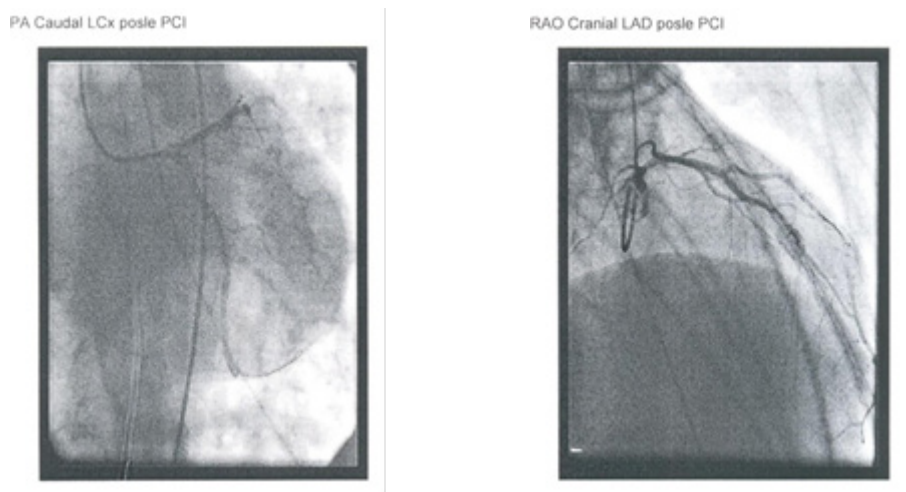


Figure 5. Branches of the left coronary artery after intervention

The period after intervention passed without any complications and exacerbations. Before the hospital discharge, holter monitoring was done again and it did not show any relevant ST segment and T wave changes, nor any significant heart rhythm disorders. After the clinical treatment, the patient continues with rehabilitation in Institute Radon in NiškaBanja.

Discussion

The loss of consciousness is a frequent reason to see a doctor. Syncope, as one of the most frequent forms of loss of consciousness, belongs to the group of ten most frequent diagnoses at discharge from the emergency centres in America (9). Information about going to emergency departments of clinics is approximately 1% (10). The facts from the Framingham study indicate that the incidence of the first episode of syncope in general population is 6,2/1000 inhabitants. It is also necessary to point out that only 56% of patients with syncope symptoms ask for medical help. Incidence increases with aging, so after the age of 70 the number of patients is higher (11,1 /1000) than it is in the age of 50 -59 when the incidence is 5,5 /1000. There is no significant difference in incidence between sexes (8). There are no precise facts for Serbia, but it is considered that the combination of these facts with the information from our medical system (the number of the first visits to a doctor and the number of GP doctors) can lead to the conclusion that at least one patient with these symptoms asks his GP for help at least once a month and that indicates the frequency and growth of this health problem in our country (1).

Syncope can have a large number of causes, but the most important are those based on cardiac diseases. Although the percentage prevalence of syncope causes varies depending on the type of examinees and the age, it can be generally said that syncope of cardiologic origin is in the second place, although there are higher values of percentage according to information received from elderly patients in emergency departments as well as from cardiology clinics(3).

The significance of timely recognition of symptoms of this type of syncope lies in the fact that they carry the risk of high mortality level and low survival rates due to the underlying diseases which contribute to their manifestation (3). The right diagnosis can be made with difficulties for different reasons: the persons who ask for help for these complaints are usually asymptomatic during the examination and most frequently they can not give any details about the event they sought medical help for (particularly the elderly) (9). The studies by Soteriades and the associate showed that persons with cardiac syncope have twice as high a risk of death compared to those without syncope and their chance to survive is lower compared to the group without syncope (8).

That is why detailed facts about the event and about the previous diseases can lead to a real cause of the loss of consciousness. Sudden occurrence, palpitation feeling, prior cardiac diseases, lack of precipitating factors (warm rooms, long lying in bed, fear of pain) or lack of autonomous prodromes (nausea or vomiting) are the facts that indicate cardiogenic origin of the syncope. These parameters are involved in the EGSYS score, one of numerous score lists to assess the seriousness of syncope (11). The person from the case description had three out of five previously mentioned factors, so the assumption of the cardiac origin of syncope was correctly made. For this reason the demand for ECG holter was approved since the coronography details showed a stricture of the coronary blood vessels, as well as the palpitation feeling before the loss of consciousness, which indicated the presence of arrhythmia before the loss of consciousness. It was confirmed by the additional ECG holter score which was carried by the patient during the loss of consciousness. This fact confirms the attitude that the gold standard in the diagnosis of syncope is the connection of symptoms and confirmed arrhythmia (3).

The facts revealed by echocardiography showed that the myocardium of this patient was hypertrophically changed and that there was

akinesia of inferoposterior and anterior wall as the consequence of some necrosis of the myocardium due to probable earlier myocardial infarction with spontaneous reperfusion and residual stenosis of 99% in the circumflex artery. Although this examination was done at the clinic, as part of a cardiac patient diagnosis, the results suggest ischaemic cardiomyopathy, which can be the cause of syncope when followed by rhythm disorders. This statement confirms that echocardiography is the key method to confirm the existence of structural cardiac diseases, and this method is used to obtain the facts about structural and functional hemodynamic cardiac condition. It is also used to get the facts about ejection fraction of the left chamber which is also relevant for the assessment of existing risk of the patient to experience adverse cardiovascular effects and sudden cardiac death (12).

Coronography showed subocclusion of circumflex artery as well as significant stenosis of the frontal descendens, so with confirmation of ischemia causes noted on the holter, the dilemma about therapeutic treatment of these changes was solved. As previously mentioned, placing the stents on the stricture spots solved the cause of ischemia therapeutically and probably the cause of onset of ventricular arrhythmia.

Therapeutic procedures, when the syncope cause is determined, have a goal to increase survival rates, to reduce injuries and to prevent new episodes. Which of these goals is more important depends on the syncope cause. The goal of therapeutic procedures in the treatment of structural cardiac diseases as the cause of syncope is not only to prevent repeated syncope episodes, but also to heal them. In case of syncope caused

by ventricular tachycardias, it is necessary to achieve the reduction of sudden cardiac death rate, that is the most significant consequence of ventricular tachycardia episodes (13). According to the holter readings carried at the moment of syncope, it was obvious that sustained ventricular tachycardia was present and that it lasted for more than 30 seconds. If shorter than 39 seconds, it is called non-sustained VT. Sustained VT manifests as monomorphic and polymorphic, which can be of great significance because the first one can be formed on the myocardial cicatrix and it can also require a more aggressive strategy of relapse prevention, while the other one may tell about the progression of ischemia and also require additional reperfusion measures, as it was done in the described case (14). In some cases, although there is not a clear structural cardiac disease, it can not be regarded as the only one responsible for the onset of syncope. With a myocardial infarction of the lower wall, a reflex syncope may occur, because in this case infarction causes and strengthens the reflex mechanism (3).

With the syncope connected to myocardial ischemia, the appropriate therapeutical choice is revascularization, as it was done in this case (3).

Conclusion

Ischaemia of the myocardium and consequential rhythm disorders can be the cause of syncope as well as sudden cardiac death. A timely diagnosis and appropriate therapeutic intervention can prevent serious consequences to set in, among which the most serious is sudden cardiac death.

References

1. Radna grupa za izradu vodiča, rukovodilac Dragoslav Sokić. Gubitak svesti: Nacionalni vodič za lekare u primarnoj zdravstvenoj zaštiti. Beograd: Srpsko lekarsko društvo; 2005.
2. Smith PEM. If It's not epilepsy. *J. Neurol. Neurosurg. Psychiatry* 2001; 70(2): 9-14. [[CrossRef](#)] [[PubMed](#)]
3. Moya A, Sutton R, Ammirati F, Blanc JJ, Brignole M, Dahm JB, et al. Guidelines for the diagnosis and management of syncope (version 2009): the Task Force for the Diagnosis and Management of Syncope of the European Society of Cardiology (ESC). *Eur. Heart J.* 2009; 30(21): 2631-71. [[CrossRef](#)] [[PubMed](#)]
4. Hoefnagels WA, Padberg GW, Overweg J, van der Velde EA, Roos RA. Transient loss of consciousness: the value of the history for distinguishing seizure from syncope. *J. Neurol.* 1991; 238(1): 39-43. [[CrossRef](#)] [[PubMed](#)]
5. Alboni P, Alboni M, Bertorelle G. The origin of vasovagal syncope: to protect the heart or to escape predation? *Clin. Auton. Res.* 2008; 18(4): 170-8. [[CrossRef](#)] [[PubMed](#)]
6. Frishman WH, Azer V, Sica D. Drug treatment of orthostatic hypotension and vasovagal syncope. *Heart Dis.* 2003; 5(1): 49-64. [[CrossRef](#)] [[PubMed](#)]
7. Wieling W, Thijs RD, van Dijk N, Wilde AA, Benditt DG, van Dijk JG. Symptoms and signs of syncope: a review of the link between physiology and clinical clues. *Brain* 2009; 132(Pt10): 2630-42. [[CrossRef](#)] [[PubMed](#)]
8. Soteriades ES, Evans JC, Larson MG, Chen MH, Chen L, Benjamin EJ, et al. Incidence and prognosis of syncope. *N. Engl. J. Med.* 2002; 347(12): 878-85. [[CrossRef](#)] [[PubMed](#)]
9. Akdemir B, Krishnan B, Senturk T, Benditt GD. Syncope: Assessment of risk and an approach to evaluation in the emergency department and urgent care clinic. *Indian Pacing Electro physiol. J.* 2015;15(2):103-9 [[CrossRef](#)] [[PubMed](#)]
10. Blanc JJ, L'Her C, Touiza A, Garo B, L'Her E, Mansourati J. Prospective evaluation and outcome of patients admitted for syncope over a 1 year period. *Eur. Heart J.* 2002;23(10):815-20 [[CrossRef](#)] [[PubMed](#)]
11. Del Rosso A, Ungar A, Maggi R, Giada F, Petix NR, De Santo T, et al. Clinical predictors of cardiac syncope at initial evaluation in patients referred urgently to a general hospital: the EGSYS score. *Heart* 2008; 94(12): 1620-6. [[CrossRef](#)] [[PubMed](#)]
12. Prastaro M, D'Amore C, Paolillo S, Losi M, Marciano C, Perrino C, et al. Prognostic role of transthoracic echocardiography in patients affected by heart failure and reduced ejection fraction. *Heart Fail Rev.* 2015; 20(3): 305-16 [[CrossRef](#)] [[PubMed](#)]
13. Priori SG, Blomström-Lundqvist C, Mazzanti A, Blom N, Borggrefe M, Camm J, et al. 2015 ESC Guidelines for the management of patients with ventricular arrhythmias and prevention of sudden cardiac death: The Task Force for the Management of Patients with Ventricular Arrhythmias and the Prevention of Sudden Cardiac Death of the European Society of Cardiology (ESC). Endorsed by: Association for European Paediatric and Congenital Cardiology (AEPC). *Eur Heart J.* 2015; 36(41): 2793-867 [[CrossRef](#)] [[PubMed](#)]
14. Wolfe CL, Nibley C, Bhandari A, Chatterjee K, Scheinman M. Polymorphous ventricular tachycardia associated with acute myocardial infarction. *Circulation* 1991; 84(4): 1543-51 [[CrossRef](#)] [[PubMed](#)]

Prikaz bolesnika

UDC:616.12-005.4-008.311:616.8-009.832
doi: 10.5633/amm.2017.0206**SINKOPA IZAZVANA VENTRIKULARNOM TAHIKARDIJOM KAO
POSLEDICA ISHEMIJE MIOKARDA – PRIKAZ SLUČAJA***Saša Ignjatijević¹, Miomir Randjelović²*Centar urgentne medicine, Niš, Srbija¹
Klinika za kardiologiju, Klinički centar Niš, Srbija²Kontakt: Saša Ignjatijević
Centar urgentne medicine, Niš, Srbija
Vojislava Ilića b.b., 18000 Niš, Srbija
E-mail: sisocrat@gmail.com

Sinkopa, jedan od oblika gubitka svesti, nastaje zbog opšte hipoperfuzije moždane kore izazvane smanjenim arterijskim pritiskom. Kardiogene sinkope nastaju zbog strukturnih promena na srcu ili disritmija.

Stariji muškarac je na ulici doživeo sinkopu. U tom trenutku je nosio holter, zbog prethodnog gubitka svesti. Hitna pomoć ga zatiče svesnog, sa normalnim EKG-om i vitalnim parametrima. Nakon opservacije u Hitnoj pomoći, upućen je kardiologu, sa normalnim fizikalnim nalazom i bez tegoba, koji ga hospitalizuje zbog promena na EKG-u.

Sutradan, urađena koronarografija pokazuje značajna suženja na granama leve koronarne arterije i postavljena su četiri stenta. Holter rađen nakon implantacije stentova je bez poremećaja ritma. Holter nošen u trenutku gubitka svesti pokazuje epizode ventrikularnih tahikardija, kojima prethodi ishemija miokarda. Nakon revaskularizacije, bolesnik je upućen u Institut za lečenje i rehabilitaciju „Niška Banja“.

Pravovremenom dijagnostikom i odgovarajućom terapijskom intervencijom zbog sinkopa kardiogenog porekla mogu se sprečiti neželjene teške posledice, od kojih je najopasnija iznenadna srčana smrt. *Acta Medica Medianae* 2017;56(2):38-44.

Ključne reči: : sinkopa, ishemija miokarda, tahikardija, ventrikular

This work is licensed under a Creative Commons Attribution 4.0 International (CC BY 4.0) Licence