



## Case report

ACTA FAC. MED. NAISS. 2004; 21 (4): 37-41

Miloš Jovanović<sup>1</sup>,  
Dragan Veselinović<sup>2</sup>

<sup>1</sup>Institute of Eye Diseases  
"Prof. dr Đorđe Nešić", Clinical  
Center of Serbia, Belgrade  
<sup>2</sup>Clinic for Eye Diseases, Niš

## SURGICAL TREATMENT OF POSTCONTUSION ORBITAL LATE PHASE HEMATOMA: A CASE REPORT

## SUMMARY

The object of the study was to present a successfully performed decompression of the orbit in orbital hematoma. Male, 51 years of age, sustained the contusion injury of the right eye during his fall on the bath tap. It caused the development of a large orbital hematoma with protrusion, restricted movement of the eyeball, pain, diplopia, folding of the retina due to hematoma pressuring the bulbus oculi and retinal hemorrhages, higher intraocular pressure and impaired visual acuity to 2/60. He was medicamentously treated for a month, but the results were not satisfactory and one month after the injury, anterior-inferior transcutaneous orbitotomy was performed. During the surgical intervention, hematoma and a part of orbital fat tissue were removed. The globe of the eye was retracted and the exophthalmus disappeared immediately after the surgery, while the mobility of the eye ball, disappearance of retinal folds with gradual receding of hemorrhage, normal intraocular pressure, abatement of pain and diplopia as well as the restoration of visual acuity to normal ensued in a few subsequent days. This study illustrated that decompression of the orbit in orbital hematoma might be successful even in the late phase, e.g., one month following the injury. It is assumed that surgical intervention would be performed by an experienced orbital surgeon.

*Key words:* orbital contusion, orbital hematoma, decompression of the orbit

## INTRODUCTION

Orbital hemorrhage may develop spontaneously, during some surgical intervention to the orbit or its adjacent structures, as well as in orbital injuries.

Spontaneous bleeding usually occurs in the increased intracranial venous pressure or in various cases of hemorrhagic diathesis (1, 2). It develops in all age groups, from the newborns to the oldest persons.

Surgery of the orbit represents the specific risk for hemorrhage development. The possibility of bleeding is present even during retrobulbar or parabolbar anesthesia, when some major blood vessel of the orbit may be injured. Such bleeding is more frequent in this type of local anesthesia before the expected operation of cataract. The hemorrhage may be so massive to force us to postpone the surgery for some time, and the cases of blindness after such orbital hemorrhage have been reported (3–5). Severe bleeding in the orbit or its adjacent structures

may also occur in the immediate post-operative period. These hazardous surgical interventions resulting in severe hemorrhage are different types of orbitotomy and decompression of the orbit, rhinoplasty, operation of sinuses and dacryocystorhinostomy (2,6,7).

Special risk to the eye is the bleeding within the orbit caused by injuries. The injuries may be inflicted by sharp objects – open wounds (8,9) or blunt objects – contused wound (10–11). Specific contusion injuries of the orbit and its adjacent structures may lead to orbital wall fractures.

Orbital bleeding may be localized in subperiosteal, parabolbar and retrobulbar space of muscle cone.

Clinical symptoms and signs are numerous. Patients complain of sudden pain deep in the eye and diplopia. The increase of orbital tension and sudden rise of intraocular pressure are evident. Objective findings are proptosis, restricted mobility of the eyeball and its complete stiffness. Ophthalmoscopy of the ocular fundus may reveal retinal folds as the result of compression. The most severe cases of contusion injuries may result in the avulsion of the eye ball and rupture of striped muscles at their scleral insertion, so the eyeball is protruded without any possibility of closing the lid (5).

The procedure of treatment in orbital hemorrhage varies according to the profusion of bleeding, the degree of anatomic impairment of the eyeball and the respective visual function. In moderate cases, with manifested proptosis, limited mobility of the eyeball and higher intraocular pressure, conservative treatment yields good results. Antiglaucoma drugs, systemic corticosteroids, and osmotherapy are administered to diminish the edema, to accelerate the resorption, decrease the swelling and reduce the intraocular pressure, respectively. If it is necessary to protect the exposed cornea, a wet chamber is inserted. In these cases, the massage of the eyeball several times a day is also beneficial (5). In case that all these procedures are not sufficient, and the proptosis is immense, highly threatening the vision due to optic nerve compression, surgical decompression of the orbit is carried out (9–11). Initially, external canthotomy followed by decompression with either anterior orbitotomy or upper panoramic orbitotomy are performed (5,6). After extraction of blood collection or clot, the eyeball is drawn back and temporary tarsorrhaphy is placed. In this way, backward compression of the eyeball is achieved and repeated bleeding is prevented. Tarsorrhaphy is usually left in place two to three weeks.

## CASE REPORT

The patient was 51 years old male. Ten years ago, he underwent heart surgery and since that time, he has been administered an anticoagulant, Sintrom, in a dose of 4 mg/day. For the first time he was presented to the Institute of Eye Diseases, Clinical Center of Serbia, on October 30, 2001, due to the injury of the right eye. He sustained the injury 24 days earlier when he slipped in his bath, striking the region of the right eye against the shower tap. It was the question of contused wound of the right eye. Until his presentation at the Institute of Eye Diseases, he was treated conservatively in another medical institution, but the condition did not improve; on the contrary, it was increasingly worse with evident impairment of the sight.

While moving the eyeball in different directions, the patient complained of pain in the eye and constant exhausting diplopia. Objective findings revealed hematoma of lids in remission, protrusion of the eyeball and exophthalmometry value of 24 mm in comparison with 17 mm measured in the left eye. There was also restricted mobility of the eyeball in all directions, and especially while looking downward or to the right (figure 1). Refracting media were transparent, and retinal bleeding with marked retinal folds were apparent in the ocular fundus (figure 2). Visual acuity of the eye was 2/60, and intraocular pressure reached 28 mmHg.

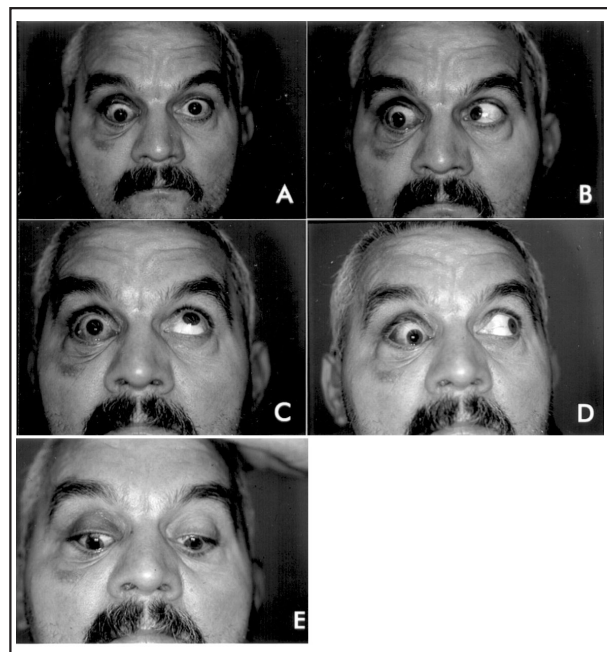


Figure 1. The picture was taken 30 days after the injury, and one day prior to surgery. The eyeball protrusion of 24 mm could be noted best in primary view direction (A). The mobility of the right eyeball was slow at all diagnostic views, to the right (B), upward (C), to the left (D), and to somewhat lesser degree downwards (E). Hematoma in remission in the region of lower lid was visible.

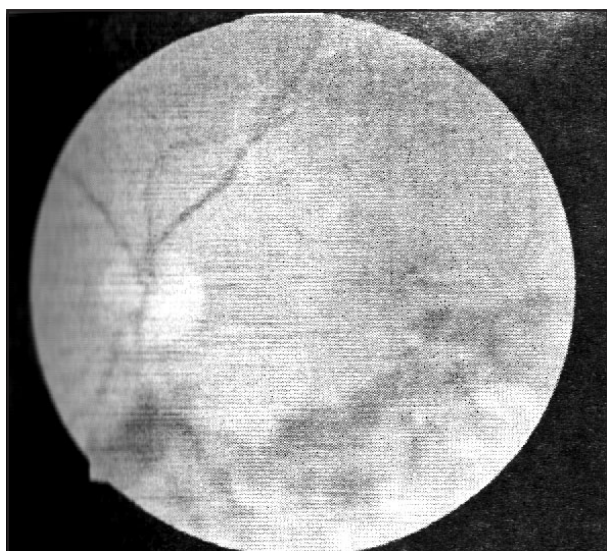

Figure 2. The picture of ocular fundus was taken 30 days after the injury. Retinal bleeding and folds were distinct, extending from papilla to temporal region and downwards. They even reached the macular region. The limits of hemorrhage were indefinite, but in bright red color.

In addition to a thorough ophthalmologic examination, some other diagnostic tests were performed. X-ray finding of the right orbit was normal, without any damage to bone structures of the walls. CT scanning of the right orbit showed modified soft tissue intensity laterally and posterior to the eyeball, not alike fresh blood by its density, but which might be analogous to density of hematoma in its advanced phase. Such a change pushed the eyeball forward so it was protruded, the right striped muscle could not be differentiated, and the optic nerve was markedly compressed and pushed towards the nose (figure 3).

## RESULTS

Based on the history, symptoms, clinical picture and clinical examination, as well as the additional tests, the conclusion was drawn that orbital hemorrhage resulting from contusion injury was present. The bleeding was localized in the para- and retrobulbar regions. Since a full month passed from the injury, it was concluded that hematoma was in the organization phase.

Compromised visual acuity, exophthalmus, limited bulbar mobility, retinal folds and hemorrhage suggested that medicamentous therapy would not yield favorable results, therefore, we opted for surgical intervention, e.g. orbital decompression. Surgery was performed in general endotracheal anesthesia. Antero-inferior transcutaneous orbitotomy was carried out. The orbit was approached via its lower border in the inferior-temporal region. Blood clot, which was in the initial phase of organization, was removed by aspirator and instruments, and a

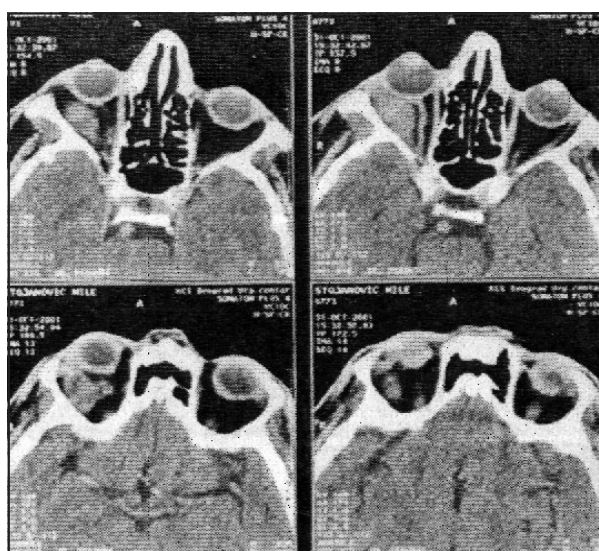


Figure 3. CT scanning was performed 30 days after the injury and one day before the surgery. The shadow of hematoma in the advanced phase was seen in the right orbit. Hematoma was localized in temporal region, near to the eyeball and behind the bulbus oculi. It was evident that such a mass caused the eyeball protrusion and concurrently pushed the optic nerve towards nasal region. The external striped muscle could not be differentiated, but it was immersed in hematoma. Bone structures of the orbit remained intact.

smaller part of orbital fat tissue was extracted in the same procedure. During the immediate surgery, higher backward compressibility of the eyeball was evident.

The postoperative course was uneventful and the recovery went well. There was no repeated bleeding and the patient was discharged on day six from the operation. The results of surgery were apparent after three months from the intervention. No eyeball protrusion or lid retraction could be noted. Bulbar mobility was improved in all directions but at forced upward view, when diplopia occurred (figure 4). There was no diplopia in primary view direction and at all other diagnostic views. Refracting media remained transparent, while hemorrhage and retinal folding disappeared in the ocular fundus (figure 5). The control CT scanning of the orbit revealed that both eyeballs were in normal position and there was no compression on the right optic nerve. The external striped muscle of the right orbit was markedly thickened (figure 6). The important issue was that the visual function of this eye was improved, namely, it was within normal limits.

## DISCUSSION

This case report suggests the gravity of the eye injury during slipping and fall in the bath. These injuries occur by striking the region of the eye against the shower and they are not so rare. They may be considerably more severe if the eyeball is ruptured, and in the event of semi-evisceration.

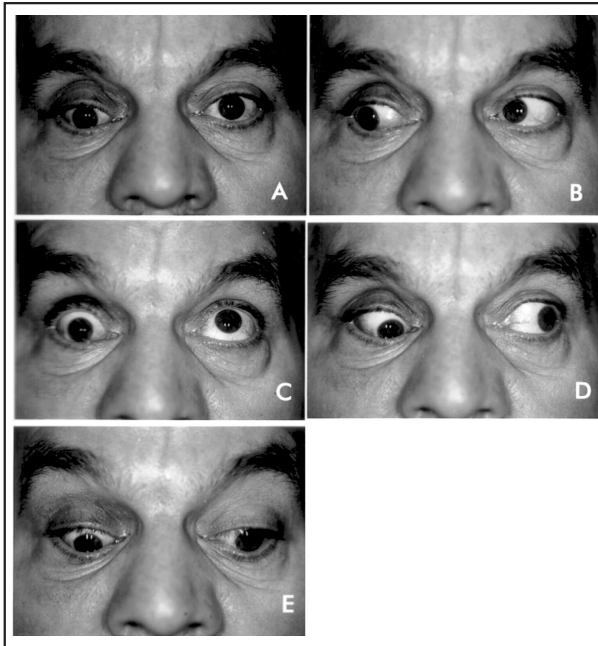


Figure 4. The picture was taken 3 months following the surgery, e.g. decompression of the orbit. There was no protrusion of the eyeball in primary view direction (A). The right eyeball restored mobility in diagnostic views directions, at the view to the right (B), to the left (D), and downwards (E), while there was slow and slightly restricted mobility while looking upward (C).

This injury was specific because the contused wound caused large retrobulbar and parabolbar hematoma, which did not recede even after a month from the injury, yet its organization was in the initial phase. The applied medicamentous treatment did not yield satisfactory results. All signs related to massive orbital bleeding were manifest: protrusion, restricted mobility of the eyeball associated with diplopia, pain, retinal folds due to compression on the globe, higher intraocular pressure and impaired visual acuity. Massive orbital hemorrhage was best shown by CT scanning of the orbit.

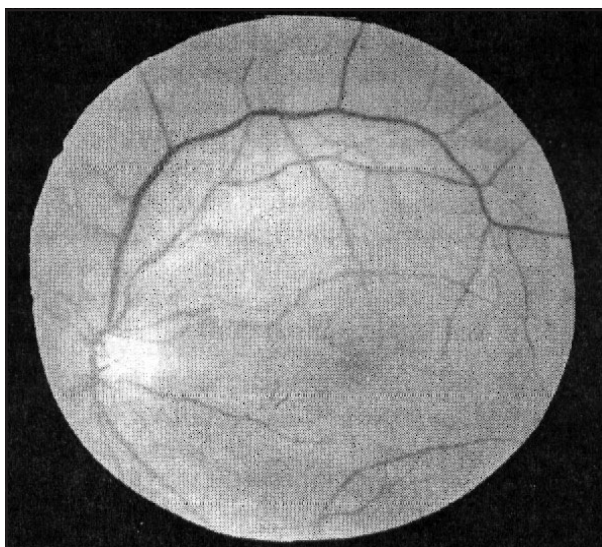


Figure 5. The picture of the ocular fundus was taken 6 months after the injury. Retinal folds and hemorrhage disappeared and the findings were normal.

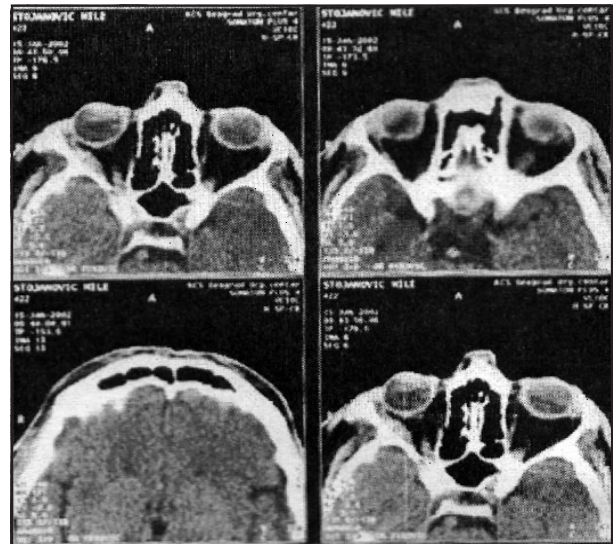


Figure 6. CT scanning of the orbit was performed 3 months following the surgery. The right eyeball was in normal position without any protrusion. No shadow of hematoma and no compression on the optic nerve could be noted. Only partially thickened external striped muscle was evident. Bone structures of the orbit remained intact.

All these symptoms, and particularly the signs such as retinal folds, compression of the optic nerve and its pushing back towards the nose as well as the impaired visual acuity, compelled us to decide on the decompression of the orbit. CT scan and the location of hematoma made us opt for the inferior temporal approach in orbitotomy. The surgery proceeded without any complications, and the most important fact was that there was no repeated hemorrhage, although we inserted the vacuum drain as a precaution. Still, during the surgery, the striped muscle was noted to be thickened, what was subsequently verified by CT scanning (figure 6). It was most probably infiltrated with blood and its function was impaired.

The results were apparent immediately following the surgery, and they became more evident in the following weeks and months after the intervention. The eyeball was drawn back to its normal position and there was no protrusion, the mobility of the eyeball was restored, while diplopia and retinal folds disappeared. The most significant outcome was the restitution of visual function, thus, the visual acuity was restored to normal. It was intriguing that, although the optic nerve was compressed for 30 days, there was no atrophy of nerve fibers, what was confirmed by regular color of optic nerve papilla. This enabled the restoration of normal visual acuity.

This study described that orbital decompression carried out one month after the development of orbital hematoma might yield excellent results. Such possibility should be always considered, whenever earlier procedures of conservative treatment have failed.

## CONCLUSION

This study suggests that decompression of the orbit in large orbital hematomas may be utilized even in the late phase and may yield satisfactory re-

sults. It brings about the restoration of normal anatomic relations, and motor and sensory skills of the eye. It implies that orbital decompression should be performed by qualified and experienced orbital surgeon who is well acquainted with orbital anatomy.

## REFERENCES

1. Atalla MR, McNab AA, Sullivan TJ, Sloan B: Nontraumatic subperiosteal orbital hemorrhage. *Ophthalmology* 2001;108:183–9.
2. Hunt KE, Ross JJ. Orbital hemorrhage in the nonoperated eye as a complication of general endotracheal anesthesia. *Arch Ophthalmol* 1998; 116:105–6.
3. Girard LJ. Subperiosteal orbital hemorrhage from retrobulbar injection resulting in blindness. *Arch Ophthalmol* 1997;115:1085–6.
4. Puustjarvi T, Purhonen S. Permanent blindness following retrobulbar hemorrhage after peribulbar anesthesia for cataract surgery. *Ophthalmic Surg* 1992; 23: 450–2.
5. Rootman J. *Diseases of the Orbit*, JB Lippincott Company, Philadelphia, 188 pp. 587–97.
6. Hunts JH, Patrinely JR, Stal S. Orbital hemorrhage during rhinoplasty. *Ann Plast Surg* 1996; 37: 618–23.
7. Sholer JD. Topical anesthesia in a patient with a history of retrobulbar hemorrhage. *Arch Ophthalmol* 1993; 111:733–6.
8. Olitsky SE, Juneja RG. Orbital hemorrhage after the administration of sub-Tenon's infusion anesthesia. *Ophthalmic Surg Lasers* 1997; 28:145–6.
9. Rosen CE. Late migration of an orbital implant causing orbital hemorrhage with sudden proptosis and diplopia. *Ophthalm Plast Reconstr Surg* 1996;12: 260–2.
10. Amagasaki K, Tsuji R, Nagaseki Y. Visual recovery following immediate decompression of traumatic retrobulbar hemorrhage via transcranial approach. *Neural Med Chir (Tokyo)* 1998;38: 221–4.
11. Liu D. A simplified technique of orbital decompression for severe retrobulbar hemorrhage. *Am J Ophthalmol* 1993;116: 34–7.

## HIRUŠKI TRETMAN POSTONTUZIONOG HEMATOMA ORBITE U KASNOJ FAZI: PRIKAZ SLUČAJA

Miloš Jovanović<sup>1</sup>, Dragan Veselinović<sup>2</sup>

<sup>1</sup>*Institut za očne bolesti Prof dr Đorđe Nešić, Klinički centar Srbije, Beograd*

<sup>2</sup>*Klinika za očne bolesti, Klinički centar Niš*

## SAŽETAK

**Cilj istraživanja je prikazati uspešno izvedenu dekompresiju orbite kod hematoma orbite.**

Muškarac star 51 godinu je zadobio povredu desnog oka tokom pada u kadi. To je dovelo do razvoja velikog hematoma orbite sa proturzijom, smanjenim pokretima jabučice, bolom, diplopijom, savijanja retine usled hematoma koji je pritiskao očni bulbus i krvarenja u mrežnjači, povišenog intraokularnog pritiska i oštećene vizuelne oštine do 2/60. Pacijent je medikamentozno tretiran mesec dana, ali rezultati nisu bili zadovoljavajući i mesec dana nakon povrede je urađena prednje donja transkutana orbitotomija. Tokom hirurške intervencije uklonjen je hematoma i deo orbitalnog masnog tkiva.

Očna jabučica se povukla i egzoftalmus je nestao odmah nakon operacije, dok je nakon nekoliko dana došlo i do normalizacije pokretljivosti očne jabučice, nestanka savijanja retine sa postepenim povlačenjem hemoragije, normalizacije intraokularnog pritiska, smanjenja bola i diplopije, kao i povratka oštine vida na normalu.

Ovaj prikaz ilustruje da dekompresija orbite kod orbitalnog hematoma može biti uspešna čak i u kasnoj fazi, pa i jedan mesec nakon povrede. Smatra se da hiruršku intervenciju treba izvesti iskusan očni hirurg.

**Ključne reči:** kontuzija orbite, hematoma orbite, dekompresija orbite