



Professional article

ACTA FAC. MED. NAISS. 2005; 22 (2): 107-111

Ivona Đorđević,
Zoran Marjanović

Clinic for Pediatric Surgery,
Niš

CLINICAL SYMPTOMS AND SIGNS OF INVAGINATION IN CHILDREN'S POPULATION

SUMMARY

Intussusception (invagination) is a specific form of bowel occlusion and stop in bowel passage. Also, it is one of the most common problems in abdominal surgical pathology in children population. It is seen in 1–4 children per 1000 births, being more common in boys than girls (3:2), in the period from 6 to 9 months of age.

The most frequent form is ileocecal (80%), ileocolic, ileoileal and colocolic. Most cases are idiopathic (90%), with no identifiable lesion acting as "lead point" or pathological apex of the intussusceptum. But, in 10% of all cases, specific "lead points" are found. A Meckel diverticulum is the most common lead point followed by hypertrophic lymphatic nodes, polyps and duplications. Other "lead points" described include submucosal hemorrhage with Henoch-Schonlein purpura, hemangiomas and ectopic pancreatic tissue in intestinal mucosa.

The aim of the study was to define the commonest clinical symptoms which can help surgeon to make an adequate diagnosis of intussusception in children's population.

During the period of three years (2002–2004), 22 patients with the diagnosis of intussusception were hospitalized at the Clinic for Pediatric Surgery in Niš. The study encompassed 14 boys (63.63%) and 8 girls (36.36%) – approximately 7.33 cases yearly.

The most commonest forms of intussusception in our study were ileocecal and ileoileal (90.63%), followed with colocolic and ileocolic (9.09%). The classic triad of colicky intermittent painful crises, vomiting, and red "currant jelly" stools occurs in most of the patients. Temperature, lethargy, adynamia and convulsiones usually occur later during the process.

The triad of symptoms and signs is pathognomonic for most of the patients with invagination. Early diagnosis is very important because it can provide nonsurgical treatment (by hydrostatic reduction), or less radical intervention (with no bowel resection).

Key words: invagination, "currant jelly", clinical symptoms

INTRODUCTION

Intussusception was first described by Barbet from Amsterdam in 1674. He also suggested surgical treatment. In 1876, Hirschsprung first reported the technique of hydrostatic reduction.

Intussusception (invagination) is a specific form of intestinal occlusion. It is invagination of a proximal portion of intestine (intussusceptum) into

distal portion (intussusceptions) and is one of the most common problems in children abdominal surgical pathology (1). The term of intussusception describes the character of the problem: "in" takes origin from the latin word "intus" that means inside, "susciptiere" that means to take (2).

The incidence of intussusception is 1.5–4 cases per 1000 live births, with male-to-female ratio of 3:2 (3). The greatest incidence of idiopathic

intussusception is in infants from 6 to 9 months of age. A seasonal incidence has been described, with peaks in the spring, summer, and the middle of the winter. These periods correspond to peaks in the occurrence of seasonal gastroenteritis and upper respiratory tract infections.

Intussusception is most often idiopathic. Most infants and toddlers (95%) do not have an identifiable specific lead point. In these cases, careful examination may reveal hypertrophied mural lymphoid tissues (Payer patches), which are due to adenovirus or rotavirus (4). A specific lead point that draws the proximal intestine and its mesentery inward and propagates it distally through peristalsis is identified in only 5% of cases and is most commonly found in cases of ileoileal intussusception (5).

Intussusception is most often ileocecal (80%), but it may be ileocolic, ileoileal and colocolic. One of the main causes for intussusception could be disproportion between ileum and ileocecal valve in infants and young children (6).

Specific lead points are more commonly found in older children and nearly always in adults with intussusception. A Meckel diverticulum is the most common lead point, followed by polyps and duplications. Other lead points described include lymphomas, submucosal hemorrhage with Henocho-Schonlein purpura, hemangiomas and ectopic pancreatic tissue in intestinal mucosa, and lymphosarcomas. Children with cystic fibrosis may present with intussusception due to concentrated meconium in the terminal ileum. Postoperative jejunoileal or ileoileal intussusception, which usually does not have a specific lead point, account for about 1% of intussusceptions in children of all ages.

Intussusception results in bowel obstruction, followed by congestion and edema with venous and lymphatic obstruction. Progressively, this leads to arterial obstruction and subsequent necrosis of the bowel. Ischemia and then necrosis result in fluid sequestration and bleeding from gastrointestinal tract. If untreated, the bowel may perforate and the patient becomes septic.

The classic triad of colicky abdominal pain, vomiting and red "currant jelly" stools is typical of intussusception.

The first symptom that follows the intussusception is pain (7).

An infant with intussusception has a history of severe cramping or colicky abdominal pain occurring intermittently every 5–30 minutes. During these attacks, the infant screams and flexes at the waist, draws the legs up to the abdomen, and may appear pale. These episodes may last for only a few seconds and are separated by periods of calm normal appearance and activity. At last, the pain becomes constant.

However, some infants become quite lethargic and somnolent between attacks. Early vomiting of undigested food may occur. As attack continues emesis may turn bilious. Stools that appear normal early in the course of the illness, eventually become dark red and mucoid (resembling currant jelly) – a sign of intestinal ischemia and mucosal sloughing.

Depending of clinical presentation, dehydration or shock followed by adynamia and lethargy can be seen.

Initial inspection may reveal a robust infant who appears healthy. Between attacks, the infant may appear somnolent or quite normal, and findings on examination of the abdomen may be quite unremarkable. During an attack or spasm, the infant suddenly appears startled or anxious and begins to scream. Upon initial inspection, the abdomen may appear scaphoid; during paroxysmus it may be rigid; and later in the course of the illness, it may become distended with signs of peritonitis. A careful palpation, after an attack has subsided, may reveal an ill-defined or sausage-shaped mass ("buden"). With early ileocolic intussusception, the mass is typically found in the right upper quadrant of abdomen.

The rectal examination should commence with inspection of fecal material in the diaper. Normal-appearing stool supports the diagnosis. A digital rectal examination should be performed routinely looking for blood or a mass higher in the anal canal. "Currant jelly" stool is seen in almost 90 % of all cases.

Characteristic triad of symptoms: painful crises, vomiting and "currant jelly" stools are pathognomonic signs that helps the surgeon to make an adequate diagnosis. Palpation of "buden" can also also in making the diagnosis.

Blood pressure, heart frequency and body temperature are also valid parameters to follow.

Stable patients with highly suspected intussusception without an evidence of ischemic bowel, perforation, or sepsis may undergo immediate contrast enema for the diagnosis and treatment of suspected intussusception.

Reduction of intussusception by hydrostatic reduction (barium enema) known as irrigoradioscopy is both therapeutic and diagnostic. A typical sign is the "mouth of snake" that demonstrates a stop in bowel passage (obstruction). Contraindications to enema reduction include evidence of bowel perforation and peritonitis, and unstable patients (8).

Ultrasonography is best used as a diagnostic tool of exclusion when the index of suspicion of intussusception is lower. This method is very useful in experienced hands for the diagnosis of ileoileal intussusception. Color Doppler ultrasonography is very powerful to detect vascular perfusion of invagination, and to determinate its' vitality.

AIM

In the study, we tried to explore the clinical presentation of symptoms and signs of intussusception, as one of the most urgent illnesses in children abdominal surgical pathology.

Particularly, we focused our search on certain pathognomonic signs in clinical presentation in order to make the prompt and adequate diagnosis, to accelerate therapy and to reduce aggressiveness and radical surgical treatment.

METHODS

In our study we used medical records and operative protocols of children hospitalized at the Clinic for Pediatric Surgery in Nish in the period 2002–2004 with the diagnosis of intussusception. The results were presented graphically and by tables.

RESULTS

During the period of three years (2002-2004), 22 children were hospitalized at the Clinic for Pediatric Surgery in Nish. All of them had the diagnosis of intussusception.

In this study, there were 14 boys (63.63%) and 8 girls (36.36%) that is approximately 3:2 in favour of boys. The average of cases was 7.33 yearly. 12 children came from cities, and 10 of them were from rural places (villages). Also, the seasonal incidence has been described, with peaks in the summer and winter months. These periods correspond to peaks in the occurrence of seasonal gastroenteritis and upper respiratory tract infections (table 1).

Table 1. Frequency of invagination through the seasons of one year

season of the year	spring	summer	autumn	winter
number of patients	3	11	2	6

Our results showed that higher incidence was registered in ileocecal and ileoileal forms of intussusceptions (90.63%), followed by colocolic and ileocolic forms (9.09%) (figure 1).

The presence of specific pathoanatomical substrate is possible. In 6 cases (27.27%) the so-called "lead point" was found: in 4 cases this substrate was in the form of hypertrophied lymph nodes, but in 2 patients it was a Meckels' diverticulum.

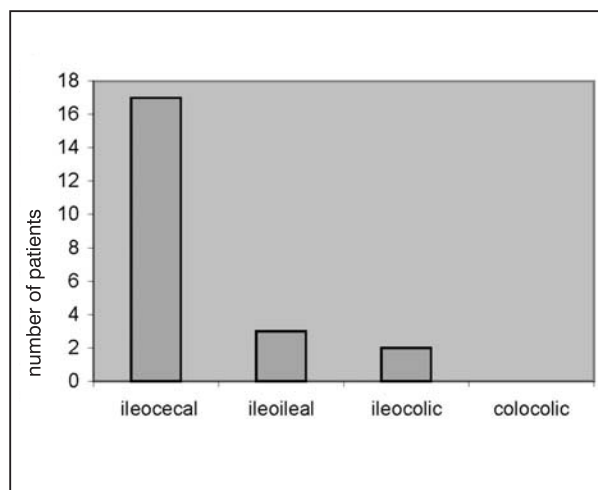


Figure 1. Frequency of specific forms of invagination in children's population

Prognostically, the most important criteria was the period between the initial symptoms of illness till arrival to hospital (9). The result are: within 12 hours from initial symptoms 9 patients came to our clinic, 7 patients came within 24 hours, and 6 patients came within 48 hours. Therapeutically, the results were conditioned with these circumstances.

In most patients with no determined pathoanatomical substrate (lead point) – so-called idiopathic forms, we performed a manual desinvagination. In one patient we did hydrostatic reduction of intussusception by barium. On the contrary, in cases with pathoanatomical substrate (lead point) surgical therapy is more radical, with intestinal resection in high percentage (table 2).

Table 2. Forms of surgical therapy in children with idiopathic intussusception. Other group are children with pathoanatomical substrate "lead point"

types of intussusception	desinvaginatio manualis	hemicolectomia dextra	resectio intestini ilei et T-T anastomosis	desinvaginatio with barium
idiopathic	15	0	0	1
with "lead point"	2	1	3	0

We were particularly interested in clinical presentation (symptoms) and our results are shown in the graph. Most frequent clinical symptoms are: presence of blood in stools, painful colicky crises and vomitus. Occasionally, after these dominant symptoms, there were others such as: febris, adynamia, prostration, even convulsions. Conclusion: the triad of symptoms (colicky pain, vomitus and "currant jelly") is pathognomonic for making the diagnosis of intussusception (figure 2).

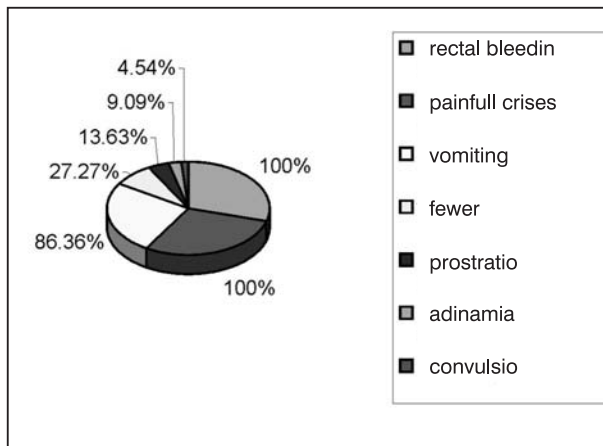


Figure 2. Symptoms and signs of invagination in children

Out of 22 children included in this study, 6 of them were vaccinated and received Polio vaccine during the period of one month before the intussusception. Vaccine causes the diffuse reactive lymph node hyperplasia. Being the pathoanatomical substrate ("lead point"), Payers' patches initiate the onset of intussusception. There was no mortality recorded.

DISCUSSION

Although invagination is relatively common in pediatric surgery, significant variability and treatment modalities exist (10).

The greatest risk for invagination is between 6 and 12 months of age. 95% of our patients were under the age of one year. The commonly affected infants were between four and six months of age, which was partly similar to other studies. It corresponds with maturation of normal intestine moves and peristaltics (11).

Early diagnosis and treatment are crucial in the treatment of childhood invagination, out of which 90–95% are idiopathic. As it has been shown in our results, the predominant place for invagination is ileocecal valve, which is caused with discrepancy of volume between small intestine and colon in young children's population.

It is very difficult to determine the outcome of this disease with the help of surgery because there are many factors which determine it. However, the main three are: how long the child has had the invagination, how much of the bowel has been damaged, and where the lesion is located. The longer the lesion remains in the bowel, the poorer its prognosis is.

The frequency of symptoms and signs in patients with invagination varies widely from one study to another. The most common symptoms regarding our patients were vomiting, followed by rectal bleeding and abdominal pain, which was comparable with other studies (12). Clinical presentation of disease is pathognomonic in most cases, which is why we preferred to explain these symptoms. Of course, except these expected signs, we could also see some others like: febris, adynamia, prostration or convulsions.

The presence of rectal blood and abdominal mass were most common signs of examination. Similar findings were revealed in other studies (13). Except the clinical investigation which is the most important in diagnosis, ultrasonography is the method of choice because it is noninvasive and reliable in diagnosis of intestinal invagination, and useful in control after hydrostatic reduction.

Early diagnosis is the key of nonsurgical treatment (hydrostatic reduction) or less radical surgical treatment (no bowel resection, but only desinvagination). Failure to diagnose invagination in the first 24 hours will decrease the rate of successful hydrostatic reduction and therefore will increase the need for surgical intervention and the period of hospitalization (14).

CONCLUSION

By following the results we found:

1. seasonal incidence with peaks in summer and winter months,
2. approximately 7.33 cases yearly, usually in urban population of children,
3. babies from 6 to 9 months of age were dominant population with higher risk of incidence (67.67%),
4. ileocecal and ileoileal form of intussusceptions make a 90.63 % of all forms of intussusceptions,
5. in 27.27 % we proved the existence of the specific pathoanatomical substrate (lead point). In this group of patients surgical procedure was more radical (with resection of ileum or hemicolectomy),
6. in patients who came to our clinic within 36 hours or even longer from the initial symptoms and signs, surgical procedure was more radical,
7. classic triad of symptoms (painful crises, vomitus and "currant jelly" stools) was pathognomonic in high percentage, which suggests intussusception.

REFERENCES

1. Krstić Z. Osnovi dečje hirurgije. BMG, Beograd, 1993: 165-171.
2. Schulman H, Laufer L. Chronic intussusception in childhood. Eur Radiol 1998; 8: 1455-1456.
3. Hase T, Kodoma M, Mizukuro T. From air to barium reduction of intussusception in children. Pediatr Surg Int 1998; 13: 223-225.
4. Linke F, Eble F, Berger S. Postoperative intussusception in childhood. Pediatr Surg Int 1998; 14: 175-177.
5. Susan L, Bratton M. Intussusception-hospital size and risk of surgery. Pediatrics 2001; 107: 299-303.
6. O'Neill J, Rowe MI, Grosfeld JL et al. Pediatric Surgery. Mosby-Year book, Missouri: 1998: 567-76.
7. Huang BY, Warshauer DM. Adult intussusception: diagnosis and clinical relevance. Radiol Clin North Am 2003; 41: 1137-51.
8. Eshed I, Witzling M, Gorenstein A, Serour F. Reduction of intussusception by air enema in children-experience over a 13-year period Harefuah. J Pediatr Surg 2003; 142: 659-61.
9. O'Ryan M, Lucero Y, Pena A, Valenzuela MT. Two-year review of intestinal intussusception in six large public hospitals of Santiago, Chile. Pediatr Infect Dis J 2003; 22: 717-21.
10. Papadopoulou F, Efremidis SC. Familial intussusception. J Pediatr Surg 2002; 37: 1549-51.
11. Medina-Franco H, Ramos-de la Medina A, Arista-Nasr J. Intussusception in adults. Case report with uncommon etiology and review of the literature. Rev Gastroenterol Mex 2002; 67: 103-6.
12. Robinson CG, Hernanz-Schulman M, Zhu Y, Griffin MR, Gruber W, Edwards KM. Evaluation of anatomic changes in young children with natural rotavirus infection: is intussusception biologically possible. J Infect Dis 2004; 189: 1382-7.
13. Chan KL, Chan JK, Peh WC, Chan KW, Tam PK. Endotoxemia associated with intussusception and its diagnostic and surgical interventions. Pediatr Surg Int 2002; 18: 685-8.
14. Osamu D, Koji A., Hutson J. Twenty-one case of small bowel intussusception. Pediatr Surg Int 2004; 10: 1055-9.

KLINIČKI SIMPTOMI I ZNACI INVAGINACIJE U DEČIJOJ POPULACIJI

Ivona Đorđević, Zoran Marjanović

Klinika za dečiju hirurgiju i ortopediju Niš

SAŽETAK

Invaginacija (intususcepcija) je specifičan vid zastoja u crevnoj prolaznosti koji, po svojoj učestalosti, zauzima vidno mesto u dečijoj abdominalnoj hirurškoj patologiji.

Najčešće pogađa decu u toku prve godine života i to između 6. i 9. meseca, pri čemu na 3 obolela dečaka dolaze 2 devojčice. Incidenca iznosi 1-4 na 1000 živorođene dece. Najčešća forma intususcepcije je ileocekalna (80 %), slede ileokolična, ileoilealna i kolokolična. Invaginacija je najčešće idiopatska (u skoro 90 % slučajeva), dok je u vrlo malom procentu opisano postojanje patoanatomskog supstrata (tačke vodilje), koji se odlikuje uvećanim limfnim žlezdama ili Mekelovim divertikulumom. Hirurška terapija kod ove druge grupe je mnogo radikalnija.

U studiji smo želeli da definišemo najčešće kliničke simptome koji bi opredelili hirurga u pravcu pravilne dijagnoze invaginacije.

Za period od 3 godine (2002-2004), koji smo obuhvatili radom u našoj studiji na Klinici za dečiju hirurgiju i ortopediju, hospitalizovano je dvadeset dvoje dece pod dijagnozom invaginacije (intususcepcije).

Od tog broja, u našoj seriji bilo je 14 (63,63 %) dečaka i 8 devojčica (36,36 %), a prosečan broj slučajeva bio je 7,33 godišnje. Najčešće su se pojavljivale ileo-cekalna i ileo-ilealna (90,63 %), dok su se kolo-količna i ileo-količna javljale mnogo ređe (9,09 %).

Najčešći klinički simptomi bolesti ispoljavali su se prisustvom sveže krvi u stolici, bolnim grčevima i povraćanjem, koji su činili dominantnu kliničku prezentaciju kod većine pacijenata. Slede febrilnost, malaksalost, adinamičnost, pa i konvulzije.

Trijas simptoma (bol, povraćanje i krv u stolici u vidu "gela od ribizle") je patognomoničan za dijagnozu bolesti.

Ključne reči: invaginacija, klinički znaci, "gel od ribizle"