



## Original article

ACTA FAC MED NAISS 2007; 24 (4): 209-212

Marija Mladenovic<sup>1</sup>  
 Andjelka Slavkovic<sup>1</sup>  
 Zoran Marjanovic<sup>1</sup>  
 Jablan Stankovic<sup>2</sup>

<sup>1</sup>Pediatric Surgery Clinic  
 Clinical Center Nis  
<sup>2</sup>Department of Urology  
 Clinical Center Nis

## PERINATAL TESTICULAR TORSIONS TREATED AT THE PEDIATRIC SURGERY CLINIC

## SUMMARY

The aim of the study was to evaluate the safety and emergency exploration of neonatal torsion.

We retrospectively reviewed the charts of 7 neonates (7 affected testicles) in the period 1980-2006.

Of 7 explored testicles, 2 were removed (28.6%). The remaining 5 (71.4%) were explored and fixed. No operative or perioperative complications were associated with emergency exploration.

During this twenty-six-year period, seven patients with the diagnosis of perinatal testicular torsion were treated at the Pediatric Surgery Clinic. All patients underwent inguinal or transscrotal exploration of the effected side. Non-contralateral orchidopexy was done. To date, no patient has had subsequent contralateral torsion. Perinatal testicular torsions are very rare and there are lots of controversies in the management. Emergency exploration of neonatal torsion is safe and rational method, and may result in higher testicular salvage rates.

*Key words:* testis, spermatic cord, spermatic cord torsion, newborn

## INTRODUCTION

Although first described more than 150 years ago, the cause and proper management of neonatal torsion has remained undecided. Controversy exists with regard to timing of exploration and necessity of removing affected testis. The contralateral testicle, which is at risk in a minority of patients, also represents a continuing dilemma.

Most neonatal torsions (72%) develop prenatally and it is hard to salvage these testicles. However, in the subset of patients in which torsion occurs at or soon after birth, emergency, exploration and detorsion result in a greater chance of testicular viability. Over these years, it has been our policy to perform emergency surgery in neonates in whom we believed there was a reasonable chance of salvaging

the gonad. In these healthy neonates, the diagnosis was made at birth or a change in physical examination was noted soon after birth and surgery was performed expeditiously.

## AIMS

We reviewed our experience in this period to determine whether our policy of emergency surgical exploration in selected patients increased testicular salvage rates or placed the patients who underwent such exploration under risk.

## MATERIAL AND METHODS

We retrospectively examined seven neonates with testicular torsion at the Pediatric Surgery

Clinic within the first 30 days of life in the period 1980-2006. All boys were examined preoperatively by a pediatric urologist or surgeon who did postoperative examination, too.

Diagnosis was made by:

1. history reported by parents
2. physical examination of patients
3. laboratory analysis and color Doppler sonography

### RESULTS

In the period 1980-2006 at the Pediatric Surgery Clinic in Nis, surgery was performed in 7 patients, 2 hours to 40 days old, on 7 affected testicles. All patients were healthy male newborns. Torsion affected 5 right (71.4 %) and 2 left testes (28.6 %). There were no cases of bilateral torsion.

All patients underwent inguinal or trans-scrotal exploration of the affected side, and all, but 2 (28.6 %) to whom orchiectomy was done, underwent detorsion of affected testis.

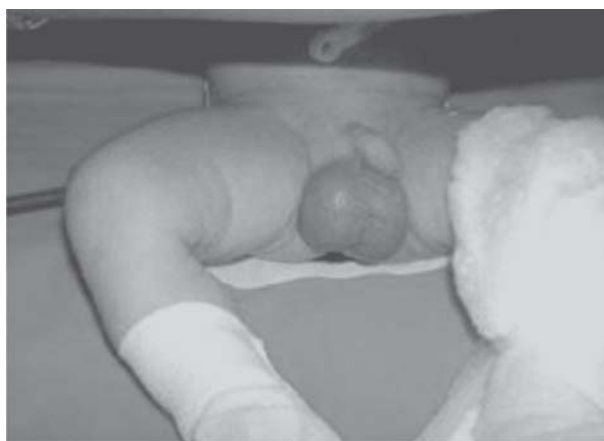

Figure 2. Perinatal testicular torsion with enlarged, bluish right hemiscrotum

We applied the inguinal approach in 5 (71.4%) patients. Orchiectomy in two patients was done due to obvious necrosis of testis. In 5 patients, orchiopexy was done on an emergency basis, usually within four hours of discovery.

Table 1. Surgical management

Neonatal testicular torsion	Surgical management				Σ	
	orhidectomy		detorsion		n	%
	n	%	n	%		
perinatal testicular torsion	0	0	1	14.3	1	14.3
postnatal testicular torsion	2	28.6	4	57.1	6	85.7
Σ	2	28.6	5	71.4	7	100

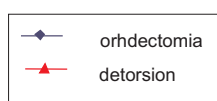
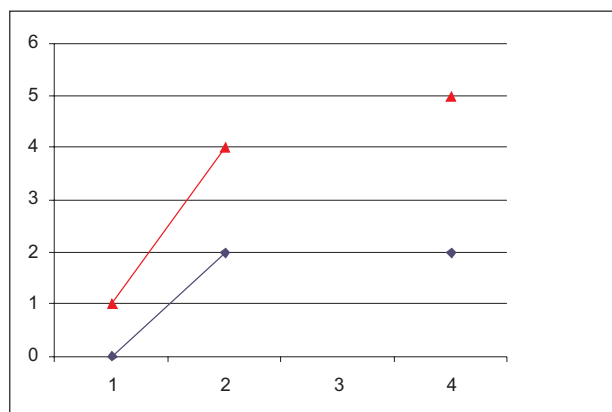


Figure 1. Surgical management and frequency of perinatal testicular torsion

None of these patients had any perioperative or postoperative complications. There were no wound infections. To date, no patient has had subsequent contralateral torsion.

### DISCUSSION

Perinatal testicular torsion is an uncommon entity and stands for approximately 12% of all testicular torsions during childhood. Usually, it is unilateral event and occurs during the prenatal period. This explains the high rate of testicular loss, approximately 95 % of affected testicles.

The controversies of the management of neonatal testicular torsion include:

1. when and if the apparently torsted gonad should be explored;
2. whether to remove or replace the grossly necrotic gonad;
3. whether contralateral orchiopexy is indicated.

The distinction between intravaginal and extravaginal torsion has been considered to be

important in deciding whether or not to perform contralateral orchiopexy in patients undergoing detorsion or orchiectomy (1).

Orchiectomy should be performed when the testis is clearly necrotic. Leaving a nonviable testis *in situ* in prepubertal torsion does not appear to have the same consequences for subsequent fertility as torsion in postpubertal boys, because immature spermatogenic elements do not have antigenetic stimulations during neonatal period (2).

When surgery is indicated, usually, the urgency of procedure is required. In a practical sense, PTT includes neonates with five definite clinical presentations and two different types of urgency to operate:

1. If torsion occurs in the perinatal period several months after birth, the newborn will be born with an absent testis (vanishing testis), in the case of which the patients should be treated as cryptorchid at an older age, or a nubbin testis when it should be approached as a sequel of a long-standing intrauterine testicular torsion.

2. If torsion occurs in the perinatal period, several weeks after birth, the child will present a regular, firm, painless scrotal mass, often in the upper part of the hemiscrotum, smaller than the contralateral normal testis, very attached to the scrotal wall, without acute inflammatory signs, not transmitting light.

3. If torsion occurs in the perinatal period several days after birth, the newborn will present a firm and painless scrotal mass, bigger or similar in size than the contralateral normal testis, without acute inflammatory signs, not transmitting light.

All these patients, with clinical evidence strongly suggestive of long-standing intrauterine testicular torsion, should be operated on electively when the child is in an optimal clinical status to confirm the suspected diagnosis, to remove the affected testis, and to explore the contralateral normal one.

Although there are no documented cases of tumors arising from microscopic focus of viable testicular tissue in nubbin testis, there is debate about the need for removing such testicular remnants to prevent this risk.

4. If torsion occurs in the perinatal period, a few days or several hours after birth, the newborn will be born with acute scrotal inflammatory signs.

5. If torsion occurs in the postnatal period within the first month of life, the child will be born without any scrotal sign and the acute scrotal inflammatory signs will appear later.

The last two groups of patients are rare and represent real surgical emergencies (3). It is accepted that the outcome for the twisted testicle has a direct

relationship with the duration of the testicular insult. Experimental models of testicular ischemia have shown the loss of spermatogenesis at 4 to 6 hours and of hormonal function at 10 to 12 hours after occlusion of testicular blood flow (4). In unclear cases, where history and physical examination do not suggest the clue, testicular torsion additional diagnostic methods (US, color Doppler sonography, scintigraphy) are very helpful. They can detect homogeneous testicles, symmetrical in size, as well as echotexture and blood flow of testicles. Bleeding with incision of the tunica albuginea may be the best prognostic sign of potential viability of the gonad (5).

The predisposing factor of PTT is the lack of firm anchoring between the testicle and the scrotal wall. As the testicle attached rapidly to the scrotal wall after birth, this kind of torsion seldom occurs after the perinatal period. In this way, during the neonatal period, there is a little but certain risk of having asynchronous contralateral testicular torsion. After the neonatal period, the chance of having contralateral testicular torsion is similar to that in the rest of the population and will depend on the existence of an abnormal insertion of the tunica vaginalis in association with the so-called bell clapper deformity.

Although some authors have recommended contralateral orchiopexy, there are some authors who think that it brings possibility of testis atrophy. Contralateral orchiopexy, at initial exploration, is recommended in all cases of unilateral torsion regardless of the age of patients or the perceived classification of torsion as intra- or extravaginal. Therefore, it is strongly recommended to use dartos-pouch fixation with no suture with eversion of the tunica vaginalis and excision of the hydatid of Morgagni. This avoids the risk of recurrent torsion, and avoids the possible increased risks of infertility and malignancy after the use of suture fixation. The technique of testicular fixation is a problem. An anterolateral or midline scrotal approach to the testis is again favored, with various methods of fixation. The most common is fixation with 3 or 4 monofilament non-absorbable suture for the tunica albuginea or the parietal tunica vaginalis. If exploration reveals a well-attached testicle to the scrotal wall with a normally inserted tunica vaginalis, one can choose between doing nothing and expecting that surrounding tissue will rapidly fix the testicle or perform a sutureless three-point fixation between tunica albuginea and scrotal wall, dartos-pouch technique (6,7). Contralateral orchiopexy must be performed in each case to protect the long-term viability of at least one testicle. The importance of these techniques is not just in simplicity of performance, but in a lower risk of contralateral testis torsion.

## CONCLUSION

In the period 1980-2006 at the Pediatric Surgery Clinic in Nis, surgery was performed in 7 patients, 2 hours to 40 days old, on 7 affected testicles. Diagnosis was made by:

1. history obtained from parents;
2. physical examination of patients;
3. laboratory analysis and color Doppler sonography.

All patients underwent inguinal or transscrotal exploration of the affected side and all, but 2 to whom orchiectomy was done, underwent detorsion of affected testis. Orchiectomy in 2 patients was done due to obvious necrosis of testis. In 5 patients, orchiopexy was done on an emergency basis, usually within 4 hours of discovery.

None of these patients had any perioperative or postoperative complications. It has been accepted that the outcome related to twisted testicle has a direct relationship with the duration of the testicular insult. To date, no patient has had subsequent contralateral torsion.

Orchiectomy should be performed when the testis is clearly necrotic. Leaving necrotic testis *in situ* in neonates does not have consequences for fertility later. Orchiopexy protects the viability of at least one testicle. The rate of the testicular salvage is very low. Emergency exploration in selected patients is safe and can result in increased rates of testicular salvage.

## REFERENCES

1. Yerkes BE, Brock W J III. Diagnosis and Management of Testicular Torsion. In: Lowell R. King, editor. Urologic surgery in infants and children. 1 st ed. USA: WB Saunders Company; 1998. p. 239-45.
2. Kirk J Pinto, H Norman Noe and Jerkins G R. Management of neonatal testicular torsion. J Urol 1997;158:1196-97.
3. Curevo J L , Grillo A ,Vecchiarelli C, Osio C and Prudent L. Perinatal testicular torsion : a unique strategy. J Pediatr Surg 2007 ;42:699-703.
4. Driver P C and Losty D P. Neonatal testicular torsion. BJU 1998 ;82:855-58.
5. Yerkes B E, Robertson M F, Gitlin J, Kaefer M ,Cain P M. and Rink C R. Management of perinatal torsion : today, tomorrow or never?. J Urol 2006;174:1579-83.
6. J D Frank and M O'Brien. Fixation of the testis. BJU Int 2002;89 (4):331-33.
7. A H Al-Salem. Intra-uterine testicular torsion: early diagnosis and treatment BJU Int 1999;83:1023-25

## PERINATALNE TORZIJE TESTISA LEČENE NA KLINICI ZA DEČJU HIRURGIJU

Marija Mladenović<sup>1</sup>, Anđelka Slavković<sup>1</sup>, Zoran Marjanović<sup>1</sup>, Jablan Stanković<sup>2</sup>

<sup>1</sup>Klinika za dečju hirurgiju, Klinički centar Niš

<sup>2</sup>Urološka klinika, Klinički centar Niš

## SAŽETAK

**Cilj rada bio je evaluacija podataka o dečacima sa perinatalnom testikularnom torzijom na Klinici za dečju hirurgiju u Nišu, pregled literature i predlog strategije tretmana koja bi se bazirala na kliničkom, hirurškom i histološkom nalazu.**

**Retrospektivno je obuhvaćena grupa od 7 neonatusa u periodu od 1980. do 2006. godine.**

**Od sedam eksplorisanih testisa dva su uklonjena (28.6 %). Ostala pet testisa (71.4%) podlegla su eksploraciji i fiksaciji. Pri kasnijim kontrolnim pregledima testisi su bili normalne funkcije. Nikakvih preoperativnih komplikacija nije bilo, kao ni komplikacija u toku samih intervencija.**

**U toku dvadesetšestogodišnjeg perioda, na Klinici za dečju hirurgiju lečeno je sedam neonatusa sa dijagnozom perinatalne torzije. Svi bolesnici su podvrgnuti ingvinalnoj ili transskrotalnoj eksploraciji zahvaćene strane. Nije učinjena kontralateralna orhidopeksija. Ni jedan bolesnik nije imao kontralateralnu torziju testisa nakon intervencije. Perinatalne torzije su dosta retke i u pogledu njihovog tretmana i danas postoje nesuglasice. Hirurška eksploracija i orhidopeksija zahvaćenog testisa je bezbedna i racionalna metoda koja može dovesti do porasta stope očuvanja testisa.**

**Ključne reči:** testis, funiculus spermaticus torzija funiculus spermaticus-a, novorođenče