

Scientific Journal of the Faculty of Medicine in Niš 2011;28(2):77-82

Original article ■

Portal Hypertension - Prevention from Variceal Rebleeding

Nenad Joksimović, Vladimir Andreevski, Magdalena Genadieva, Meri Trajkovska

University Clinic of Gastroenterohepatology, Faculty of Medicine in Skopje, Macedonia

SUMMARY

The aim of this study is to present the importance of pharmacologic therapy in an early prevention of bleeding and rebleeding from the oesophageal varices in patients with portal hypertension.

Three hundred and fifteen patients with liver cirrhosis have been evaluated and diagnosed in the University Clinic of Gastroenterohepatology. In the evaluation of the degree of the portal hypertension, besides the routine laboratory examination, Colour-Doppler ultrasonography, endoscopy and endosonography have been used. Depending on the results and therapy, all the patients were classified in two main groups:

- Patients treated with pharmacologic therapy (propranolol, isosorbide mononitrate and spironolactone)
- Control group composed of patients without therapy.

Both groups were divided into three subgroups depending of the degree of the oesophageal varices: 1st, 2nd and 3rd degrees.

Drug therapy was used as a measure of prevention from bleeding and rebleeding from the dysfunctional varicose-changed blood vessels in the oesophagus. The patients were treated with combined drug therapy with the main effect of decreasing the resistance of the liver circulation and splanchnic flow. We prescribed isosorbide 5 mononitrate, 2 times per day / 20mg, propranolol 2 times / 20mg per day and spironolactone 2 times / 25mg per day in combination in patients with cirrhosis and ascites.

From 315 patients with liver cirrhosis and portal hypertension, the A group included 162 (51%) patients. All of them were divided into three groups: with the 1st degree varices reported in 67 patients, 2nd degree in 59 patients and 3rd degree in 36 patients. Rebleeding was not detected in the first degree group. In the 2nd degree group, there were three patients, as well as in the group three with 3rd degree varices.

Group B involved 153 patients (49%). First degree varices were reported 69 patients, 2nd in 51 patients, and 3rd degree in 33 patients. Rebleeding was found in two patients with the 1st degree, 2nd degree in 17 patients with and 3rd degree varices in 15 patients.

The combination of propranolol, isosorbide 5 mononitrate and spironolactone reduces the portal pressure, which decreases the opportunity of variceal bleeding and rebleeding.

Key words: portal hypertension, liver cirrhosis, endoscopy, endosonography

Corresponding author:

Nenad Joksimović •

tel. +38970387050 •

e-mail: nenadjoksimovic@yahoo.com •

INTRODUCTION

Portal hypertension is high blood pressure in the portal vein and its tributaries. It is often defined as portal pressure gradient - the difference in pressure between the portal vein and the hepatic veins by 10 mmHg or more. Portal perfusion covers 72% of all liver oxygenation (1-3).

Causes can be divided into prehepatic, intrahepatic, and posthepatic. Intrahepatic causes include liver cirrhosis and hepatic fibrosis. The consequences of portal hypertension are caused by blood being forced down the alternate channels with the increased resistance to flow through the portal system. They include: ascites, hepatic encephalopathy, increased risk of spontaneous bacterial peritonitis, hepatorenal syndrome, splenomegaly (sequestration of red blood cells, white blood cells, platelets leading to pancytopenia), and portocaval anastomosis (oesophageal varices, gastric varices, anorectal varices (4, 5).

Pharmacologic prophylaxis of variceal bleeding and endoscopic band ligation yield similar results. After resuscitation, the management of active variceal bleeding includes administering vasoactive drugs, such as somatostatin, octreotide or terlipressin, use of endoscopic band ligation, sclerotherapy and balloon tamponade (6, 7).

The aim of this study is to present the importance of pharmacologic therapy in an early prevention from bleeding and rebleeding from the oesophageal varices in patients with portal hypertension.

MATERIAL AND METHODS

Three hundred and fifteen patients with liver cirrhosis have been evaluated and diagnosed in the University Clinic of Gastroenterohepatology (Figure 1). In the evaluation of the degree of the portal hypertension, besides the routine laboratory examination, Colour-Doppler ultrasonography, endoscopy and endosonography have been used. Depending on the results and therapy, all the patients were classified in two main groups:

- Patients treated with pharmacologic therapy (propranolol, isosorbide mononitrate and spironolactone)
- Control group composed of patients without therapy.

Both groups were divided into three subgroups depending of the degree of the oesophageal varices: 1st, 2nd and 3rd degrees (Figures 2, 3 and 4).

The groups were homogenous according to medical history, signs and symptoms, degree of liver injury, portal hypertension and degree of oesophageal varicosities.

Drug therapy was used as a prevention measure from bleeding and rebleeding from the dysfunctional

varicose-changed blood vessels in the oesophagus. The patients were treated with combined therapy of drugs with the main effect of decreasing the resistance of the liver circulation and splanchnic flow. We used isosorbide 5 mononitrate, 2 times per day/20mg, propranolol 2 times/20mg per day and spironolactone 2 times/25mg per day in combination (2, 3, 6).

As an adjunctive therapy to all forms of treatment in patients with episodes of active bleeding, we used parallel infusion of 600 µg/24h somatostatin analogue (sandostatine) for 72 hours.

Including criteria in our study were:

- High risk for bleeding and rebleeding, according to clinical, endoscopy and endosonography findings;
- Presence of portal hypertension;
- Degree of the disease according to Child-Pugh classification
- Histology.

Excluding criteria were:

- Patients who did not had controls;
- Patients who did not receive correct therapy;
- Death before the beginning of study.

The patients who could not receive the therapy were transferred into control group.

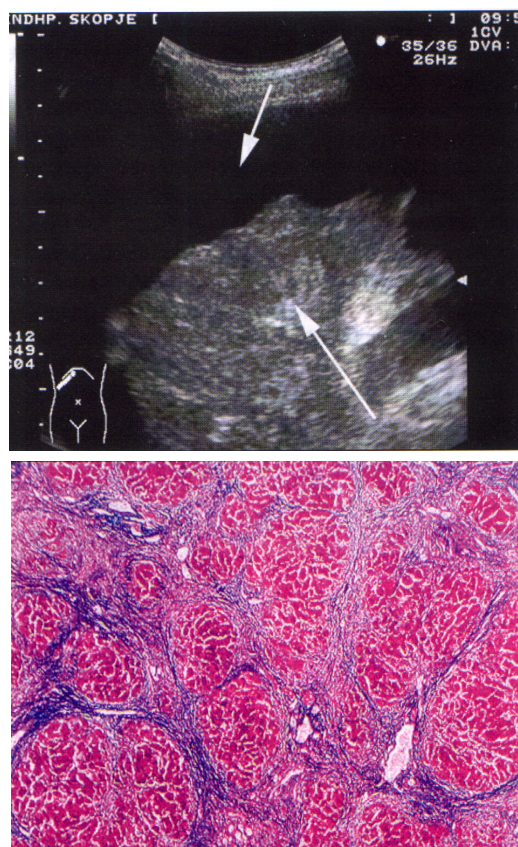


Figure 1. Sonography findings - liver cirrhosis and histology

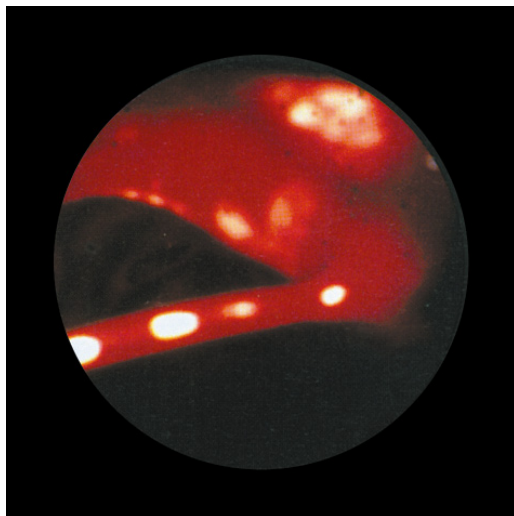
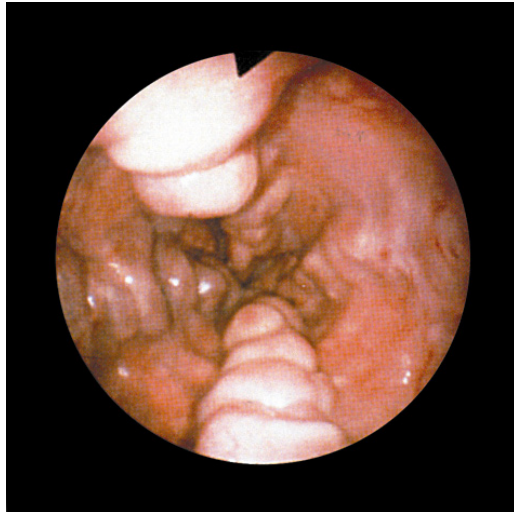


Figure 2. Esophageal varicosities - acute bleeding

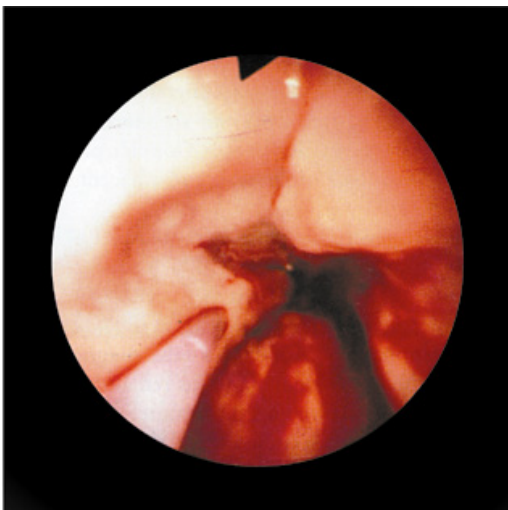


Figure 3. Esophageal varicosities - sclerosation

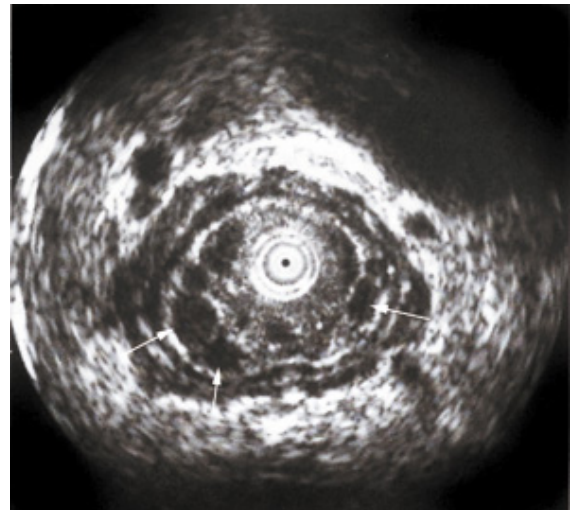


Figure 4. Endosonographic finding in esophageal varicosities

RESULTS

From 315 patients with liver cirrhosis and portal hypertension, with mean age 55.3 years, range 21-65 years, the A group included 162 (51%) patients. All of them were divided into the three subgroups: 67 patients with 1st degree varices, 59 with the 2nd degree, and 36 with the 3rd degree varices.

Rebleeding was not found in the first degree group, in the 2nd degree group there were three patients, as well as in the group with the 3rd degree varices (Table 1).

The endoscopic sclerosation was performed in 81 patients (60 males and 21 females) (Table 2).

All patients were scored according to CHILD classification. Ninety-one patients had CHILD A score, 47 CHILD B and 24 CHILD C scores. In the group of patients treated with triple therapy, there were no rebleeding (Table 3).

Group B included 153 patients (49%). First degree varices were reported in 69 patients, the 2nd in 51 patients, and the 3rd degree varices in 33 patients. Rebleeding was found in two patients with the 1st degree varices, the 2nd degree varices in 17 patients (Table 2).

The endoscopic sclerosation was performed in 79 patients (53 males and 26 females). According to the CHILD classification, CHILD A score was detected in 87 patients, CHILD B in 55 and CHILD C in 11 patients. In the last one, there were 4 patients with rebleeding (Table 3).

The patients of both groups, who experienced rebleeding, were successfully treated with sandostatine infusion therapy until cessation of a bleeding episode.

Table 1. Treated and control group of patients

<i>Mean age 55.3 years, range 21-65</i>			
Group	Patients / %	Male	Female
A	162 (51%)	105	57
B	153 (49%)	99	54
Sum.	315 (100%)	204	111

Table 2. Distinction of rebleeding in both groups

Varices Stadium	Group A	Rebleeding No	Group B	Rebleeding No	Re-rebleeding No
I	67	0	69	2	/
II	59	3	51	17	/
III	36	3	33	15	4
Sum.	162	6	153	34	4

Table 3. CHILD classification in the study

CHILD	A group	B group
A	91	69
B	47	51
C	24	33
Sum.	162	153

DISCUSSION

The combination of beta blockers and isosorbide-5-mononitrate is a well-known therapy for primary and secondary prevention of variceal hemorrhage in patients with cirrhosis. It is concluded that patients treated with the association nadolol plus isosorbide-5-mononitrate are not at increased risk of developing renal dysfunction or worsening of ascites compared with patients treated with nadolol alone (2). Our results have shown no complications from the combination of propranolol plus isosorbide-5-mononitrate, too.

In addition, the combination of propranolol plus other agents like prazosin causes a decrease in portal pressure. Albilos compared the portal pressure reduction and safety of the combination of propranolol plus prazosin with that of propranolol plus isosorbide-5-mononitrate. As a result of greater decrease in arterial pressure, the first combination was less tolerated than

propranolol plus isosorbide-5-mononitrate, meaning that the last one is much safer to use. Our results confirm the safety use of the second combination and successful decrease of portal hypertension in cirrhotic patients. Thus, it effectively prevents variceal bleeding at the same time (6).

Somatostatin and his analogues are highly effective in controlling variceal bleeding. Patients with active bleeding at emergency endoscopy may benefit from higher doses of somatostatin infusion (4). All of our patients either receiving or not the combination of propranolol, isosorbide-5-mononitrate and spironolactone, were effectively treated with sandostatine during rebleeding episodes.

Low-sodium diet plus the administration of spironolactone reduces portal pressure and azygos blood flow in patients with compensated cirrhosis, but low-sodium diet alone only produces mild effects that are likely to be clinically irrelevant (1). This fact justifies adding spironolactone to beta blockers and nitrates in our study,

in order to prevent variceal bleeding and rebleeding episodes.

CONCLUSION

The combination of propranolol, isosorbide 5 mononitrate and spironolactone reduces the portal

pressure, which decreases the risk of bleeding and rebleeding from the changed blood vessels of the oesophagus.

The variceal bleeding and rebleeding are most frequent in patients with CHILD C score according to Child-Pugh classification.

References

1. Garcia JC, Salmeron J, Feu F. Effect of low sodium diet and spironolactone on portal pressure in patients with compensated cirrhosis. *Hepatology* 2004;19:1095-99.
2. Merkel C, Gatta A, Donada C. Long-term effect of nadolol or nadalol plus isosorbide-5-mononitrate on renal function and ascites formation in patients with cirrhosis. *Hepatology* 2001;11:808-14.
3. Salemo F, Borroni G, Lorenzano E. Long term administration of isosorbide-5-mononitrate does not impair renal function in cirrhotic patients. *Hepatology* 2004;23:450-62.
4. Mointhong E. Randomised controlled trial comparing different schedules of somatostatin in the treatment of acute variceal bleeding. *Hepatology* 1999;28:771.
5. Wong F, Blendis L. Advances in treatment of portal hypertension. *Gastroenterology* 2000;118:802-3.
6. Albilos A, Garcia - Pagon JC, Iborra J. Propranolol plus prazosin compared to propranolol plus isosorbide-5-mononitrate in the chronic treatment of portal hypertension. *Gastroenterology* 1998; 115:116-23.
7. Lin HC, Tsai Y, Yang M. Hemodynamic effects of combination of propranolol and clonidine in patients with post-hepatic cirrhosis. *J Gastroenterol Hepatol* 1995; 10:181-6.

PORTNA HIPERTENZIJA - PREVENCIJA REKRVARENJA

Nenad Joksimović, Vladimir Andreevski, Magdalena Genadieva, Meri Trajkovska

Univerzitetska klinika za gastroenterohepatologiju, Medicinski fakultet u Skoplju, Makedonija

Sažetak

Cilj studije bio je da se predstavi značaj medikamentne terapije u ranoj prevenciji krvarenja i ponovnog krvarenja iz variksa jednjaka kod pacijenata sa portnom hipertenzijom.

Evaluirano je 315 bolesnika sa cirozom jetre, koja je dijagnostifikovana na Univerzitetnoj Klinici za gastroenterohepatologiju. Za procenu stepena portne hipertenzije, pored rutinskog laboratorijskog pregleda, rađena je kolor-dopler ultrasonografija, endoskopija i endosonografija. U zavisnosti od rezultata i terapije, bolesnici su podeljeni u dve grupe:

- Bolesnici lečeni medikamentnom terapijom (Inderal, Plodin i Aldactone)
- Kontrolna grupa - bolesnici bez terapije

Obe grupe bolesnika bile su podeljene u tri podgrupe u zavisnosti od stepena variksa jednjaka: I, II i III stepen.

Medikamentna terapija se primenjivala kao terapija prevencije krvarenja i ponovnog krvarenja zbog disfunkcionalnih varikozno izmenjenih krvnih sudova u ezofagusu. Bolesnici su lečeni kombinovanom terapijom, pri čemu je glavni efekat bio smanjenje otpora cirkulacije u jetri i protoka u visceralnim organima. U kombinaciji su prepisivani Isosorbid 5 mononitrat, dva puta dnevno u dozi od 20 mg, Propranolol dva puta po 20 mg dnevno, Aldactone dva puta po 25 mg dnevno kod bolesnika sa ascitesom.

Od 315 bolesnika sa cirozom jetre i portnom hipertenzijom, u grupi A su bila 162 (51%) takva bolesnika. Svi bolesnici bili su podeljeni u tri grupe: I stepen variksa imalo je 67 bolesnika, II stepen imalo je

59 bolesnika, III stepen 36 bolesnika. Ponovno krvarenje nije zabeleženo u grupi sa prvim stepenom, u grupi sa II stepenom bila su tri bolesnika, kao i u grupi sa III stepenom.

U grupi B bilo je 153 (49%) bolesnika. Varikse I stepena imalo je 69 bolesnika, II stepena 51 bolesnik, III stepena 33 bolesnika. Ponovno krvarenje zabeleženo je kod dva bolesnika sa I stepenom, 17 bolesnika sa II stepenom i 15 bolesnika sa III stepenom.

Kombinacija Propranolola i Isosorbide 5 mononitrata dovodi do sniženja portnog pritiska, što dalje smanjuje mogućnost krvarenja i ponovnog krvarenja iz izmenjenih krvnih sudova jednjaka.

***Ključne reči:* portna hipertenzija, ciroza jetre, endoskopija, endosonografija**