

Case report ■

Subconjunctival Infection due to *Dirofilaria Repens* - Case Report

Marija Trenkić Božinović¹, Branislav Tomašević¹, Simona Gabrielli², Suzana Otašević³, Aleksandar Petrović⁴, Gabriella Cancrini², Aleksandar Tasić⁵, Milan Trenkić⁶

¹Department of Ophthalmology, University Medical Center Niš, Serbia

²University Roma Sapienza, Department of Public Health and Infective Diseases, Italy

³University of Niš, Faculty of Medicine, Department of Microbiology and Immunology, Serbia

⁴Department of Histology and Embriology, Faculty of Medicine in Niš, Serbia

⁵Public Health Institute Niš, Serbia

⁶Department of Gynecology and Obstetrics, University Medical Center Niš, Serbia

SUMMARY

The aim of the survey was to present the clinical course and surgical treatment of the first case of human ocular dirofilariasis on the territory of the city of Niš, in the southeast Serbia.

Male patient, 57 years old, visited an ophthalmologist because of extreme swelling and redness of the eyelids of the right eye, scratches and pain in his right eye. On standard examination on biomicroscope, temporally 3 mm from the limbus, intrapalpebrally, a mobile parasite was observed in the subconjunctival space. Complete extraction of the living parasites, 13 cm long, was performed. A sample of the nematode based on morphological and morphometric characteristics was identified as *Dirofilaria repens*-like. The diagnosis was confirmed with molecular methods.

For ocular dirofilariasis, surgical methods and complete extraction of the parasite are the only ways to achieve complete recovery.

Key words: *Dirofilaria repens*, subconjunctival, human dirofilariasis

Corresponding author:

Marija Trenkić Božinović •

phone: +381 63 1094900 •

e-mail: marija.trenkic@gmail.com •

INTRODUCTION

Dirofilaria is a parasite of domestic and wild animals (dogs, cats and other canines) which requires two hosts for conducting the life cycle. As with other filaria species, mosquitoes transmit infectious microfilariae, which develop into fertile macrofilariae in their definitive host. Humans may become infected as aberrant hosts and apart from rare exceptions, the worms remain infertile (1-3).

In the genus *Dirofilaria* there are more than 40 described species, but only a few are the causes of the human infections worldwide: *D. immitis*, *D. tenuis*, *D. repens*, *D. inermis* and *D. ursi*. In Europe, human dirofilariosis is caused by *D. repens* (also known as the parasite of the Old World) and *D. immitis*, which is present throughout the world. *Dirofilaria repens* is a parasite of the skin and subcutaneous tissue in animals, mostly dogs. Human infections occur sporadically, can be visceral and superficial (skin and conjunctiva), and *D. repens* is cited as the most common cause. The life cycle of *Dirofilaria* is conducted through five developmental forms in the final and transitional hosts (1-5). In nature, host adult female *Dirofilaria spp.* produce thousands of live larvae (microfilariae) of the first stage, which are present in the blood of the host organism, that hematophagous insects inject during the diet, in which organism larvae evaluate to infective stage. Infective larvae penetrate into the host (human also) through a wound, and then migrate via blood to the subcutaneous tissue and subconjunctiva. It takes six months to develop the adult form in the final host. In man, as a non-friendly host, *Dirofilaria spp.* can develop to the stage 4 or 5, or only to immature adult nematodes in the various tissues and organs (1-5). That is the reason why in the human organism usually there are not circulated microfilaria. Until today, we have had only a few cases of human dirofilariosis in which microfilariae in the peripheral blood have been detected.

In the majority of cases, human infection is asymptomatic, subcutaneous nodules are most common on the head, trunk, upper limbs and joints, and can mimic benign skin tumors. Also, the infection of male genitals and mammary glands in women can occur. Visceral infections are presented in the form of a solitary or numerous lesions in the organs and tissue (1, 2, 5).

Human ocular dirofilariosis can affect the orbit and periorbital region, the skin of the eyelids (it is usually in the form of localized subcutaneous nodule in the eyelid or periorbital region as a benign tumor), the conjunctiva, the Tenon membrane, a retrobulbar space or has intrabulbar localization. These patients may have a severe disability, and surgery alone can be complicated due to localization (6-11). In this parasitic infection, the most frequent localization is subconjunctival or subtenonian space. When parasite has this localization, diagnosis is easier because of the possibility of direct detecting.

It can even imitate the mucoceles of lacrimal sacus. In case of parasites migration to the deeper parts of the orbit, diagnosis is made by excisional biopsy, which also leads to complete cure; however, the surgery is very complicated (12).

Parasitological identification is possible on the basis of the morphology and morphometry, if the nematode is not significantly damaged. *Dirofilaria repens* has a thick, ridged cuticle, broad rounded edges and thick muscle. In contrast, *Dirofilaria immitis* has a smooth cuticle. In recent years, we have used the molecular biology methods as PCR, which enables the detection and identification of species in the presence of minimal amounts of parasites (13-15).

The aim of this paper was to present the clinical course and surgical treatment of the first case of human dirofilariosis on the territory of the city of Niš, which has been known as the area without findings of canine dirofilariosis and the region with the lowest seroprevalence of human dirofilariosis in humans in the southeaste Serbia (16).

CASE REPORT

Male patient, 57 years old, visited an ophthalmologist because of extreme swelling and redness of eyelids of the right eye, scratches and pain in the right eye. The patient had no other ocular signs or symptoms, and his general condition was otherwise good. The patient's blood tests were within the normal limits, without eosinophilia. For five days he was treated with systemic and local antibiotics and corticosteroids. On the sixth day, when swelling was reduced, on the standard examination on biomicroscope, temporally 3 mm from the limbus, intrapalpebrally, a live mobile parasite was observed in the subconjunctival space. It was thread-like and white (Figure 1).

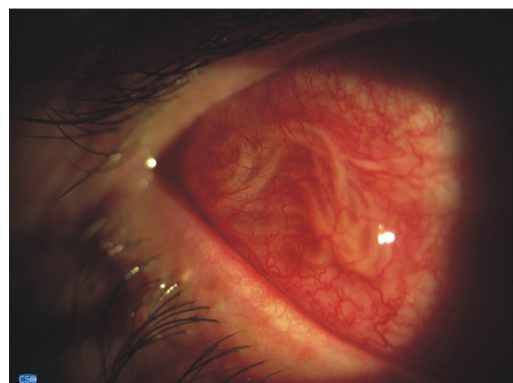


Figure 1. The parasite under the bulbar conjunctiva

On the same day, under the local anesthesia, complete extraction of the live parasite, about 13 cm long, was performed (Figure 2), which was delivered in the saline solution to the Department of Microbiology and Parasitology (Figure 3).

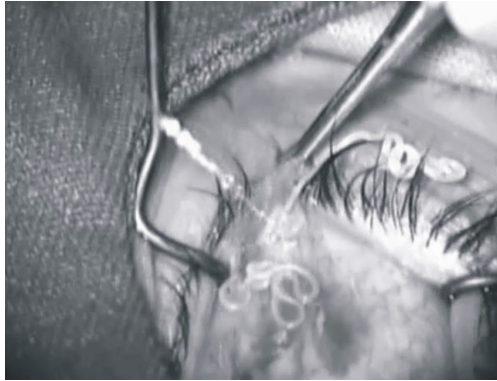


Figure 2. Operating extraction of the living parasites

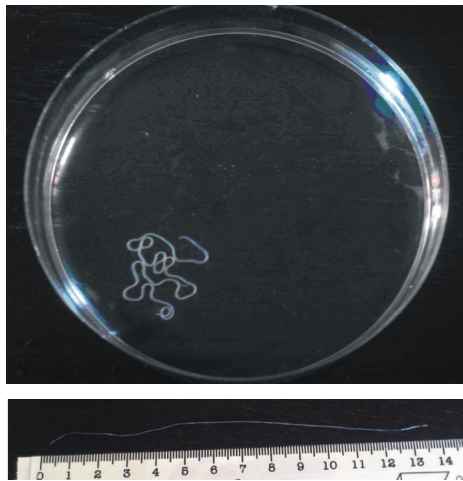


Figure 3. A full view of the adult worm, *Dirofilaria repens*-like, 13 cm long

A sample of the nematode based on morphological and morphometric characteristics was identified as *Dirofilaria* spp. (*Dirofilaria repens*-like). It was found that this was an adult female *D. repens*. Based on the presence of the notched cuticle, which is a characteristic of *D. repens* type, it is easy to differentiate this type from *D. immitis*, which has a completely smooth cuticle. In addition, the length of the parasite and the thickness of the cuticle are important parameters for the differentiation of these two types of *Dirofilaria*. This worm was long 129,5 mm and 0,475 mm wide (Figure 4 and 5). In addition, using a modified Knott test and a commercial filtration test (EVSCO, BUENA, NJ, USA), circulating microfilariae in the peripheral blood were not found.

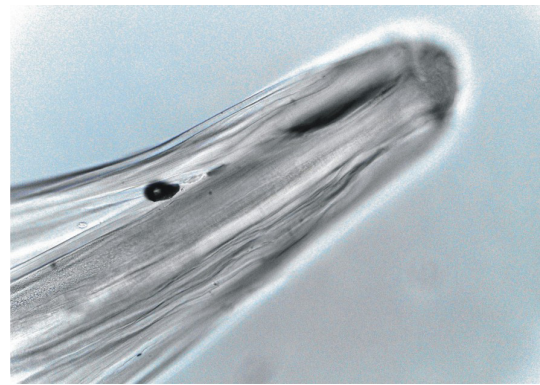


Figure 4. Photomicrograph of the anterior end and body of the worm X 200




Figure 5. Photomicrograph of the surface of the worm cuticle X 100

Genomic DNA was extracted from a small piece of the worm (about 25 mg) (NucleoSpin tissue; Macherey-Nagel, Duren, Germany) and submitted to PCR amplification filarioid-generic primers (cox1 gene fragment) (17). Amplicon was purified (SureClean; Bionline, London, U.K.) and then sequenced. The sequence was corrected by visual analysis of the electropherogram and compared with those available in the GenBank data base by BLAST analysis. Sequencing evidenced 100% identity with *D. repens* (Accession Number AJ271614), confirming the morphological diagnosis.

After successful extraction, the patient felt no discomfort. History data did not reveal any specifics (Figure 6).

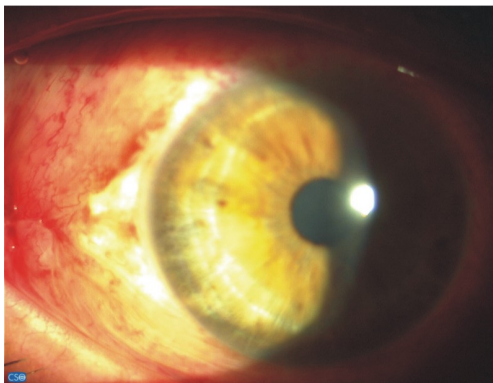


Figure 6. Postoperative appearance of the conjunctiva

DISCUSSION

Zoonoses caused by *Dirofilaria repens* are characteristic of the countries of the Old World (Italy, France, Greece, Spain, Africa, the Middle East and Asia). In recent years, there has been an increasing number of publications on this topic on the territory of Ukraine and Russia. Human dirofilariasis was registered in Croatia, Slovenia, Hungary (2, 18, 19).

In Serbia so far, about 34 cases have been reported and in southeastern Serbia only four cases of this subcutaneous infection. This is the first case of the human ocular, subconjunctival dirofilariasis on the territory of the southeast Serbia and the city of Niš. Note that in this case there was no history of patient's trips or stay in other parts of Serbia, such as Vojvodina which is considered as a hyperendemic area for *D. repens* in dogs (16, 20-24).

Previous research of dirofilariasis prevalence in dogs and humans pointed to the fact that the territory of the city of Niš is an area where dirofilariasis in dogs has not been detected and the region without reported human infections. However, the results of the recent re-

arch on seroreactivity to *Dirofilaria* antigens conducted in Serbia show that we can expect the human infection in our city because seroreactivity was proved in 5.3% (95% CI 0.1-24.6%) of examiness from Niš (16, 25).

In most cases of the human ocular dirofilariasis, nonspecific inflammatory reaction occurred, which was resistant to conventional antibiotic and anti-inflammatory therapy. In addition, a few episodes of disease exacerbation can occur until the definite diagnosis is made. In the described cases of the deep periocular localization, patients had nonspecific and even unusual symptoms, and were exposed to the harmful effects of various diagnostic procedures (7, 9, 12, 26). In case of human ocular dirofilariasis, the subconjunctival or subtenonic type, the localization allows easy and quick diagnosis of the parasite infection, since the conjunctiva is transparent and the parasite can be directly visible (27-29). The extraction may be difficult due to the mobility of the parasite. Some other ocular localizations as the peribulbar, intraorbital or even intrabulbare require serious and difficult surgical procedures to achieve the complete extraction of the parasite (27, 30).

CONCLUSION

Apparently, the dirofilariasis may occur more frequently in the future. The most important thing for doctors practitioners and clinicians, particularly ophthalmologists, is to consider human dirofilariasis in the differential diagnosis because the clinical diagnosis of *Dirofilaria* infections in most cases was wrong. For ocular dirofilariasis, surgical methods and complete extraction of the parasite are the only way to achieve complete recovery. Due to the fact that in most cases there are not circulated microfilaria, the use of antihelmintics is not justified in the treatment of these patients.

References

1. Pampiglione S, Rivasi F. Human dirofilariasis due to *Dirofilaria* (Nochtiella) repens: an update of world literature from 1995 to 2000. *Parassitologia* 2000; 42: 235-54.
2. Pampiglione S, Canestri-Trotti G, Rivasi F. Human dirofilariasis due to *Dirofilaria* (Nochtiella) repens: a review of world literature. *Parassitologia* 1995; 37 (2-3): 149-93.
3. Genchi C, Kramer LH, Rivasi F. Dirofilarial Infections in Europe. *Vector Borne Zoonotic Dis* 2011; 21. [Epub ahead of print]
4. Tasić A. Investigation of the prevalence of filariosis in dogs in some areas of Vojvodina. Thesis, University of Belgrade, Faculty of Veterinary Medicine. 2005.
5. Dzamić AM, Colović IV, Arsić-Arsenijević VS, Stepanović S, Borčić I, Dzamić Z, Mitrović SM, Rasić DM, Stefa - nović I, Latković Z, Kranjčić-Zec IF. Human *Dirofilaria*- repens infection in Serbia. *Helminthol* 2009; 83 (2): 129-37. <http://dx.doi.org/10.1017/S0022149X09341346>
6. Wesolowska M, Kisza K, Szalinski M, Zielinski M, Okulewicz A, Misiuk-Hojlo M, Szostakowska B. First case of heterochthonoussubconjunctivaldirofilariasis described in Poland. *Am J Trop Med Hyg* 2010; 83 (2): 210. <http://dx.doi.org/10.4269/ajtmh.2010.10-0084>
7. Aleshaev MI, Tatarchenko PI, Rumiantseva NF, Kostenko VV. Dirofilariasis of the eyeball. *Vestn Oftalmol* 2004; 120 (6): 35-6. [Article in Russian]
8. Mănescu R, Bărașcu D, Mocanu C, Pîrvănescu H, Mîndriă I, Bălășoiu M, Turculeanu A. Subconjunctival nodule with *Dirofilaria*repens. *Chirurgia* (Bucur) 2009; 104 (1): 95-7. [Article in Romanian]

9. Sangit VA, Haldipurkar SS. Subconjunctival dirofilariasis mimicking scleritis: first report from Western India. *Indian J Ophthalmol* 2012; 60 (1): 76-7. <http://dx.doi.org/10.4103/0301-4738.91343>
10. Malov VA, Cheremnykh LG, Gorbachenko AN, Moiseenko AV, Bertram LI, Kniazeva EF, Orlov MD. A clinical case of dirofilariasis. *Klin Med (Mosk)* 2005; 83 (5): 69-72. [Article in Russian]
11. Aiello A, Aiello P, Aiello F. A case of palpebral dirofilariasis. *Eur J Ophthalmol* 2005; 15 (3): 407-8.
12. Sathyan P, Manikandan P, Bhaskar M, Padma S, Singh G, Appalaraju B. Subtenons infection by *Dirofilaria repens*. *Indian J Med Microbiol* 2006; 24 (1): 61-2. <http://dx.doi.org/10.4103/0255-0857.19899>
13. Gabrielli S, Tasić S, Magi M, Cancrini G. Molecular diagnosis of human dirofilariasis from paraffin-embedded nodules. In *2nd European Dirofilaria days: 2009*. Edited by Morchón R, Simón F, Montoya JA. Salamanca, Spain: Morchón R, Simón F, Montoya JA, Genchi C; 2009:98-216.
14. Cancrini G, Montoya MN, Prieto G, Bormay-Linares FJ. Current advances in experimental diagnosis of human and animal dirofilariasis. In: *Heartworm infection in humans and animals*, Simon F, Genchi C. 2001; Eds: 103-120.
15. Cancrini G, Prieto G, Favia G, Giannetto G, Tringali R, Pietrobelli M, Simoã NF. Serological Assays On Eight Cases Of Human Dirofilariasis Identified By Morphology And DNA Diagnostics. *Ann Trop Med Parasitol* 1999; 93 (2): 147-52. <http://dx.doi.org/10.1080/00034989958627>
16. Tasić-Otašević S, Gabrielli S, Tasić A, Miladinović Tasić N, Kostić J, Ignjatović A, Popović Dragonjić L, Milošević Z, Cancrini G. Seroreactivity to *Dirofilaria* antigens in people from different areas of Serbia. *BMC Infect Dis* 2014; 14:68. <http://dx.doi.org/10.1186/1471-2334-14-68>
17. Casiraghi M, Bain O, Guerrero R, Martin C, Pocacqua V, Gardner SL, Franceschi A, Bandi C. Mapping the presence of *Wolbachia pipientis* on the phylogeny of filarial nematodes: evidence for symbiont loss during evolution. *Int J Parasitol* 2004; 34 (2): 191-203. <http://dx.doi.org/10.1016/j.ijpara.2003.10.004>
18. Muro A, Genchi C, Cordero M. Human dirofilariasis in the European Union. *Parasitol Today* 1999; 15(9): 386-9. [http://dx.doi.org/10.1016/S0169-4758\(99\)01496-9](http://dx.doi.org/10.1016/S0169-4758(99)01496-9)
19. Salamatin RV, Pavlikovska TM, Sagach OS, Nikolayenko SM, Korniyushin VV, Kharchenko VO, Masny A, Cielecka D, Konieczna-Salamatin J, Conn DB. Human dirofilariasis due to *Dirofilaria repens* in Ukraine, an emergent zoonosis: epidemiological report of 1465 cases. *Acta Parasitol* 2013; 58 (2): 592-98. <http://dx.doi.org/10.2478/s11686-013-0187-x>
20. Tasić A, Rossi L, Tasić S, Miladinović-Tasić N, Ilić T, Dimitrijević S. Survey of canine dirofilariasis in Vojvodina, Serbia. *Parasitol Res* 2008; 103: 1297-302. <http://dx.doi.org/10.1007/s00436-008-1132-z>
21. Tasić A, Tasić-Otašević S, Gabrielli S, Miladinović-Tasić N, Ignjatović A, Đorđević J, Dimitrijević S, Cancrini G. Canine *Dirofilaria* Infections in Two Uninvestigated Areas of Serbia: Epidemiological and Genetic Aspects. *Vector-Borne And Zoonotic Dis* 2012; 12 (12): 1031-35. <http://dx.doi.org/10.1089/vbz.2011.0949>
22. Tasić S, Stoiljković N, Miladinović-Tasić N, Tasić A, Mihailović D, Rossi L, et al. Subcutaneous Dirofilariasis in South-East Serbia-Case Report. *Zoonoses Public Health* 2011; 5(58): 318-22. <http://dx.doi.org/10.1111/j.1863-2378.2010.01379.x>
23. Trenkić-Božinović M, Tomašević B, Veselinović A, Petrović A, Tasić A, Otašević S. The first case of human ocular dirofilariasis in the city of Niš. *International Congress - XLVII Days of Preventive Medicine, Niš, 2013*. (<http://www.izjz-nis.org.rs/index.html>)
24. Ignjatović M, Veličković Lj, Mihailović D, Tasić A, Miladinović Tasić N, Otašević S. The human dirofilariasis - one more case in Southeastern Serbia. *International Congress-XLVII Days of Preventive Medicine, Niš, 2013*. (<http://www.izjz-nis.org.rs/index.html>)
25. Tasić A, Tasić S, Miladinović-Tasić N, Zdravković D, Đorđević J. Prevalence of *Dirofilaria repens* - cause of zoonosis in dogs. *Acta Fac Med Naiss* 2007; 24 (2): 72-5.
26. Nath R, Gogoi R, Bordoloi N, Gogoi T. Ocular dirofilariasis. *Indian J Pathol Microbiol* 2010; 53 (1): 157-9. <http://dx.doi.org/10.4103/0377-4929.59213>
27. Siepmann K, Wannke B, Neumann D, Rohrbach JM. Subcutaneous tumor of the lower eyelid: a potential manifestation of a *Dirofilaria repens* infection. *Eur J Ophthalmol* 2005; 15 (1): 129-31.
28. Gorezis S, Psilla M, Asproudis I, Peschos D, Papadopoulou C, Stefaniotou M. Intravitreal dirofilariasis: a rare ocular infection. *Orbit* 2006; 25 (1): 57-9. <http://dx.doi.org/10.1080/01676830500499224>
29. Masseron T, Sailliol A, Niel L, Floch JJ. Conjunctival dirofilariasis caused by *Dirofilaria repens*: report of a French case. *Med Trop (Mars)* 1995; 55(4 Pt 2): 457-8. [Article in French]
30. Gautam V, Rustagi IM, Singh S, Arora DR. Subconjunctival infection with *Dirofilaria repens*. *Jpn J Infect Dis* 2002; 55 (2): 47-8.

SUBKONJUNKTIVALNA INFEKCIJA IZAZVANA DIROFILARIJOM REPENS PRIKAZ SLUČAJA

Marija Trenkić Božinović¹, Branislav Tomašević¹, Simona Gabrielli², Suzana Otašević³,
Aleksandar Petrović⁴, Gabriella Cancrini², Aleksandar Tasić⁵, Milan Trenkić⁶

¹Odsek za oftalmologiju, Univerzitetski Medicinski centar Niš, Srbija

²Univerzitet Roma Sapienza, Odsek za javno zdravlje i infektivne bolesti, Italija

³Univerzitet u Nišu, Medicinski fakultet, Odsek za mikrobiologiju i imunologiju, Srbija

⁴Odsek za histologiju i embriologiju, Medicinski fakultet Niš, Srbija

⁵Institut za javno zdravlje Niš, Srbija

⁶Odsek za ginekologiju i akušerstvo, Univerzitetski Medicinski centar Niš, Srbija

Sažetak

Cilj ovog rada bio je da se predstavi klinički tok i hirurško lečenje prvog slučaja humane okularne dirofilariose na teritoriji grada Niša, u jugoistočnoj Srbiji.

Muškarac, 57 godina starosti, obratio se oftalmologu zbog izrazitog otoka i crvenila kapaka desnog oka, subjektivnog osećaja grebanja i bola u desnom oku. Standardnim pregledom na biomikroskopu, u međukapućnom prostoru, temporalno 3 mm od limbusa, uočen je mobilan parazit ispod vežnjače. U lokalnoj anesteziji urađena je kompletna ekstrakcija živog parazita, dugog 13 cm. Uzorak nematode, na osnovu morfoloških i morfometrijskih karakteristika, je mikroorganizam poput *Dirofilarie repens*. Dijagnoza je potvrđena molekularnim metodama.

Za humanu okularnu dirofilariozu, hirurška metoda, odnosno kompletna ekstrakcija parazita, jedini je i potpuni način izlečenja.

Ključne reči: *Dirofilaria repens*, subkonjunktivalna, humana dirofilarioza