

Original article

Morphological Variations of the Cemento-Enamel Junction in Permanent Dentition

Nenad Stošić¹, Stefan Dačić², Dragica Dačić Simonović²

¹University of Niš, Faculty of Medicine, Niš, Serbia

²Department of Restorative Dentistry and Endodontics, Clinic of Dentistry, Niš, Serbia

SUMMARY

Cemento-enamel junction (CEJ) is an important anatomical structure of the tooth, which is located in the cervical part of the tooth between the crown and root, or at the contact point between the enamel which overlaps the tooth crown and cementum overlapping the root dentin.

There are four possible relationships between two tissues that make the CEJ such as: the cement overlaps the enamel; the enamel overlaps the cement; the enamel and cement abut each other with no overlap; the enamel and cement are not in contact. The aim of this study was to determine the relationship between the enamel and cement which make the CEJ in different types of permanent teeth.

The material consisted of 30 permanent teeth with intact CEJ. Staining of CEJ was carried out using the methylene blue. After staining, the tooth was washed under the running water and drying at room temperature. Each tooth was longitudinally cut in the vestibular-oral direction. Observation of CEJ was done with Leica light microscope and images were obtained using a Nikon camera.

The results indicated that the most common form of CEJ between the cement and enamel in the region of CEJ was that cement and enamel abutted without overlap (36.7%), followed by the cement overlapping the enamel (33.3%), and the cases when a gap between the cement and enamel (16.7%) was present, and when the enamel overlapped the cement (13.3%).

Because of the morphological diversity of CEJ, careful performing of dental interventions in the region of tooth neck is necessary because they may change the morphology of this region, induce the pathological processes and hypersensitivity of teeth.

Key words: cemento-enamel junction, cement, enamel

Corresponding author:

Nenad Stošić

e-mail: nenadstosic10@gmail.com

INTRODUCTION

Cemento-enamel junction (CEJ) is an important anatomical and morphological structure of the tooth. It is located in the cervical part of the tooth between the crown and root, or at the contact point between the enamel which overlaps the tooth crown and cementum overlapping the root dentin (1,2).

Gingival fibers are annexed to the CEJ and thus contribute to the stability of the tooth; therefore, examining CEJ is a useful clinical parameter for determining periodontal disease (2,3). In young individuals, CEJ is covered with the gingiva and thus is protected from various agents. The aging process, as well as the effects of various physical and chemical agents, may cause the withdrawal of the gingiva and the appearance of lesions in the area of CEJ.

Disturbance of the integrity in the cement or enamel may expose dentin around the tooth neck and cause hypersensitivity, caries or erosion (2,4).

The relationship between the cementum and enamel in the neck of the tooth varies. Connections between these two tissues that make up for mineralized CEJ can be bonded in four ways: 1. The cement overlaps the enamel, 2. The enamel overlaps the cement 3. The enamel and cement abut each other with no overlap. 4. The enamel and cement are not in contact (5).

From the clinical point of view, the most favourable relationship in the CEJ is when the enamel overlaps the cement, as then the activity of acids and enzymes from the gingival biofilm have the least detrimental effect on the cervical region of the tooth. Furthermore, probing of the CEJ may have substantial clinical importance even in younger patients for the teeth whitening procedures, frequent caries and erosions of the tooth neck.

AIMS

The aim of this study was to determine the interrelationship of these two mineralized tissues that make the CEJ in different types of permanent teeth.

MATERIALS AND METHODS

The research was conducted in the period from February to March 2015, at the Department of Dentistry at the Faculty of Medicine, University of

Nis, Serbia. The study sample was comprised of 60 dissected parts of permanent teeth (30 crowns and 30 roots) from adult patients of both sexes, aged 18-65 years. The sample consisted of teeth from the upper and lower jaws (incisors, canines, premolars, molars) with the intact cement-enamel border. Teeth were extracted either for medical, orthodontic or prosthetics reasons.

We applied the following procedure for the preparation of the tooth: each extracted tooth from the upper and lower jaw was carefully cleaned off residues of biological tissue, using a handpiece and steel drill, with adequate polishing abrasive discs, a rubber band, and abrasive paste. Before staining, the surface of each tooth was coated with two layers of clearcoat, which was applied both on the crown and on the root of the teeth, except in the region of 1 to 1.5 mm around CEJ. Further, we immersed the teeth into a container filled with 10% formalin, to facilitate staining and afterwards the teeth were left 24 hours to dry out. Next we immersed them in a 1% solution of methylene blue for 24h and lastly, after the staining was carried out, the teeth were washed under the running water for 1 minute and left to dry out for 12 to 24h.

Each tooth was longitudinally dissected across the vestibular-palatal (lingual) plane in order to produce two samples with similar size. Cutting was done using a diamond disc mounted on a handpiece with water cooling.

Examination of the CEJ was performed using a light microscope Leica, while the magnification and photographing were performed using a Nikon camera with a blue filter.

RESULTS

From a sample total of 60 dissected parts of teeth, the following results were obtained. The most common relationship between the cement and enamel in the region of CEJ was that cement and enamel were abutting without overlap (36.7%), followed by the cement overlapping the enamel (33.3%). The least observed cases of CEJ were visible when a gap between the cement and enamel (16.7%) was present, and when the enamel overlapped the cement (13.3%).

The light microscopic images of four types of the cement-enamel junction are shown in Figures 1-4.

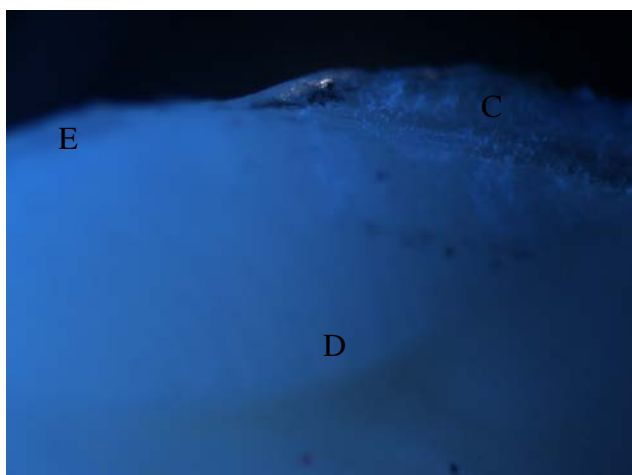


Figure 1. Light microscopy finding of morphological variations of the cemento-enamel junction (CEJ) when the cement overlaps the enamel
E – enamel, C- cement, D - dentin




Figure 3. Light microscopy finding of morphological variations of the cemento-enamel junction (CEJ) when the cement and enamel abut each other
E – enamel, C- cement, D - dentin

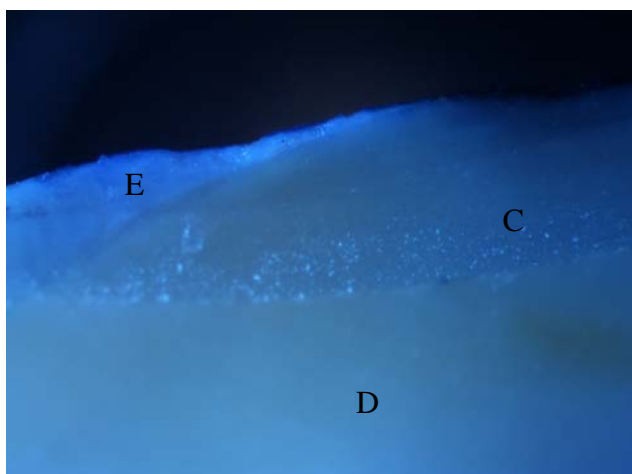


Figure 2. Light microscopy finding of morphological variations of the cemento-enamel junction (CEJ) when the enamel overlaps the cement
E – enamel, C- cement, D - dentin



Figure 4. Light microscopy findings of morphological variations of the cemento-enamel junction (CEJ) showing a distance between the two mineralized tissues with initial caries - denuded dentin-a gap.
E – enamel, C- cement, DC – denture caries

The distribution of the four types of mineralized dental tissues in the region of CEJ is provided in Table 1.

Table 1. Distribution of the relationship between mineralized tissues at the cemento-enamel junction in the total sample (n=60)

Type of CEJ	n=60	%
I	20	33.3%
II	8	13.3%
III	22	36.7%
IV	10	16.7%

- I – Cement overlaps enamel
- II - Enamel overlaps cement
- III -Cement and enamel abut each other with no overlap
- IV -Gap between cement and enamel

We analyzed the distribution of the mutual relationships between the cement and enamel including all dissections of teeth regardless of gender, tooth type and age of the patient.

The most common relationship was that cement and enamel abutted each other with no overlap, no significant differences were observed as

compared to the situation when the cement overlapped the enamel. In contrast, the mentioned cases of CEJ were significantly more distributed than the other two types, i.e. when there was a gap between the cement and the enamel and when the enamel overlapped the cement.

DISCUSSION

Cement-enamel border has been studied using a variety of methods such as microscopy (2), scanning electron microscopy (6), morphogens and embryonic analysis (7,8). Since Choquet (9) in 1899 first described the four mutual relationships between the cement and enamel in CEJ region, all of these methods were used for the classification, which includes the following relationships: 1. The cement overlaps the enamel, 2. The enamel overlaps the cement, 3. The enamel and cement abut each other with no overlap, and 4. There is a space between the enamel and cement, with exposed dentin in-between.

In our study, using the light microscopy, we confirmed the existence of all relationships between the cement and enamel as described by Choquet (9). However, some researchers were unable to find the relationship when the enamel overlaps the cement (10).

Roa et al. (5) reported the four relationships between the cement and enamel that was described by Choquet in a sample of 68 teeth (9). In their findings, 51.9% of the cases described the relationship when the cement and enamel were in contact, whereas 42.4% of the cases showed that the enamel overlapped the cement.

Our findings also showed that the two most common relationships between the cement and enamel were when the cement and enamel were in contact (36.7%), and when the cement overlapped the enamel (33.3%).

We determined that the presence of the relationship when the enamel overlapped the cement accounted for 13.3%, which was similar to the distribution of cases when the enamel and cement were not in contact (16.7%). In the latter case, we observed the exposed dentin, demineralization, cervical and root caries.

The importance of CEJ in periodontics and restorative odontology is increasing with aging of an

individual (11,12). The neck region of the tooth was mostly investigated for cervical and radicular caries, increased sensitivity of the teeth and the frequent occurrence of cervical erosion (13,14). Young people are increasingly using refreshing drinks which contain acidic and erosive components. In the case of the unfavorable relationship of the cement and enamel, the exposed dentin is a subject to demineralization and erosion.

Furthermore, in addition to diverse chemical and physical factors present in the oral environment, improper brushing of teeth may disturb the morphology of CEJ causing the exposure of dentin (2).

The ratio of cement and enamel varies, not only between individuals but also between the types of teeth from the same person, even in different sections of the same tooth. Our sample consisted of teeth extracted from females and males of various ages and from both jaws, as one previous study already showed that age of patients, as well as the jaw of extracted tooth, do not significantly influence the results (2).

The findings of this study showed a substantial proportion (16.7%) of cases when the exposed dentine was present in the region of the neck of the tooth. Therefore, we recommend that certain clinical procedures, such as the placement of hooks and metal prosthetics covers, removal of stones and concretions, and particularly whitening of teeth, should be carefully performed.

CONCLUSION

This study showed that the cement-enamel border is an important anatomical structure of the tooth with different morphological variations. Therefore, it has substantial importance for the proper implementation of certain dental procedures that take place in the region of the neck of the tooth and for the appropriate brushing of teeth. Otherwise, the morphology of CEJ may be violated, with the occurrence of increased tooth sensitivity to physical and chemical agents as well as to the development of pathological processes in the neck of the tooth.

References

1. Madhusudan A, Prabhpreet K, Nidhi D, Jappreet S. Comparison of hard tissue interrelationships at the cervical region of teeth based on tooth type and gender difference. *J Forensic Dent Sci* 2014; 6: 86–91.
<http://dx.doi.org/10.4103/0975-1475.132531>
2. Arambawatta K, Peiris R, Nanayakkara D. Morphology of the cemento-enamel junction in premolar teeth. *J Oral Sci* 2009; 51: 623–7.
<http://dx.doi.org/10.2334/josnusd.51.623>
3. Hu H, Hof M, Spanauf A, Renggli H. Validity of clinical assessments related to the Cemento-enamel junction. *J Dent Res* 1983; 62: 825–9.
<http://dx.doi.org/10.1177/00220345830620071301>
4. Francischone LA, Consolaro A. Morphology of the cemento-enamel junction of primary teeth. *J Dent Child (Chic)* 2008; 75: 252–9.
5. Roa I, del Sol M, Cuevas J. Morphology of the Cement-Enamel Junction (CEJ), Clinical Correlations. *Int J Morphol* 2013; 31: 894–8.
<http://dx.doi.org/10.4067/S0717-95022013000300018>
6. Neuvald L, Consolaro A. Cemento-enamel junction: microscopic analysis and external cervical resorption. *J Endod* 2000; 26: 503–8.
<http://dx.doi.org/10.1097/00004770-200009000-00004>
7. Owens P. The root surface in human teeth: a microradiographic study. *J Anat* 1976; 122: 389–401.
8. Bosshardt DD, Schroeder HE. Cementogenesis reviewed: a comparison between human premolars and rodent molars. *Anat Rec* 1996; 245: 267–92.
[http://dx.doi.org/10.1002/\(SICI\)1097-0185\(199606\)245:2<267::AID-AR12>3.0.CO;2-N](http://dx.doi.org/10.1002/(SICI)1097-0185(199606)245:2<267::AID-AR12>3.0.CO;2-N)
9. Choquet J. Note sur les rapports anatomiques existant chez l'homme entre l'émail et le ciment. *L'Odontologie* 1899; 8: 115–25.
10. Gómez De Ferraris ME, Campos Muñoz A. Histología, Embriología e Ingeniería tisular bucodental. In: *Histología, Embriología e Ingeniería Tisular Bucodental*. 3ra ed. Medica Panamericana, Mexico, 2009: 1–13.
11. Vandana KL, Haneet RK. Cemento-enamel junction: An insight. *J Indian Soc Periodontol* 2014; 18: 549–54.
<http://dx.doi.org/10.4103/0972-124X.142437>
12. Berkovitz BKB, Holland GR, Moxham BJ. A colour atlas and text of oral anatomy, histology and embryology. 2nd ed. Wolfe, London, 1992.
13. Beck JD, Hunt RJ, Hand JS, Field HM. Prevalence of root and coronal caries in non institutionalized older population. *J Am Dent Assoc* 1985; 111: 964–7.
<http://dx.doi.org/10.14219/jada.archive.1985.0242>
14. Schroeder HE, Scherle W. Cemento-enamel junction revisited. *J Periodontol Res* 1998; 23: 53–9.
<http://dx.doi.org/10.1111/j.1600-0765.1988.tb01027.x>

Morfološke varijacije cementno gleđnog spoja kod zuba stalne denticije

Nenad Stošić¹, Stefan Dačić², Dragica Dačić-Simonović²

¹Univerzitet u Nišu, Medicinski fakultet, Niš, Srbija

²Odeljenje za restorativnu stomatologiju i endodonciju, Klinika za stomatologiju, Niš, Srbija

SAŽETAK

Cementno gleđni spoj (cemento-enamel junction - CEJ) predstavlja važnu anatomsku strukturu koja se nalazi u vratnom delu zuba na mestu dodira gleđi koja prekriva dentin krunice i cementa koji prekriva dentin korena zuba. Četiri moguće veze između dva mineralizovana tkiva koja čine CEJ opisuju se na sledeći način: cement prekriva gleđ, gleđ prekriva cement, gleđ i cement se dodiruju linijski i gleđ i cement se ne dodiruju.

Cilj ovog istraživanja bio je da se utvrdi međudodnos gleđi i cementa u nivou CEJ kod različitih vrsta stalnih zuba.

Materijal je činilo 30 stalnih zuba sa očuvanim CEJ. Za bojenje tkiva u nivou CEJ korišćena je metilen plava. Nakon bojenja, vršeno je ispiranje zuba pod mlazom vode i sušenje na sobnoj temperaturi. Svaki zub je uzdužno presecan u vestibularno-oralnom pravcu. Posmatranje CEJ je sprovedeno svetlosnim mikroskopom Leica na uvećanju x10, a fotografisanje korišćenjem Nikon kamere.

Rezultati ove studije su pokazali da je najzastupljeniji odnos tkiva u nivou CEJ dodir gleđi i cementa u 36,7% slučajeva. Cement je prekrivao gleđ u 33,3%; gleđ i cement se nisu dodirivali u 16,7% i gleđ je prekrivala cement u 13,3% slučajeva.

Zbog morfološke raznolikosti CEJ neophodno je pažljivo izvođenje različitih stomatoloških intervencija u vratnom regionu zuba, jer u suprotnom može doći do promene njene morfologije, pojave patoloških procesa i pojačane osetljivosti zuba.

Ključne reči: cementno gleđni spoj, cement, gleđ