



Case report

Testicular Microlithiasis: Case Report and Literature Review

Goran Savić¹, Vladimir Vasić¹, Milan Petrović², Jovan Petrović²,
Dragoslav Bašić³, Jovan Hadži-Đokić⁴

¹*Zvezdara University Medical Center, Department of Urology, Belgrade, Serbia*

²*General Hospital Leskovac, Department of Urology, Leskovac, Serbia*

³*Clinical Center Niš, Clinic of Urology, Niš, Serbia*

⁴*Serbian Academy of Sciences and Arts, Belgrade, Serbia*

SUMMARY

Testicular microlithiasis is a condition characterized by the ultrasonographic findings with multiple microliths, with the prevalence of 0.6% to 9%. This is a condition of unknown etiology; however, in many cases it may be associated with cryptorchidism, Klinefelter syndrome, Down syndrome, varicocele, testicular torsion and male pseudohermaphroditism. Many retrospective studies point to the association between testicular microlithiasis and testicular cancer.

We report a case of a 50-year-old patient who presented to the urologist because of dysuric symptoms. Ultrasonographic examination of both testicles revealed microcalcifications in large numbers, i.e. "the phenomenon of the starry sky". More than 20 microcalcifications were present on the cross section of both testicles. Standard laboratory blood tests were normal. Prostate-specific antigen was 1.22 ng/ml. If risk factors for developing cancer are present, some authors recommend a biopsy of the testicles. However, based on the literature review, currently, there is no a strictly defined protocol.

Key words: testicle, microlithiasis, tumor

Corresponding author:

Vladimir Vasić

Email:vladimirdrvasic@gmail.com

INTRODUCTION

Testicular microlithiasis (TM) is a condition characterized by the ultrasonographic findings with multiple microliths, with the prevalence of 0.6% to 9%. Calcium deposits are formed in the lumen or on the components of the basement membrane of seminiferous tubules. Testicular microlithiasis is marked as limited (LTM) if the screen image shows less than five microcalculi. If the sonographic findings reveal more than five microliths, TM is described as classical (CTM). This is a condition of unknown etiology, but in many cases it may be associated with cryptorchidism, Klinefelter syndrome, Down syndrome, varicocele, testicular torsion and male pseudohermaphroditism. Diagnosing of testicular microlithiasis has increased in the past few years due to technological advances and raising awareness about the disease.

Usually, it occurs as an incidental finding without symptoms. Many retrospective studies point to the association between TM and testicular cancer. However, there is no consensus on whether TM can be considered a precancerous lesion.

CASE REPORT

We report a case of a 50-year-old patient who presented to the urologist because of dysuric symptoms. In the case history, surgery or chronic illnesses was not mentioned. The patient presented with the general type of obesity. Physical examination showed both testicles in the regular position in the scrotum, with correct dimensions, of homogeneous consistency; on palpation, they were painless. Both epididymises were without pathological deformities. Ultrasonographic examination of both testicles revealed microcalcifications in large numbers, i.e. "the phenomenon of the starry sky". More than 20 microcalcifications were present on the cross section of both testicles (Figure 1 and 2).

Dimensions of the testicles were 3.4 x 2.8 cm (right) and 3.2 x 2.7 cm (left). Standard laboratory blood tests were normal. Urinalysis was normal, while urine culture was sterile. Prostate-specific antigen was 1.22 ng/ml. The results of the semen analysis were within the reference values.

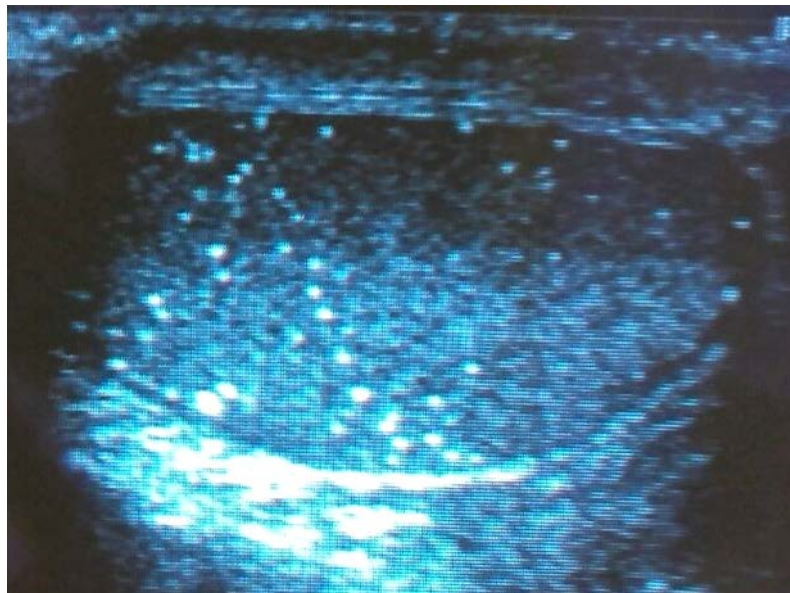


Figure 1. Ultrasonography examination revealed microcalcifications in large numbers, i.e. "the phenomenon of the starry sky"

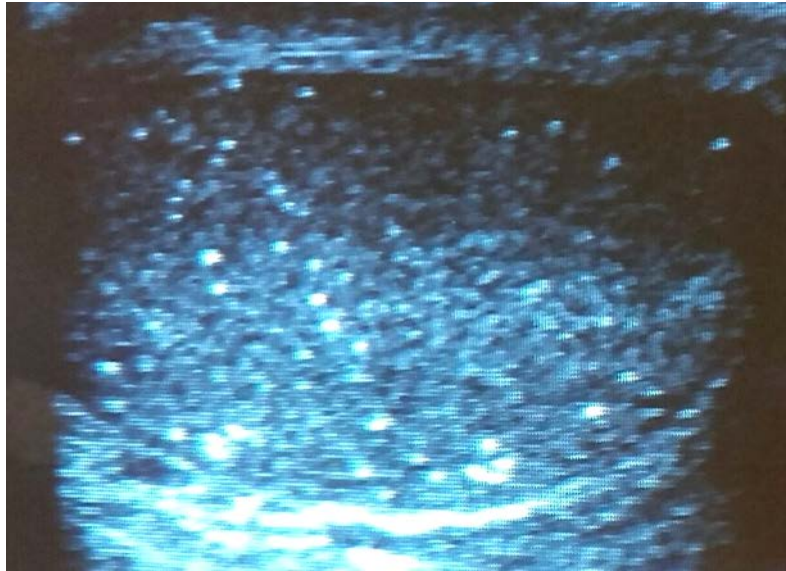


Figure 2. More than 20 microcalcifications were present on the cross-section of both testicles

DISCUSSION

Based on the former research, the prevalence of TM cannot be determined, but several published studies indicate the prevalence of 0.6% to 9% in symptomatic patients. Hobart and al. (1) point out that the prevalence of TM in patients who underwent ultrasonography due to a variety of scrotum symptoms was 0.6%, while Yee and colleagues (2) suggest that the incidence was 6% in adults and children. Results of some studies do not determine the relationship between testicular microlithiasis and the risk of testicular cancer evolving. Previous studies have shown an increase in the prevalence of testicular tumors in patients with TM. It has not been elucidated yet in which way TM influences the growth of testicular cancer. Testicular microlithiasis is in most cases an accidental finding detected by ultrasonography of the scrotum. Ringdahl (3) noted that in patients with scrotum symptoms and TM, the prevalence of testicular cancer is 8% compared to patients without symptoms in whom the prevalence is 2%. Lam et al. (4) discussed TM at the moment of the ultrasound examination of the scrotum in patients with testicular tumor and risk factors for the development of cancer such as contralateral testicular tumor, testicular atrophy and cryptorchidism. Skryme (5) noticed the development of testicular cancer in patients who were followed up for the pre-existing TM. Nevertheless, this study did not present statistically significant results that show an increased risk of cancer in patients with microlithiasis compared to patients with normal ultrasound findings. According to several studies (8-10), there is an increased risk for the development of the testicular germ cell tumor in patients with testicular microlithiasis but in the presence of other risk factors.

Barchetti and colleagues (9) showed the association between TM and extragonadal germ cell tumor. Their study shows the great importance of the annual scrotal ultrasound examination in patients with TM, in whom the extragonadal tumor of the retroperitoneum was surgically removed. Some authors indicate the need for an annual ultrasound examination of the scrotum and retroperitoneum in patients with TM as an incidental finding. Lee (10) noticed an association between paratesticular cellular angiofibroma, rare benign mesenchymal tumor and testicular microlithiasis. The study points to the possibility of a genetic mechanism that would be common for these diseases, but such claim requires further examination. Janzen et al. (11) showed that 37% of cases with TM were associated with cryptorchidism in the population of prepubertal male patients. Radiological studies (12, 13) suggest a follow-up of the patients with testicular microlithiasis associated with cryptorchidism, testicular atrophy, contralateral testicular tumor and with a family history of testicular cancer. Most authors emphasize the need for training patients with testicular microlithiasis to do self-examination, the need for regular annual physical examinations, determination of tumor markers, as well as annual ultrasound examination. However, there is no consensus on the period during which the patient should be followed up.

CONCLUSION

If the risk factors for developing cancer are present, some authors recommend a biopsy of the testicles. However, currently, based on the literature review there is no a strictly defined protocol.

References

1. Hobarth K, Susani M, Szabo N, Kratzik C. Incidence of testicular microlithiasis. *Europ Urology* 2000; 40:464–7.
[https://doi.org/10.1016/0090-4295\(92\)90467-B](https://doi.org/10.1016/0090-4295(92)90467-B)
2. Yee WS, Kim YS, Kim SJ, Choi JB, Kim SI, Ahn HS. Testicular microlithiasis: prevalence and clinical significance in a population referred for scrotal ultrasonography. *Korean J Urol* 2011;52:172-7.
<https://doi.org/10.4111/kju.2011.52.3.172>
3. Ringdahl E, Claybrook K, Teague L, Northrup M. Testicular microlithiasis and its relation to testicular cancer on ultrasound findings of symptomatic men. *J Urol* 2004; 172:1904–6.
<https://doi.org/10.1097/01.ju.0000142449.47356.29>
4. Lam DL, Gerscovich EO, Kuo MC, McGahan JP. Testicular microlithiasis: our experience of 10 years. *J Ultrasound Med* 2007;26:867-73.
<https://doi.org/10.7863/jum.2007.26.7.867>
5. Skyrme RJ, Fenn NJ, Jones AR, Bowsher WG. Testicular microlithiasis in a UK population: its incidence, associations and follow-up. *BJU Int* 2000; 86:482–5.
<https://doi.org/10.1046/j.1464-410X.2000.00786.x>
6. Coffey J, Huddart RA, Elliott F, et al. Testicular microlithiasis as a familial risk factor for testicular germ cell tumour. *Br J Cancer* 2007;97:1701-6.
<https://doi.org/10.1038/sj.bjc.6604060>
7. Miller FN, Rosairo S, Clarke JL, Sriprasad S, Muir GH, Sidhu PS. Testicular calcification and microlithiasis: association with primary intra-testicular malignancy in 3477 patients. *EurRadiol* 2007;17:363-9.
<https://doi.org/10.1007/s00330-006-0296-0>
8. Tan I, Ching B, Toh C, Tan M. Testicular Microlithiasis Predicts Concurrent Testicular Germ Cell Tumors and Intratubular Germ Cell Neoplasia of Unclassified Type in Adults A Meta-Analysis and Systematic Review, *Cancer*2010;116(19): 4520-32.
9. Barchetti F, De Marco V, Barchetti G, Pasqualitto E, Sartori A, Glorioso M, Gigli S, Megna V, Montechiarlo S, Boncore V, Stagnitti A. Incidental Discovery of Testicular Microlithiasis: What Is the Importance of Ultrasound Surveillance? Two Case Reports. *Case Rep Oncol* 2013;6:520-5
<https://doi.org/10.1159/000356097>
10. Lee S, Choi HJ. Double Para-testicular Cellular Angiofibroma and Synchronous Testicular Microlithiasis. *JPTM* 2016; 50(1):75-7.
11. Sharma S, Manchanda V, Gupta R. Testicular microlithiasis in a unilateral undescended testis: a rare phenomenon. *Malaysian J Pathol* 2013; 35(2):181-3
12. Shetty D, Bailey AG, Freeman SJ. Testicular microlithiasis an ultrasound dilemma: survey of opinions regarding significance and management amongst UK ultrasound practitioners. *Br J Radiol* 2014;87:20130603.
<https://doi.org/10.1259/bjr.20130603>
13. Bennett HF, Middleton WD, Bullock AD, Teefey SA. Testicular microlithiasis: US follow up. *Radiology* 2001; 218: 359–63
<https://doi.org/10.1148/radiology.218.2.r01fe25359>

Mikrolitijaza testisa: prikaz slučaja sa osvrtom na literaturu

Goran Savić¹, Vladimir Vasić¹, Milan Petrović², Jovan Petrović²,
Dragoslav Bašić³, Jovan Hadži-Đokić⁴

¹Univerzitetski medicinski centar Zvezdara, Odeljenje za urologiju, Beograd, Srbija

²Opšta bolnica Leskovac, Odeljenje za urologiju, Leskovac, Srbija

³Klinički centar Niš, Klinika za urologiju, Niš, Srbija

⁴Srpska akademija nauka i umetnosti, Beograd, Srbija

SAŽETAK

Mikrolitijaza testisa je stanje koje se na ultrasonografskom nalazu karakteriše multiplim mikrolitima, sa prevalencijom od 0,6% do 9%. Nejasne je etiologije, ali u velikom broju slučajeva može biti udružena sa kriptorhizmom, Klinefelterovim sindromom, Daunovim sindromom, varikocelom, torzijom testisa i muškim pseudo-hermafroditizmom. Mnoge retrospektivne studije ukazuju na povezanost mikrolitijaze testisa i karcinoma testisa.

Prikazujemo slučaj pedesetogodišnjeg bolesnika koji se javlja urologu zbog dizuričnih smetnji. Na ultrasonografskom pregledu u oba testisa se uočavaju mikrokalifikacije u velikom broju, tzv. "fenomen zvezdanog neba." Na poprečnom preseku oba testisa uočeno je više od 20 mikrokalifikacija. Kompletna krvna slika i biohemijske analize bile su u referentnim okvirima. Specifični antigen prostate iznosio je 1,22 ng/ml.

Ukoliko postoje faktor irizika za razvoj karcinoma, neki autori preporučuju biopsiju testisa. Međutim, za sada, na osnovu pregleda literature ne postoji jasno utvrđen protokol.

Ključnereči: testis, mikrolitijaza, tumor