

Review article

Pelvic Ring Injuries

Saša Milenković^{1,2}, Milan Mitković^{1,2}

¹University of Niš, Faculty of Medicine, Niš, Serbia

²Orthopaedic and Traumatology Clinic, Clinical Centre Niš, Niš, Serbia

SUMMARY

Pelvis is a strong bony-ligamentous structure containing many organs, vessels and nerves. Three forces or a combination of those forces produce pelvic fractures. The main causes of pelvic fractures are traffic accidents and falls from height. Biomechanically pelvic ring can be stable or unstable. Biomechanically unstable pelvic ring after the injury may provoke hemodynamic instability. Mortality rate in hemodynamically unstable patients with pelvic fractures remains high. Hemodynamically unstable patients require urgent closing of the pelvic volume with pelvic C clamps or external fixator. This fixation is usually temporary. The massive venous bleeding from the injured pelvis needs the pelvic packing (tamponade); arterial bleeding needs angiography and embolization. After a patient's hemodynamic status stabilizes, further evaluation and mechanical stabilization of the pelvis is needed. The definitive stabilization of the pelvis includes hemodynamically stable patients and implies anterior, posterior or both anterior and posterior pelvic ring fixation. The main indication for the anterior stabilization is symphyseal diastasis greater than 2,5 cm. Anterior stabilization can be achieved with external fixator or with symphyseal plating. The primary indication for surgery of posterior pelvic ring complex is vertical pelvic instability. Stable mechanical fixation can be applied with anterior sacro-iliac plating, percutaneous ilio-sacral screws, and trans-iliac sacral bars. Inadequate treatment of pelvic injury may cause permanent disability and serious chronic disorders.

Key words: pelvic ring, injuries, surgical treatment

Corresponding author:

Saša Milenković

E-mail: sasaortoped@gmail.com

INTRODUCTION

Pelvic ring injuries are generally caused by the high energy trauma, traffic accidents or occur after falls from heights. Pelvic injuries can be isolated or associated with other orthopedic injuries or other organ injuries (urinary system, reproductive system, bowel system, soft tissues, arteries, veins, nerves). In polytrauma patients, pelvic injuries are not rare. Complex pelvic trauma still represents a life-threatening injury for the patient, particularly in polytrauma (1-3). Patients with pelvic injuries can be hemodynamically unstable or stable. Biomechanical instability of the pelvic ring may provoke hemodynamic instability because the disrupted pelvic ring leads to damage to many vessels of the pelvis and sacral bones. Hemodynamically unstable patients with pelvic ring injuries require urgent and immediate treatment, with the aim of general health status stabilization and saving the patient's life. Control and cessation of bleeding in hemodynamically unstable patients is achieved with the pelvic clamp, external fixation, pelvic tamponade or embolization. Fixation of pelvic ring in emergencies is generally temporary and it is achieved with external fixation or by pelvic C clamps (4, 5). After stabilization of the general health status, it is necessary to perform a stable pelvic ring fixation and restore the patient to prehospital activity (6).

Anatomy of the pelvis

The pelvis is a ring made up of three bones: the sacrum and two innominate bones. The innominate bones articulate with the sacrum through the sacroiliac joints and between themselves through symphysis pubis. They are joined by important ligamentous structures. The sacroiliac joints are stabilized by anterior sacroiliac ligament, posterior sacroiliac ligament, and interosseous ligament. The pubic symphysis is reinforced by fibrocartilage and a series of thin ligaments. The posterior sacroiliac ligament is the main vertical stabilizer of the pelvic ring. The pelvic floor is supported by sacrospinous and sacrotuberous ligaments (7).

The mechanism of injury

Three major forces or their combination can produce pelvic ring injuries. Lateral compression injury (LC) leads to lateral compression and internal

rotation of hemipelvis, which are often the results of side-impact motor-car or automobile-pedestrian accidents. Anteroposterior compression (APC) leads to the external rotation of the injured hemipelvis. A vertical shear (VS) injury leads to cephalad dislocation of the hemipelvis and usually occurs after fall from heights. A combined mechanism of injury (CMI) is a combination of the previously mentioned forces (7).

Classification of pelvic injuries

The Tile classification is based on the stability of the pelvic ring and mechanism of injury (Figure 1). Type A injuries include the pelvic ring fractures that do not compromise the stability of the pelvic ring. These fractures are stable. Type B injuries involve the pelvic ring in two or more sites and create rotationally unstable but vertically stable fractures. The posterior sacroiliac complex remains stable. Type C injuries are both rotationally and vertically unstable fractures. The posterior sacroiliac complex is completely disrupted (anterior and posterior sacro-iliac ligaments). The Tile classification serves as the AO/OTA classification.

The Young-Burgess classification is based on the mechanism of injury and force patterns according to increasing levels of energy applied to fractures of the pelvic ring and the result is associated with the risk of hemodynamic instability. APC I injuries have symphyseal diastasis less than 2,5 cm. Posterior pelvic ring complex remains intact. APC II injuries are characterized by symphyseal diastasis greater than 2,5 cm. APC III injuries are defined as a vertically unstable pelvic ring, including complete disruption of the posterior ligamentous complex.

LC I injuries consist of a spectrum of posterior compression injuries of the sacroiliac joint. LC II injuries accompany the rupture of the posterior sacroiliac ligament with internal rotation of the hemipelvis around the axis of the anterior sacroiliac joint. LC III injuries involve the findings of an LC II with APC injury to the contralateral side. VS injuries are associated with disruption of all major ligaments and characterized by vertical dislocation of the injured hemipelvis. The combined mechanism of injury is a combination of the previous forces (7-10).

Initial treatment

Initial evaluation of the injured patients include the identification of life-threatening conditions, including the pelvic and associated injury. Mortality

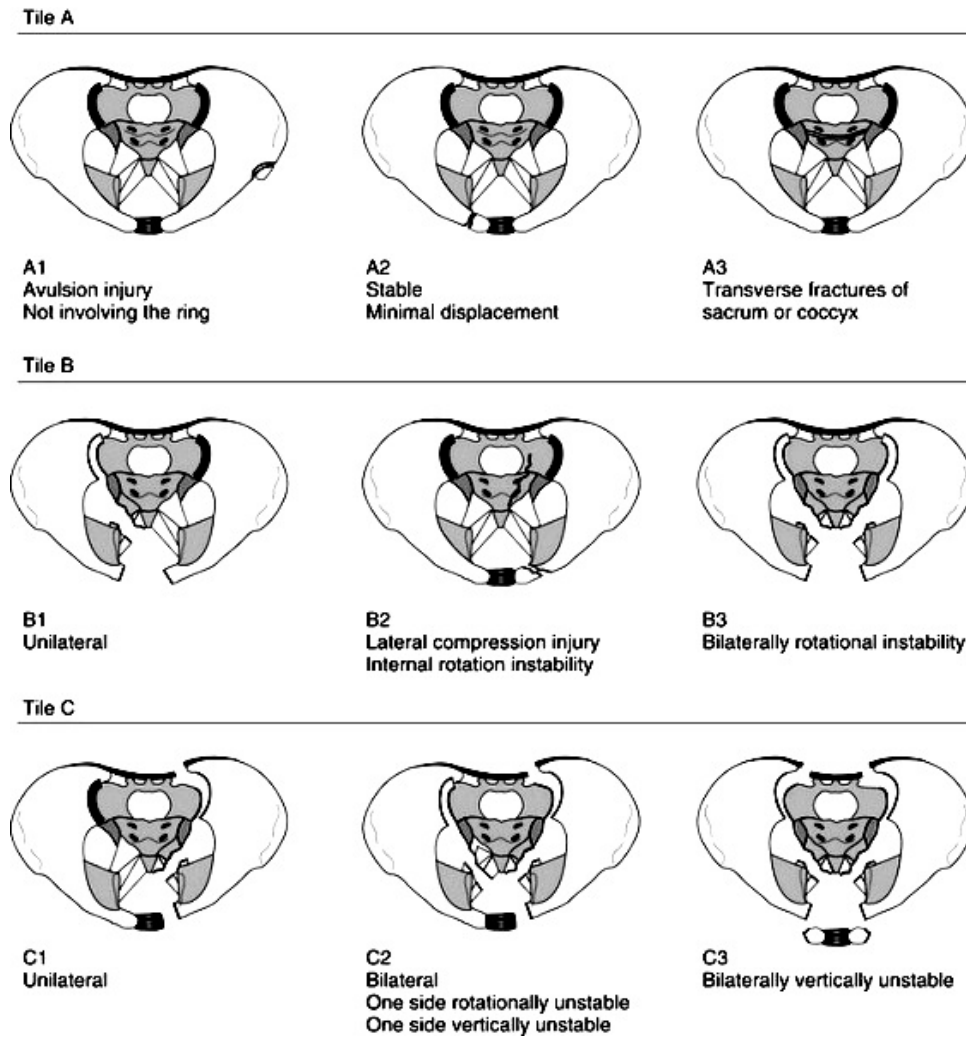


Figure 1. Marvin Tile classification of pelvic injuries (Tile M. Acute pelvic fractures: I. Causation and classification. *J Am Acad Orthop Surg* 1996; 4 (3): 143-51.)

rate of hemodynamically unstable patients remains high (11, 12). The major causes of mortality are early exsanguinations and the late sequel of prolonged shock and mass transfusion (13). Identification of the sources of hemorrhage is critical. In all trauma patients, the Advanced Trauma Life Support (ATLS) protocol should be followed.

Physical examination is useful to detect injuries and should identify open wounds in the perineum or anterior pelvis, subcutaneous injuries, perineal and scrotal ecchymosis, as well as neurological injuries (14). In hemodynamic abnormality, emergency plain AP pelvic radiograph should be obtained in the emergency department as well as abdominal ultrasound examination. Indices of hemodynamic status should

be noted, including tachycardia, increased base deficit, increased lactate level, blood pressure lower than 90 mm Hg, and need for transfusion. CT scan and additional radiographic (Inlet, Outlet) examination should be balanced against risk in hemodynamically unstable patients (Figure 2). In cases with dislocated pelvic fractures, a urethral and bladder injury should be suspected and retrograde urethrogram or cystogram should be performed (7, 15, 16). The emergency treatment protocol includes closing of the pelvic volume with external fixator or pelvic C clamps with or without pelvic tamponade (pelvic packing) (Figure 3). External fixation and pelvic C clamps are temporary methods of pelvic fixation (Figure 4) (16-21).

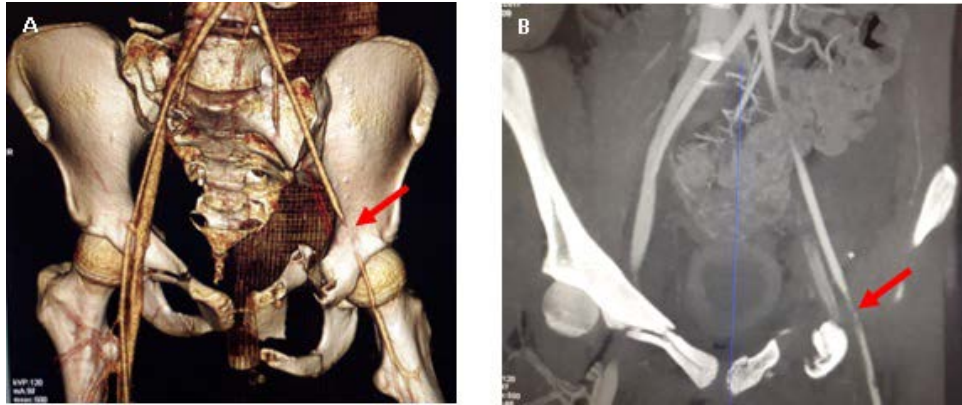


Figure 2. (A, B) An injury of the femoral artery caused by an unstable pelvic fracture

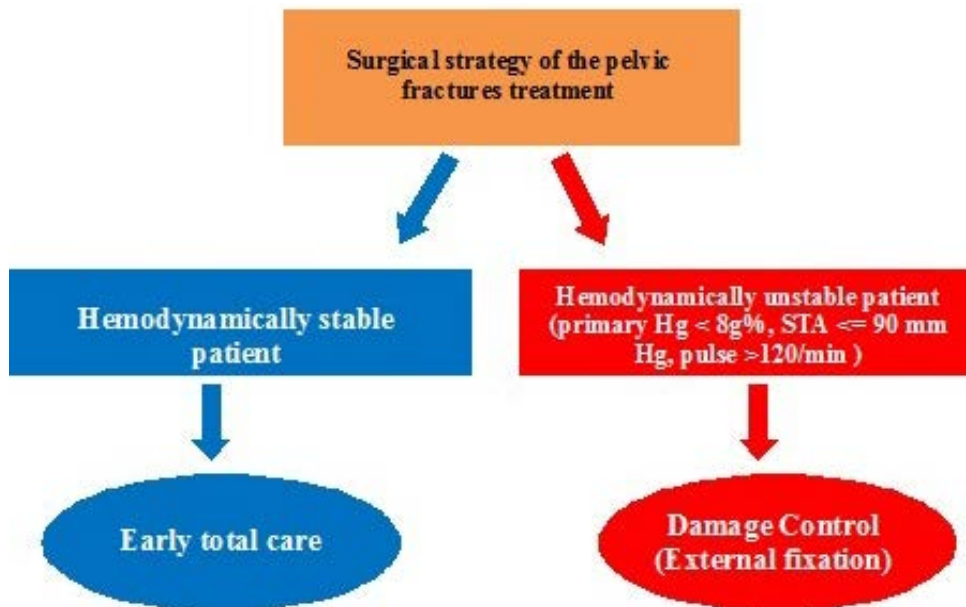


Figure 3. Surgical strategy of the pelvic fractures treatment

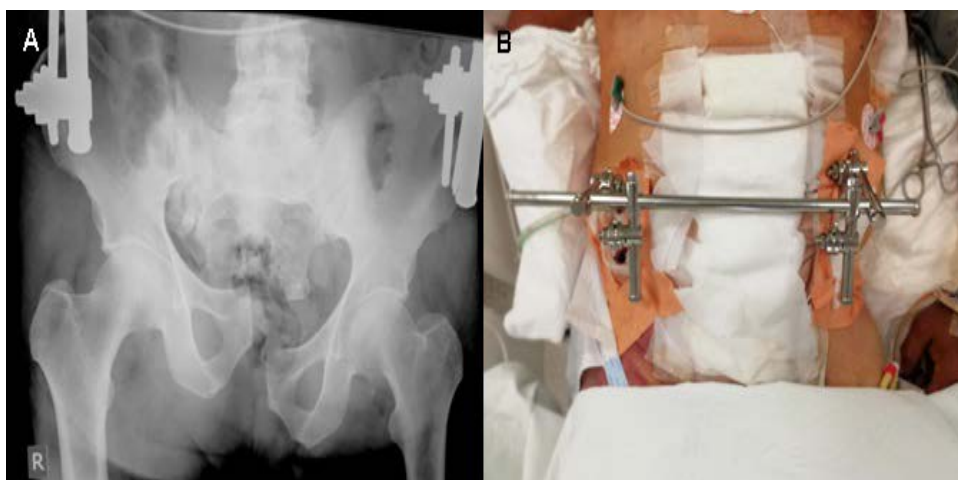


Figure 4. (A, B) Temporary external fixation of the type C pelvic ring injury in the polytraumatized patient with external fixation method using external fixator according to Mitković

Definitive treatment

The main indication for surgery of anterior pelvic ring injuries include symphyseal diastasis greater than 2,5 cm. Biomechanical studies have shown no significant clinically beneficial difference between anterior external or internal fixation of the anterior pelvic ring complex (22, 23). However, anterior internal fixation is superior to external fixation in resisting vertical displacement of the hemipelvis. The current method consists of a four or

six hole symphyseal plate with 3,5 mm or 4,5 mm cortical screws on each side of the symphysis (Figure 5).

The primary indications for surgical treatment of posterior pelvic ring complex injuries include type C pelvic injury according to Tile classification. Posterior stabilization can be achieved with posterior sacral plate, posterior sacral bars, anterior sacroiliac plates, and percutaneous screw(s) fixation of the sacroiliac joint (Figure 6-8) (24).

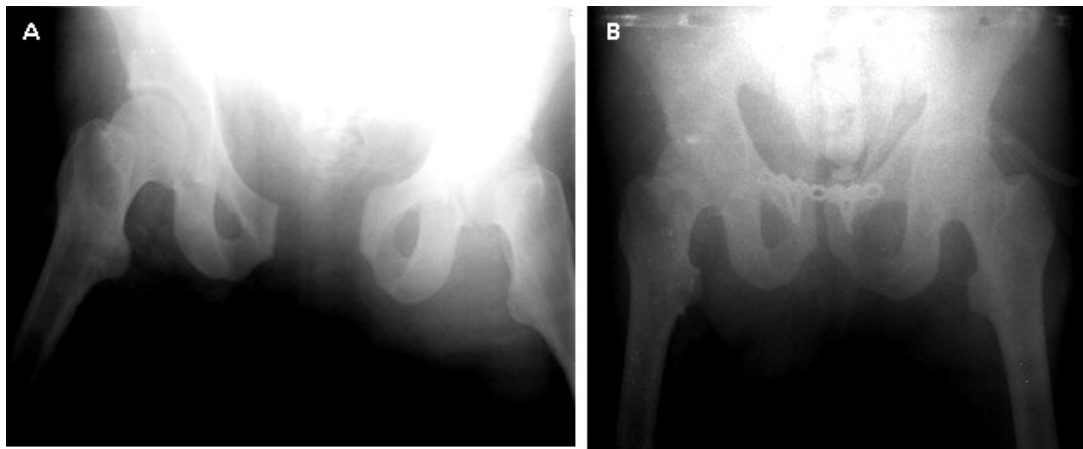


Figure 5. (A, B) Type B pelvic ring injury treated by open reduction and internal fixation of the anterior pelvic ring complex (pubic symphysis)

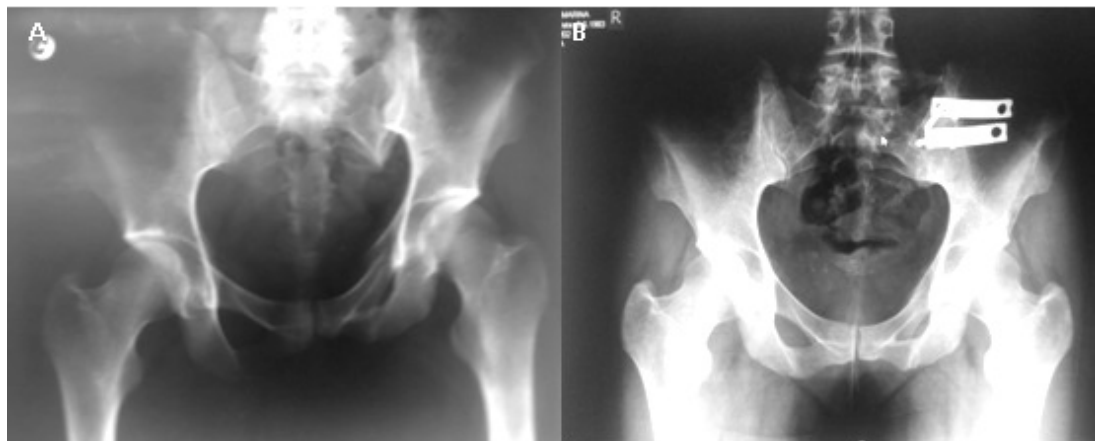


Figure 6. (A, B) Open reduction and internal fixation of the posterior pelvic ring complex (Sacro-iliac joint dislocation)

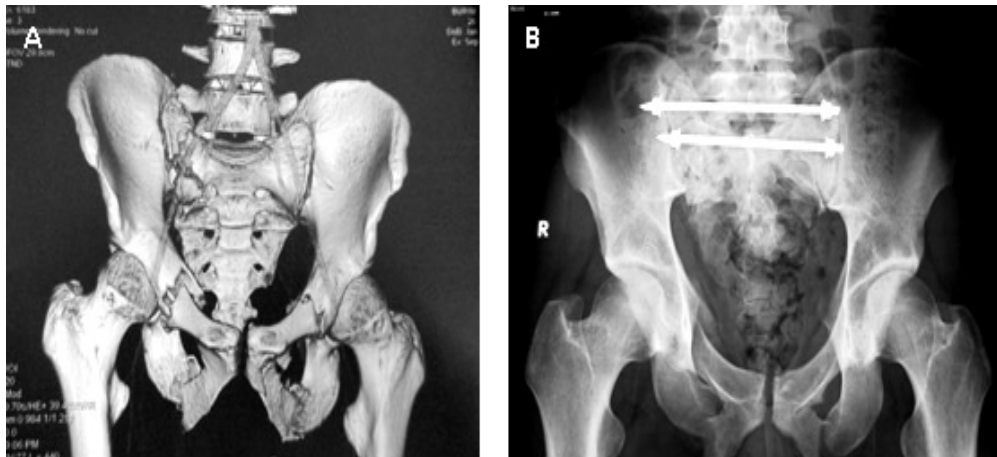


Figure 7. (A, B) Unstable type C pelvic injury (anterior pubic fractures, posterior vertical sacral fracture) treated with posterior fixation using the sacral bars

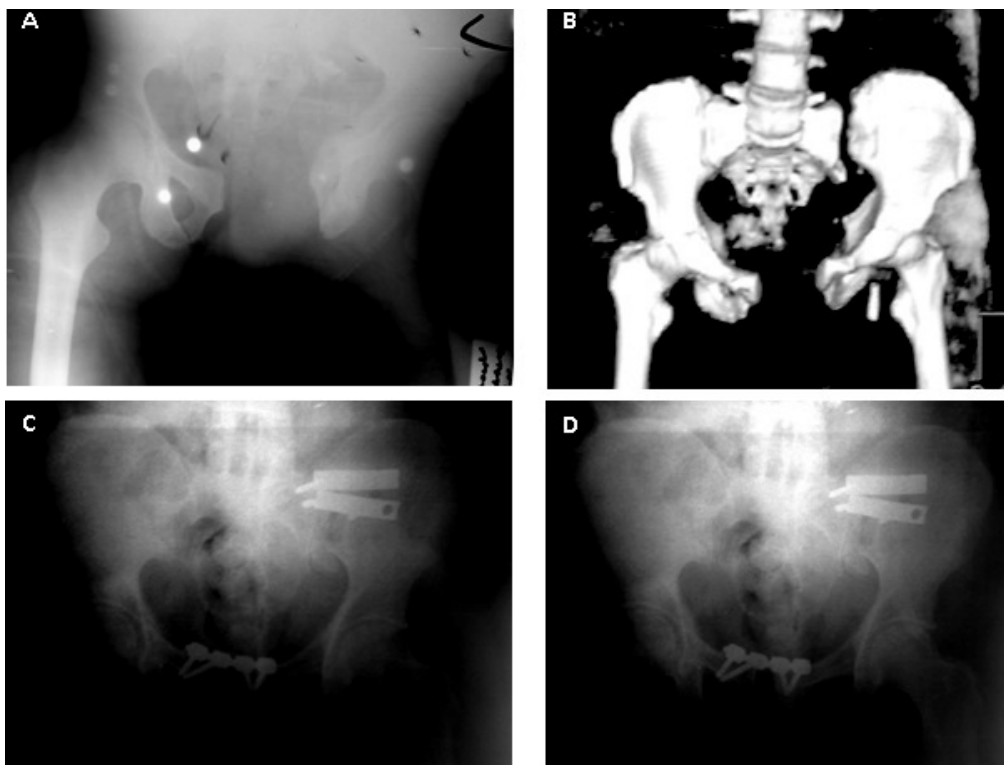


Figure 8. (A, B, C, D) Unstable type C pelvic ring injury treated by open reduction and internal fixation of both- anterior and posterior pelvic ring complex (anterior- pubic symphysis, posterior- sacro-iliac)

Complications

Surgery for pelvic fracture can be associated with large blood losses, serious intraoperative hemorrhage, deep vein thrombosis, pulmonary embolism, postoperative wound infection, dehiscence, postoperative neurologic deficit, and postoperative loss of

fixation and reduction (24- 31). Prophylaxis of venous thromboembolism with low molecular weight heparins should be started within 12 to 24 hours of the pelvic injury during four to six weeks. Aspirin and elastic stockings are inadequate discharge thromboprophylaxis for trauma patients (24).

DISCUSSION

Pelvic ring injuries are very severe and complex, requiring treatment in highly specialized institutions and multidisciplinary team approach involving orthopaedic surgeons, especially in polytrauma. In addition to emergency, blood transfusion, external fixation of the pelvic ring and tamponade are the methods which can reduce pelvis volume, stop the bleeding and stabilize general health status in hemodynamically unstable patients with bleeding. In many cases, tamponade is not necessary and it is sufficient to perform transfusion and external fixation of the pelvic ring (32). Temporary stabilization of the unstable pelvic ring using pelvic C clamps is described in the literature. External fixation is a good method for polytraumatized patients to achieve fracture stabilization, decreasing bony motion and reduced pelvic volume (33-35). Disadvantage of external fixators are that they do not provide posterior stability and can potentially increase pelvic deformity in the pelvis with vertically unstable injuries (Type C) (36). Skeletal traction of the affected side may be necessary to reduce the unstable hemipelvis. Skeletal traction, as a definitive method for the treatment of type C pelvic injuries, and external fixation are unfortunately still used in some hospitals in Serbia. In this treatment, patients are confined to bed, which increases the possibility for complications and high rate of nonunions and malunions. Patients with nonunions and malunions have permanent disability and severe health problems (urogenital disorders, back pain, gastrointestinal disturbances, problems with sitting, standing, walking). The primary goal in the treatment of pelvic ring injuries is to achieve fracture healing in excellent or good anatomical position and to achieve excellent or good functional results. Due to all these facts, it can be considered that these injuries need to be treated in highly specialized institutions using a multidisciplinary team approach. In hemodynam-

ically stable patients, the method of choice is the definitive fixation of anterior or both anterior and posterior pelvic ring complex (type B and C injuries) (6, 37). Definitive stabilization of the pelvic ring should be obtained as early as possible, preferably within the first seven days after the initial trauma (4). The sacroiliac joint disruption can be treated using anterior or posterior approach. After the reduction of the dislocated sacroiliac joint, stable fixation can be applied with anterior plating or with percutaneous iliosacral screws and posterior transiliac sacral bars. In the vertical sacral fractures, the method of posterior plating or posterior traniliac sacral bars can be used (16, 38, 39). External fixator by Mitković is a good option for anterior fixation of the unstable pelvic ring (temporary in polytrauma patients or definitive stabilization in the type B pelvic injury) (21). Pins can be applied to the iliac crest under direct palpation without fluoroscopy or placing the pins supra-acetabularly with fluoroscopic imaging. Biomechanical studies show that supra-acetabular pin placement has greater rigidity, but in an emergency, iliac crest placement is quicker. Pelvic ring injuries encompass a wide spectrum of injuries associated with visceral and neurologic injuries. According to the literature sources, fewer than 50% of patients with severe pelvic fractures return to the previous activity (40).

CONCLUSION

Pelvic ring injuries encompass a wide spectrum of injuries, from low-energy pubic fractures to high-energy pelvic fractures. Unstable hemodynamic patients with biomechanically unstable pelvic ring need emergency stabilization with external fixation or with pelvic C clamps. Hemodynamically stable patients need definitive stabilization and fixation of the anterior pelvic ring complex (type B injury) or of both anterior and posterior pelvic ring complex (type C injury).

References

1. John T, Ertel W. Pelvic injuries in the polytraumatized patient. *Orthopäde* 2005; 34(9):917-30.
<https://doi.org/10.1007/s00132-005-0860-3>
2. Culemann U, Oestern HJ, Pohlemann T. Current treatment of pelvic ring fractures. *Chirurg* 2013; 84(9):809-26.
<https://doi.org/10.1007/s00104-012-2391-x>
3. Culemann U, Tosounidis G, Reilmann H, Pohlemann T. Injury to the pelvic ring. Diagnosis and current possibilities for treatment. *Unfallchirurg* 2004; 107(12):1169-81.
4. Tile M. Pelvic ring fractures: Should they be fixed? *J Bone Joint Surg [Br]* 1988; 70-B (1):1-12.
<https://doi.org/10.1302/0301-620X.70B1.3276697>
5. Burkhardt M, Culemann U, Seekamp A, Pohlemann T. Strategies for surgical treatment of multiple trauma including pelvic fracture. Review of the literature. *Unfallchirurg* 2005; 108(10):812-20.
<https://doi.org/10.1007/s00113-005-0997-x>
6. Milenkovic S, Mitkovic M, Saveski J, et al. Surgical treatment of unstable type C pelvic injury. *Acta Chir Iugosl* 2013; 60(2):53-8.
<https://doi.org/10.2298/ACI1302053M>
7. Smith WR, Suzuki T, Tornetta III P. Pelvic fractures: evaluation and acute management. In: *Orthopaedic knowledge update: Trauma 4*. Edited by Schmidt AH, Teague DC. American Academy of Orthopaedic Surgeons (AAOS); 2010. p. 279- 92.
8. Starr AJ, Malekzadeh AS. Fractures of the pelvic ring. In: *Rockwood & Green's Fractures in Adults*, 6th edition. Edited by Bucholz RW, Heckman JD, Court-Brown CM. Lippincott Williams & Wilkins; 2006. p. 1585-684.
9. Tile M. Acute pelvic fractures: I. Causation and classification. *J Am Acad Orthop Surg* 1996; 4(3): 143-51.
<https://doi.org/10.5435/00124635-199605000-00004>
10. Lefavre KA, Padelecki JR, Starr AJ. What constitutes a Young and Burgess lateral compression- I (OTA 61- B2) pelvic ring disruption A description of computed tomography- based fracture anatomy and associated injuries. *J Orthop Trauma* 2009; 23(1): 16- 21.
<https://doi.org/10.1097/BOT.0b013e31818f8a81>
11. Olson SA, Burgess A. Classification and initial management of patients with unstable pelvic ring injuries. *Instr Course Lect* 2005; 54: 383-93.
12. BiffL WL, Smith WR, Moore EE, et al. Evolution of a multidisciplinary clinical pathway for the management of unstable patients with pelvic fractures. *Ann Surg* 2001; 233 (6): 843-50.
<https://doi.org/10.1097/0000658-200106000-00015>
13. Smith W, Williams A, Agudelo J, et al. Early predictors of mortality in hemodynamically unstable pelvic fractures. *J Orthop Trauma* 2007; 21 (1): 31-7.
<https://doi.org/10.1097/BOT.0b013e31802ea951>
14. McCormick JP, Morgan SJ, Smith WR. Clinical effectiveness of physical examination in diagnosis of posterior pelvic ring injuries. *J Orthop Trauma* 2003; 17 (4): 257- 61.
<https://doi.org/10.1097/00005131-200304000-00003>
15. Milenković S, Mitković BM, Bašić D, et al. Urinary tract injury associated with pelvic fractures. *Acta Chir Iugosl* 2014; 61(1): 9-15.
<https://doi.org/10.2298/ACI1401009M>
16. Milenković S. Fractures of the pelvis and acetabulum. Monography. Medical faculty of Niš; Niš. 2018.

17. Milenković S, Mitković M, Soldatović G, et al. External fixation in polytrauma patients. *Eur J Trauma* 2004; (Suppl 1) 30: S 161.
18. Mitković M, Milenković S, Micić I, Mitković MM. External fixation in skeletal trauma in 21st century. *Eur J Trauma*. 2010; (Suppl 1) 36:S 245-6.
19. Mitković M, Milenković S, Micić I, Mitković MM. Results of application of Mitkovic external fixation system on 25 thousand traumatology and orthopaedic patients. International scientific-practical conference "Ilizarov readings 2016". Abstract book; 462- 464. Kurgan, Russia. 2016.
20. Mitković M, Milenković S, Micić I, Mitković M. Biomechanical investigation and clinical application of new external fixation system. German Congress of Orthopaedics and Traumatology (DKOU 2015). Meeting Abstract; 30: 788; Berlin. 2015.
21. Mitković M, Milenković S, Micić I, et al. External skeletal fixation as temporarily method in damage control. When and where external fixation can be definitive method of fracture treatment? *Eur J Trauma Emerg Surg* 2016; (Suppl 2) 42: S69.
22. Stocks GW, Gabel GT, Noble PC, et al. Anterior and posterior internal fixation of vertical shear of the pelvis. *J Orthop Res* 1991; 19 (2): 237-45. <https://doi.org/10.1002/jor.1100090212>
23. Vrahas M, Hern TC, Diangelo D, et al. Ligamentous contributions to pelvic stability. *Orthopedics* 1995; 18 (3): 271-4.
24. Sagi HC, Jimenez M. Pelvic fractures: definitive treatment and expected outcomes. In: *Orthopaedic knowledge update: Trauma 4*. Edited by Schmidt AH, Teague DC. American Academy of Orthopaedic Surgeons (AAOS); 2010. p. 293-307.
25. Stannard JP, Lopez-Ben RR, Volgas DA, et al. Prophylaxis against deep-vein thrombosis following trauma: A prospective, randomized comparison of mechanical and pharmacologic prophylaxis. *J Bone Joint Surg [Am]* 2006; 88 (2): 261-6. <https://doi.org/10.2106/JBJS.D.02932>
26. Stannard JP, Singhania AK, Lopez-Ben RR, et al. Deep vein thrombosis in high-energy skeletal trauma despite thromboprophylaxis. *J Bone Joint Surg [Br]* 2005; 87 (7): 965-8. <https://doi.org/10.1302/0301-620X.87B7.15989>
27. PREPIC Study Group. Eight-year follow-up of patients with permanent vena cava filters in the prevention of pulmonary embolism: The Prepic (Prevention du Risque d'Embolie Pulmonaire par Interruption Cave) randomized study. *Circulation* 2005; 112 (3): 416-22. <https://doi.org/10.1161/CIRCULATIONAHA.104.512834>
28. Dove AF, Poon WS, Weston PAM. Haemorrhage from pelvic fractures: dangers and treatments. *Injury* 1982; 13 (5): 375-81. [https://doi.org/10.1016/0020-1383\(82\)90088-2](https://doi.org/10.1016/0020-1383(82)90088-2)
29. Evers BM, Cryer HM, Miller FB. Pelvic fracture hemorrhage. Priorities in management. *Arch Surg* 1989; 124: 422-4. <https://doi.org/10.1001/archsurg.1989.01410040032006>
30. Fleming WH, Bowen JC III. Control of hemorrhage in pelvic crush injuries. *J Trauma* 1973; 13 (6): 567-70. <https://doi.org/10.1097/00005373-197306000-00013>
31. Gordon RL, Fast A, Aner H, Shifrin E, et al. Control of massive retroperitoneal bleeding associated with pelvic fractures by angiographic embolization. *Isr J Med Sci* 1983; 19: 185-8.
32. Scaglione M, Parchi P, Digrandi G, et al. External fixation in pelvic fractures. *Musculoskelet Surg* 2010; 94 (2): 63-70. <https://doi.org/10.1007/s12306-010-0084-5>
33. Tiemann AH, Schmidt C, Gonschorek O, Josten C. Use of the "C- clamp" in the emergency treatment of unstable pelvic fractures. *Zentralbl Chir* 2004; 129 (4): 245-51. <https://doi.org/10.1055/s-2004-822833>
34. Heini PF, Witt J, Ganz R. The pelvic C- clamp for the emergency treatment of unstable pelvic ring injuries. A report on clinical experience of 30 cases. *Injury* 1996; (Suppl 1) 27: S 38-45.

[https://doi.org/10.1016/S0020-1383\(96\)90110-2](https://doi.org/10.1016/S0020-1383(96)90110-2)

35. Pohlemann T, Culemann U, Gänsslen A, Tscherne H. Severe pelvic injury with mass hemorrhage: determining severity of hemorrhage and clinical experience with emergency stabilization. *Unfallchirurg* 1996; 99 (10): 734-43.
<https://doi.org/10.1007/s001130050049>
36. Dickson KF, Matta JM. Skeletal deformity after anterior external fixation of the pelvis. *J Orthop Trauma* 2009; 23 (5): 327-32.
<https://doi.org/10.1097/BOT.0b013e3181a23f5b>
37. Milenković S, Kocić M, Mitković BM, et al. Nestabilne povrede karličnog prstena- značaj hirurške stabilizacije i rehabilitacije na krajnje funkcionalne rezultate. *Balneoclimatologija* 2016; 40 (2): 225-9.
38. Yinger K, Scalise J, Olson SA, et al. Biomechanical comparison of posterior pelvic ring fixation. *J Orthop Trauma* 2003; 17 (7): 481-7.
<https://doi.org/10.1097/00005131-200308000-00002>
39. Keating JF, Werier J, Blachut P, et al. Early fixation of the vertically unstable pelvis: the role of iliosacral screw fixation of the posterior lesion. *J Orthop Trauma* 1999; 13(2): 107- 13.
<https://doi.org/10.1097/00005131-199902000-00007>
40. Oliver CW, Twaddle B, Agel J, Routt MLJr. Outcome after pelvic ring fractures: Evaluation using the medical outcomes short SF- 36. *Injury* 1996; 27(9): 635- 41.
[https://doi.org/10.1016/S0020-1383\(96\)00100-3](https://doi.org/10.1016/S0020-1383(96)00100-3)

Povrede karličnog prstena

Saša Milenković^{1,2}, Milan Mitković^{1,2}

¹Univerzitet u Nišu, Medicinski fakultet, Niš, Srbija

²Klinika za ortopediju i traumatologiju, Klinički Centar Niš, Niš, Srbija

SAŽETAK

Karlica je jaka koštano-ligamentarna struktura koja sadrži mnoge organe, krvne sudove i nerve. Tri sile, ili njihova kombinacija, izazivaju prelome karlice. Glavni uzrok preloma karlice su saobraćajni udesi ili pad sa visine. Biomehanički, karlični prsten može biti stabilan ili nestabilan. Biomehanički nestabilan karlični prsten može da provocira hemodinamsku nestabilnost. Stopa mortaliteta kod hemodinamski nestabilnih bolesnika sa prelomima karlice ostaje visoka. Hemodinamski nestabilni bolesnici zahtevaju hitno zatvaranje karličnog volumena pomoću karlične C kleme ili pomoću spoljašnjeg fiksatora. Ovakva fiksacija obično je privremena. Masivna venska krvarenja iz povređene karlice zahtevaju tamponadu karlice, dok arterijsko krvarenje zahteva angiografiju i embolizaciju. Po stabilizaciji hemodinamskog statusa bolesnika, dalja evaluacija podrazumeva mehaničku stabilizaciju karlice. Definitivna stabilizacija karlice uključuje hemodinamski stabilnog bolesnika i podrazumeva prednju ili zadnju fiksaciju ili i prednju i zadnju fiksaciju karličnog kompleksa. Glavna indikacija za to da je potrebno izvršiti prednju stabilizaciju je dijastaza pubične simfize za više od 2,5 cm. Prednja stabilizacija postiže se spoljašnjom fiksacijom ili simfizealnim pločama. Primarna indikacija za to da je potrebno uraditi zadnju stabilizaciju karličnog kompleksa je vertikalna nestabilnost karlice. Stabilna mehanička fiksacija može se postići prednjim sakro-ilijačnim pločama, perkutanom iliosakralnim zavrtnjima i transilijačnim sakralnim barovima. Neadekvatan tretman povreda karlice može da izazove trajnu invalidnost i ozbiljne hronične poremećaje.

Ključne reči: karlični prsten, povrede, hirurško lečenje