

Case report

Prosthetic Rehabilitation of Geriatric Patients: A Case Report

Maja Anđelković¹, Nikola Gligorijević^{1,2}, Milena Kostić^{1,2}

¹Dental Clinic Niš, Department for prosthodontics, Niš, Serbia

²University in Niš, Faculty of Medicine, Niš, Serbia

SUMMARY

Introduction. Tooth loss and changes in tooth structure affect the quality of life of patients both from the aspect of orofacial health and general health as well.

Case report. Lack of teeth reduces the ability to chew and swallow food, which significantly disrupts the function of the digestive system. Less pleasing appearance and speech disorders affect the patient's psychological status and quality of social life.

Conclusion. Elderly patients represent a specific category to which special attention should be paid when solving the problem of edentulousness

Key words: edentulism, elderly , complete denture, prosthodontics

Corresponding author:

Nikola Gligorijević

e-mail: dr.gligorijevicnikola@gmail.com

ORAL MANIFESTATIONS OF ELDERLY PATIENTS

Aging is a natural and physiological process that progresses differently but indisputably in humans. Although life expectancy has significantly increased with the development of medicine and better living conditions, the population that is considered to be older are people over the age of 65. Their role in society is still proactive, and analysis shows that they could even make up to a quarter of the world's total population (1). Therefore, it is of crucial importance to invest maximum effort in preserving the general and oral health of elderly patients, which, in addition to medical, also achieves an enviable socio-economic benefit.

With aging, numerous changes occur in the patient's mouth, caused by atrophy, degeneration and disease development of oral tissues, or as a consequence of various systemic diseases. Gerontostomatology is an interdisciplinary science that deals with the study of both healthy, as well as prevention and treatment of diseased orofacial system in geriatric patients.

Systemic diseases can lead to a number of changes in the geriatric population: varicose veins, discoloration, vulnerability and atrophy of the oral mucosa, increased susceptibility to infections and immune diseases (Pemphigus, Pemphigoid, Lichen planus, Sjogren's syndrome), deposits and changes in the tongue, glossitis, Papillitis, Stomatopyrosis and Stomatodynia, Xerostomia and neurological changes (atypical orofacial pain). It should also be mentioned that the use of prescription drugs used in therapy of both chronic and acute diseases can significantly change the oral flora, and in combination with xerostomia cause infections of the oral cavity (1, 2).

Changes in the orofacial system caused by aging are changes in dental tissue (pulp withdrawal by formation of secondary and tertiary dentin, abrasion, attrition and erosion of teeth), changes in periodontal tissue (almost always signs of periodontitis), changes in masticatory keratinized mucosa and tongue. These changes may cause a change in food taste, decreased salivation, changes in the composition of biological plaque and consecutive opportunistic infections (3).

Tooth loss causes permanent damage to the structures of the orofacial system. Prosthodontic prevention consists of timely production of high-quality

dentures in order to minimize changes in the oral mucosa and temporomandibular joints, thus preventing further damage and rehabilitating the functions of the orofacial system. The production of dentures enables chewing, swallowing and speech, restores a harmonious appearance to the patient and improves their quality of life (4).

Studies have shown that a large number of elderly patients are edentulous (5, 6). The complete lack of teeth makes it impossible for the patient to chew food and speak. The height of the lower third of the face decreases, the lips are pulled into the oral cavity, and fungal deposits are formed on the commissures of the lips, which cause Cheilitis angularis. With a reduction in the distance between the jaws, the wrinkles on the face and around the lips are more prominent, leading to an aging appearance which reduces the patient's self-confidence. All of the above affects the mental health and social life of the patient, isolating him from society and reducing his working ability (7).

THE AIM

The aim of this paper was to point out the specifics of producing complete dentures in geriatric patients through a case report.

SPECIFICS OF MAKING COMPLETE DENTURES FOR GERIATRIC PATIENTS

In the treatment of geriatric patients with complete dentures, it is necessary to make maximum effort in order to ensure optimum retention and stability and achieve satisfactory aesthetic effects of the dentures. They should be comfortable while in use and have the possibility of easily maintaining their hygiene, as well as oral hygiene in general (4).

The success of future therapy is influenced by the health of the structures of the orofacial system. Complete dentures compensate for lost natural teeth and the resorbed part of the alveolar ridge. Retention and stability of complete dentures depends on the supporting tissues that are supposed to hold the prosthesis in the patient's mouth. In the upper jaw, the supporting tissue is the hard palate, the maxillary alveolar ridge and the area that extends buccally from the ridge to the relatively mobile mucosa. By secondary compression of the described supporting tissues, masticatory pressure is transferred to the supporting tissues of the maxillary complete den-

ture. The supporting tissues of the mandibular complete denture is the mandibular alveolar ridge and soft tissues up to the area of relatively mobile mucosa. Retention and stabilization of the mandibular complete denture difficult to achieve due to the small surface of the supporting tissue, the proximity of the tongue, and difficulty in achieving a neutral muscular position (1).

One of the main challenges in making complete dentures is primarily the alveolar ridge, which is often uneven, with exostoses and unevenly resorbed. The described effects are usually a consequence of non-simultaneous tooth loss, as well as incorrect repositioning of bone lamellae after extraction. The appearance of duplications of the mucous membrane is most often associated with the use of inadequate old dentures. Frenulum and plica insertion at the very top of the alveolar ridge is the result of advanced atrophy and resorption of the alveolar ridge due to patient's not wearing dentures, and it significantly impacts retention and stabilization of the dentures. The mucous membrane of the alveolar ridge is often ischemic, vulnerable and thin, which can be attributed to the aging process. White deposits often appear on the tongue, and the gustatory papillae are often atrophied. The appearance of macroglossia, the spread of the tongue between the alveolar ridges of the upper and lower jaw in order to raise the bite, as well as infantile type of swallowing should also not be neglected. Decreased bite height can affect the temporomandibular joints, so pain and crepitations are common, as well as uncoordinated neuromuscular movements of the mandible, which negatively affects therapy (1, 4).

Given their mental and physical condition, cooperation with elderly patients requires patience and understanding from the practitioner. Patients with reduced cognitive abilities and dementia, are more difficult for treatment, but they should not be excluded from prosthodontic therapeutic procedures. Attention should also be paid to neurological patients in whom it is more difficult to perform certain conventional work phases of making complete dentures (8, 9).

Geriatric patients have different expectations from prosthodontic therapy. In the past, total dentures were seen as a mean to restore functionality to the orofacial system, today it is very important to equally justify the aesthetic requirements of such prosthesis. Aesthetic standards of geriatric patients

are incomparably higher than those that were valid decades ago (9, 10).

By taking anamnestic data, a detailed clinical examination and establishing a diagnosis, each geriatric patient is approached individually, considering his wishes and needs. The justification of gerontoprosthodontics as a special branch of prosthodontics is in specific diagnostic and modified therapy procedures for elderly patients, whose number is undoubtedly growing.

CLINICAL CASE

A 78-year-old patient, slightly confused and dependent of someone else's care, contacted the Department of Prosthodontics at the Clinic of Dental Medicine in Niš, in order to make new complete dentures (Figure 1).

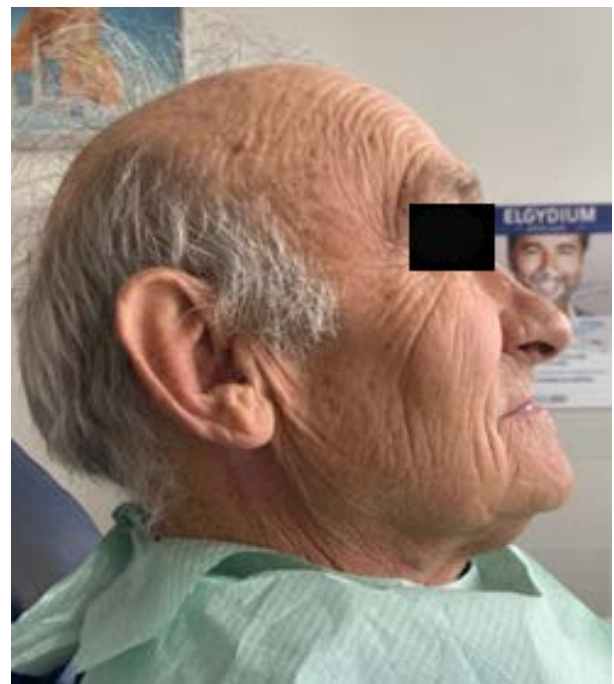

Figure 1. Edentulous geriatric patient's profile

He had difficulty moving and suffered from cervical arthritis, which caused pain in his neck. He stated in his anamnesis that he suffers from diabetes. He used his old dentures for 11 years, so he could no longer chew with them. The teeth in the denture were abraded which caused a reduction in the bite height. After interviewing the patient, and the completion of the extra and intraoral examination, he was offered a therapy plan consisting of the produc-

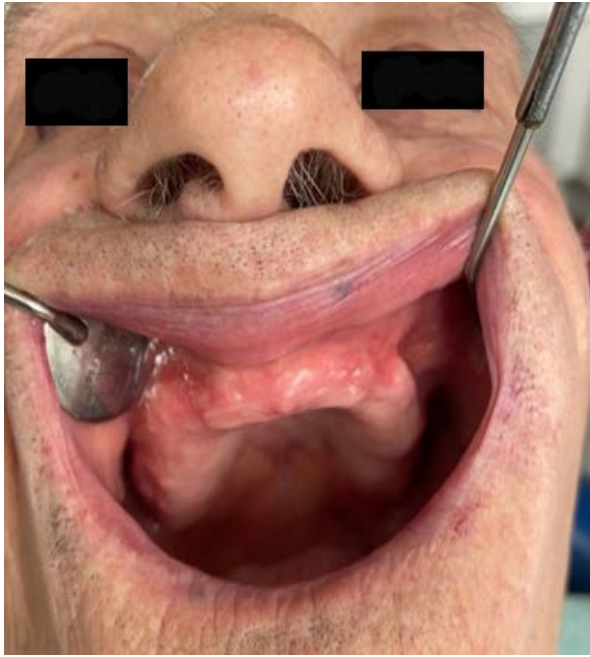

Figure 2. Uneven maxillary alveolar ridge

tion of both upper and lower denture (Figure 2).

The anatomical impression was taken with alginate using a standard tray (Alginplus, Major Prodotti Dentari, Italy). Borders for the individual tray were marked on the impression, which was transferred to the anatomical model. The custom tray was made using self-polymerizing acrylate (Duracrol, Spofa Dental, Czech Republic). After that, a functional impression was taken using a custom tray by utilizing a combination of compressive impression technique in the area of relatively mobile mucosa and acompressive for the immobile mucosa, followed by border molding, by which satisfactory retention and stabilization of future dentures was achieved (Cavex Outline, the Netherlands). Working models were made using hard stone on which upper and lower bite blocks were produced. The correct centric relationship between the upper and lower arch was determined. Bite blocks provided support to the lips and cheeks and an adequate vertical dimension of occlusion was established. The position of the occlusal plane was defined using extraoral parameters: bipupillary and Camper lines. The middle of the upper and lower dentition did not coincide with the medial line of the face, due to the visual asymmetry. Following the setting of the teeth, a clinical tryout phase was conducted. The patient was satisfied with the size, shape and color of the teeth. The patient wanted a lighter shade of teeth by his choice (Ivoclar Vivadent, Liechtenstein) (Figure 3).

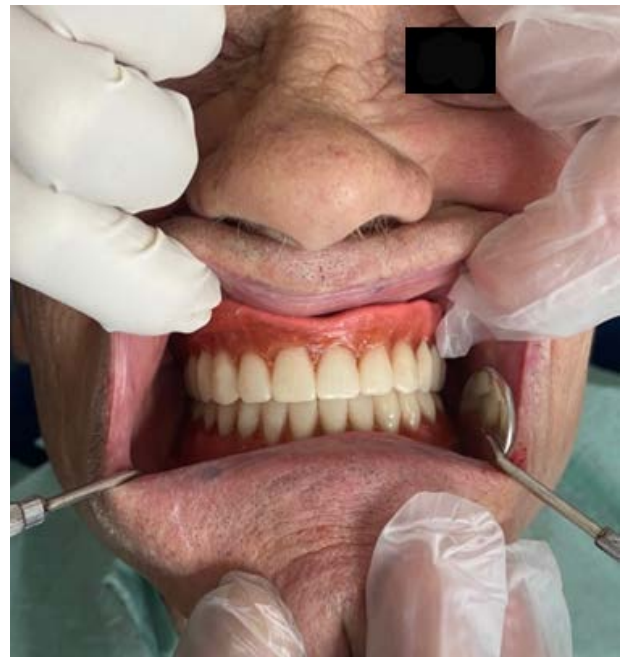


Figure 3. Teeth setting tryout after centric relation and vertical height determination

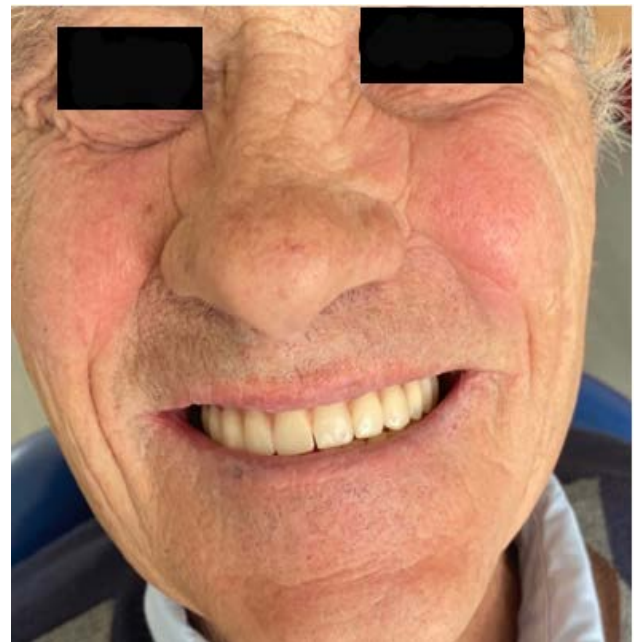

Figure 4. Satisfied patient after new complete denture fabrication

After soft tissue modeling followed by denture processing, the dentures were provided to the patient, and instructions for use were given. Retention and stabilization were optimal and the patient was satisfied with the therapeutic effect (Figure 4).

Denture corrections were made one, three and

seven days after providing them to the patient, and there was no significant damage to the mucous membrane in terms of erosions and ulcerations. The patient completely adapted and used them throughout the day. Wearing dentures while sleeping is not recommended for elderly patients due to the permanent pressure on the supporting tissues. The dentures should be placed in cold water with disinfectant overnight.

CONCLUSION

Given the increase in the number of older people, their needs in the field of dentistry must not be neglected. The goal of gerontostomatology is the study, prevention and treatment of diseases of the orofacial system in elderly patients and it is characterized by specifics in functional, aesthetic and prophylactic rehabilitation. Making complete dentures for geriatric patients provides a challenge to the practitioner, but as a result gives the patients the ability to chew, swallow and talk, to have a smile on their face and to live longer and more satisfied.

References

1. Tihaček Šojić Lj, Stančić I. Stomatološka gerontoprotetika. Koraci Kragujevac 2009.
2. Nitschke I, Wendland A, Weber S, Jockusch J, Lethaus B, Hahnel S. Considerations for the Prosthetic Dental Treatment of Geriatric Patients in Germany. *J Clin Med.* 2021;10(2):304. <https://doi.org/10.3390/jcm10020304>
3. Barbe AG, Schmidt P, Bussmann M, Kunter H, Noack MJ, Röhrig G. Xerostomia and hyposalivation in orthogeriatric patients with fall history and impact on oral health-related quality of life. *Clin Interv Aging.* 2018; 13:1971-9. <https://doi.org/10.2147/CIA.S178370>
4. Tihaček Šojić Lj, Stančić I, Jelenković A, Milić Lemić A. The possibilities of prosthetic rehabilitation of shortened dental arches in elderly patients. *Stom Glas S* 2008; 55: 238-46. <https://doi.org/10.2298/SGS0804238T>
5. Rivera-Hernandez M, Flores Cerqueda S, García Ramírez JC. The growth of gerontology and geriatrics in Mexico: Past, present, and future. *Gerontol Geriatr Educ.* 2017; 38(1):76-91. <https://doi.org/10.1080/02701960.2016.1247068>
6. Arai H, Ouchi Y, Yokode M, Ito H, Uematsu H, Eto F, Oshima S, Ota K, Saito Y, Sasaki H, Tsubota K, Fukuyama H, Honda Y, Iguchi A, Toba K, Hosoi T, Kita T; Members of Subcommittee for Aging. Toward the realization of a better aged society: messages from gerontology and geriatrics. *Geriatr Gerontol Int.* 2012; 12(1):16-22. <https://doi.org/10.1111/j.1447-0594.2011.00776.x>
7. Pantea M, Tancu AMC, Petre A, Imre M, Ionescu E.J. Elderly Patients' Perception of Previewing the Prosthetic Treatment Outcome. *Med Life.* 2020;13(1):82-6.
8. Schüler IM, Kurtz B, Heinrich-Weltzien R, Lehmann T, Kwetkat A. Testing the ability for autonomous oral hygiene in hospitalized geriatric patients-clinical validation study. *Clin Oral Investig.* 2021; 25(3):1059-68. <https://doi.org/10.1007/s00784-020-03402-5>

9. Weg RB. The backbone of academic gerontology: introduction. *Gerontol Geriatr Educ.* 1989; 9(4):1-7. https://doi.org/10.1300/J021v09n04_01
10. Tahani B, Khademi A, Fathollahi S. Status of geriatric education and meeting the standards of facilities in dental schools. *J Educ Health Promot.* 2019; 8:163. doi:10.4103/jehp.jehp_220_19 <https://pubmed.ncbi.nlm.nih.gov/31544128>

Protetska rehabilitacija gerijatrijskih bolesnika: prikaz slučaja

Maja Anđelković¹, Nikola Gligorijević^{1,2}, Milena Kostić^{1,2}

¹Klinika za dentalnu medicinu Niš, Služba za stomatološku protetiku, Niš, Srbija

²Univerzitet u Nišu, Medicinski fakultet, Niš, Srbija

SAŽETAK

Uvod. Gubitak zuba i promene na njihovim strukturama utiču na kvalitet života bolesnika, kako sa aspekta zdravlja orofacijalnog sistema, tako i opšteg zdravstvenog stanja.

Prikaz slučaja. Nedostatak zuba smanjuje sposobnost žvakanja i gutanja hrane što bitno remeti funkciju sistema organa za varenje. Narušen izgled bolesnika i smetnje u govoru utiču na njihov psihološki status i kvalitet socijalnog života.

Zaključak. Bolesnici strarije životne dobi predstavljaju specifičnu kategoriju, kojoj treba posvetiti posebnu pažnju prilikom rešavanja problema bezubosti.

Ključne reči: bezubost, gerijatrijski bolesnici, totalna zubna proteza, protetika