

Case report

A Rare Case of Coexistence of Cervical Lymph Node Metastasis of Papillary Thyroid Carcinoma and Cervical Ganglioneuroma: A Possibility of Radioiodine Refractory Thyroid Cancer Misdiagnosis

Katarina Vuleta Nedić¹, Vladimir R. Vukomanović¹, Ana Ranković², Vesna D. Ignjatović¹,
Svetlana Kocić³

¹University of Kragujevac, Faculty of Medical Sciences, Department for Nuclear Medicine, Kragujevac, Serbia

²University Clinical Center Kragujevac, Department of Radiology, Kragujevac, Serbia

³Department of Radiology, Clinical Hospital Center Zemun, Belgrade, Serbia

SUMMARY

Introduction. Well-differentiated thyroid cancer (DTC) is curable in most patients with adequate surgical approach, radioactive iodine (RAI) treatment, and thyroid-stimulating hormone (TSH) suppression. However, around 2% - 4% of cases experience a local recurrence in lateral cervical lymph nodes during a follow-up. Among these cases, nearly two-thirds become resistant to RAI therapy, known as RAI-refractory DTC (RR-DTC), offering poor prognosis and limited therapeutic options. We present the case of erroneously suspected RAI-refractory DTC due to incidental finding of coexisting cervical ganglioneuroma.

Case report. A 44-year-old man was administered the second radioiodine dose in our department due to the existence of locoregional metastatic lymph nodes of papillary thyroid carcinoma (PTC). During the follow up, raising tendency of suppressed serum thyroglobulin levels, negative control diagnostic ¹³¹I whole body scan, and negative ¹⁸F-fluorodeoxyglucose (FDG)-positron emission tomography scan (PET) aroused suspicion of RR-DTC. Although the patient was considered for peptide-receptor radionuclide therapy (PRRT) optionally, mainly because of positive finding in patient's neck on ^{99m}Tc-Hynic-TOC imaging (Tekrotyd scan), the preference was given to a surgical approach. Finally, histopathological examination of extirpated neck tumor mass confirmed the presence of one lymph node metastasis of papillary carcinoma and coexistence of ganglioneuroma.

Conclusion. The authors want to point out the importance of multidisciplinary approach in diagnostics and therapy in case of suspected loss of thyroid differentiation features, as well as clinical awareness of coexisting asymptomatic rare tumors.

Keywords: RAI therapy, RAI-refractory thyroid carcinoma, ganglioneuroma

Corresponding author:

Vesna D. Ignjatović

e-mail: vesnaivladaignjatovic@gmail.com

INTRODUCTION

Differentiated thyroid carcinoma (DTCs) including papillary, follicular, and Hürthle cell carcinoma account for 93% of all thyroid cancers (1). The main therapeutic modality for these tumors with a favorable outcome is surgery followed by the application of radioiodine (RAI) in patients with intermediate to high-risk features (2, 3). In most patients, this would be curative treatment, but according to Wang et al., recurrent disease is detected in lateral cervical lymph nodes in 2% - 4% of patients (4). In two thirds of these patients with progressive disease, due to the initial aggressive behavior or dedifferentiation of cancer cells, RAI-refractory thyroid disease is registered. There is no consistent definition of RAI-refractory thyroid cancers in literature. Considering individual criteria for radioiodine refractory thyroid disease, we can only consider the likelihood that a tumor will be RAI irresponsive (5, 6). It is very important to recognize this condition because of further therapeutic strategies that might be applied. The present case describes unexpected finding of cervical ganglioneuroma adjacent to papillary thyroid carcinoma lymph node metastasis with a possibility of imaging misinterpretation and consequently the inadequate selection of therapeutic approach.

CASE REPORT

A 44-year-old man was referred to our department for administration of a second dose of radioiodine due to elevated thyroglobulin levels (Tg) and detection of locoregional metastatic lymph

nodes of papillary thyroid carcinoma (PTC). A year before, he was diagnosed with PTC (pT3bN1bMx) and treated with total thyroidectomy and bilateral neck dissection, followed by ablation/adjutant therapy with 150 millicuries (mCi) of ^{131}I . After ultrasound-detected lymphadenopathy on the right side of the neck and increased thyroglobulin levels during the follow-up, the patient underwent regional and central re-dissection of the right side of the neck. Lymph nodes metastases of papillary thyroid carcinoma were identified, thus adjuvant radioiodine therapy was recommended. The second dose of 150 mCi of radioiodine (RAI) was administered and during two follow-ups, after three (Tg = 75 ng/ml) and six months (Tg = 267 ng/ml), the level of suppressed thyroglobulin dramatically increased. Diagnostic ^{131}I whole-body scan was made under endogenous stimulation following a 4-week thyroid hormone withdrawal (TSH > 30 uIU/ml) and there was no registered abnormal uptake of radioiodine. Taking into account also negative ultrasound of neck, the patient was referred to ^{18}F -fluorodeoxyglucose (FDG)-positron emission tomography (PET) computed tomography (CT) (^{18}F -FDG PET/CT) which showed no metabolically active lesions. In order to provide alternative therapeutic options to our patient with suspected RAI-refractory thyroid carcinoma, which was primarily related to peptide-receptor radionuclide therapy (PRRT), we conducted additional diagnostics $^{99\text{m}}\text{Tc}$ -Hynic-TOC imaging (Tektrotyd scan). Interestingly, a focal intense uptake of radiolabeled somatostatin analog was depicted (Krenning score 4) in the upper third of the left side

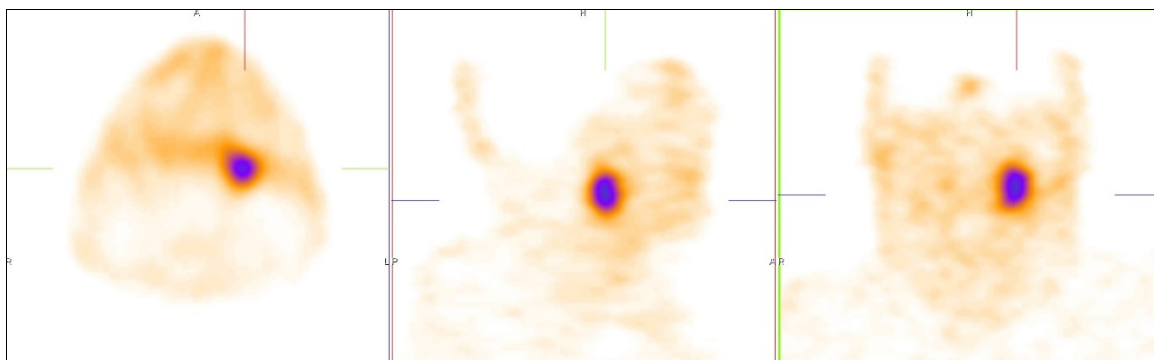


Figure 1. Transverse, sagittal, and coronal slice of the acquired SPECT, using $^{99\text{m}}\text{Tc}$ -Hynic-TOC

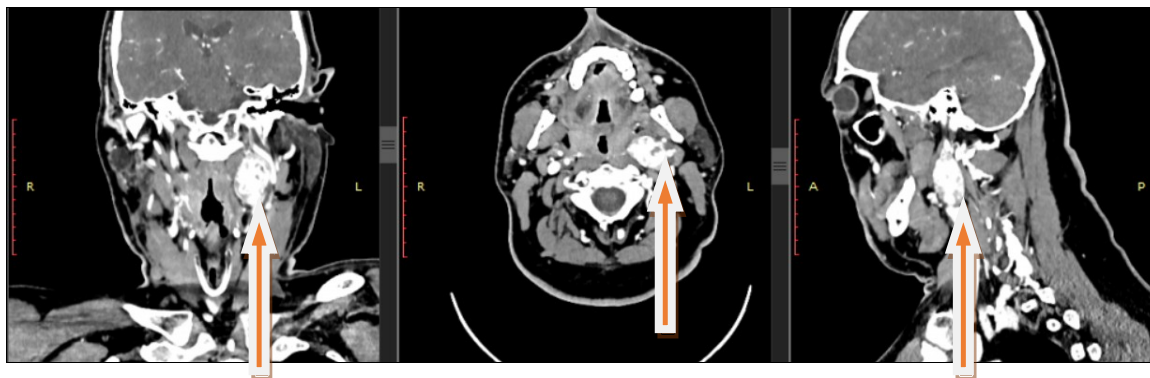


Figure 2. Coronal, axial, sagittal section on postcontrast CT examination

of the neck (Figure 1). Additionally, contrast-enhanced CT of neck showed hypervascular tumor lesion located in left carotid space at the level of the carotid bifurcation (Figure 2). Finally, neck tumor mass was extirpated and histopathological finding confirmed one lymph node metastasis of papillary carcinoma and coexistence of ganglioneuroma. Postoperative serum Tg level dropped significantly (Tg = 14 ng/ml).

DISCUSSION

Differentiated thyroid carcinoma (DTC) represents about 90% of all thyroid carcinomas with overall ten-year survival of approximating 95% (7). Isolated in thyroid gland or presented as regional disease, in most cases DTC is curable with adequate surgical approach followed by the administration of radioiodine in intermediate and high-risk patients (8). In 10% of DTC patients with distant metastasis (lungs in 50% and bone in 25% cases), 10-year overall survival is less than 50% (9). Two thirds of DTC patients with distant metastasis show decreased iodine-uptake with apparent loss of thyroid differentiation features and insensitiveness to adjuvant RAI treatment as well as standard cytotoxic chemotherapeutic agents (3).

RAI-refractoriness is characterized by the tumor inability to concentrate RAI, loss of prior iodine-avidity and ability of some affected tissues showing high RAI uptake while others do not. It may also involve disease progression despite RAI accumulation. However, a consistent definition of RAI-refractory DTC remains controversial. None of the mentioned criteria alone can be considered when making a decision to introduce another therapeutic option (10).

Numerous studies have shown the role of SSTR in the regulation of thyroid cell proliferation and reported that these receptors are expressed in both normal and thyroid disorders (11). According to these research findings, the most represented receptor subtypes in DTCs are SSTR2a and SSTR5 (12). The potential role of various radiolabeled somatostatin analogues for diagnostic and therapeutic purposes in RAI-refractory DTCs such as ^{111}In -octreotide, $^{99\text{m}}\text{Tc}$ -Hynic-TOC, ^{68}Ga -DOTA-TATE, ^{90}Y -DOTA-TOC and ^{177}Lu -DOTA-TATE relies on previous findings (11).

In this case, we wanted to consider the application of PRRT, due to limited therapeutic options in the treatment of de-differentiated thyroid carcinomas. According to Czepczyński and Matysiak-Grześ, PRRT in de-differentiated DTCs patients showed stabilization and partial remission of disease (13). After detection of focal uptake on $^{99\text{m}}\text{Tc}$ -Hynic-TOC scan in patient neck, which was supported by additional morphological information (contrast-enhanced neck CT), a board of physicians made a decision about further surgical treatment. Histopathological findings of extirpated neck tumor mass revealed a simultaneous presence of lymph node metastasis of papillary thyroid carcinoma and cervical ganglioneuroma. This eventually explained increasing of serum Tg level and simultaneous positive findings on $^{99\text{m}}\text{Tc}$ -Hynic-TOC scan.

An absence of RAI uptake of papillary thyroid carcinoma lymph node was probably the result of factors that influence RAI uptake, including patient preparation, administered activity and the sensitivity of detection (14). Despite many studies indicating the correlation between sensitivity of ^{18}F -FDG PET and Tg levels in patients with negative radioiodine scan (15, 16), ^{18}F -FDG PET/CT in our patient's case

was surprisingly negative. These finding might be due to the tumor volume being too small for the detection by ^{18}F -FDG PET/CT (17). Another explanation for such a result would be lower aggressiveness and slow progression of the disease (18).

Ganglioneuromas (GN) represent slow-growing, mostly benign tumors of the sympathetic nervous system that originate from the neural crest tissue. Usually located in the posterior mediastinum, retroperitoneum and adrenal gland, these neoplasms are in up to 5% of patients presented as neck tumor masses (19). Most GNs are asymptomatic, with the exception of compression symptoms affecting adjacent structures and infrequent clinical manifestations resulting from catecholamine hypersecretion (20). It is well known that tumors of neuroectodermal origin (neurogenic tumors-neuroblastoma, ganglioneuroblastoma and ganglioneuroma) are characterized by SSTR expression, which enables them to be visible on somatostatin receptor scintigraphy (SRS) (21). Therefore, the higher the degree

of differentiation of neurogenic tumors, the higher the rate of SSTR expression and most likely the SRS positivity (22).

CONCLUSION

In this case report, we want to point out the importance of using different complementary imaging modalities simultaneously with biochemical response monitoring (serum Tg levels) in order to define potential existence of radioiodine refractoriness. Multidisciplinary approach in the context of diagnostic imaging and therapy is crucial in the management of advanced thyroid cancer with suspected loss of thyroid differentiation features. It must be emphasized that clinical awareness of coexisting asymptomatic rare tumors such as cervical ganglioneuroma is mandatory in making diagnostic conclusions and choice of therapy in the treatment of locoregional recurrent disease in differentiated thyroid carcinomas.

References

1. Roseland ME, Dewaraja YK, Wong KK. Advanced imaging and theranostics in thyroid cancer. *Curr Opin Endocrinol Diabetes Obes* 2022;29(5):456-65. <https://doi.org/10.1097/MED.0000000000000740>
2. Choudhury PS, Gupta M. Differentiated thyroid cancer theranostics: radioiodine and beyond. *Br J Radiol* 2018;91(1091):20180136. <https://doi.org/10.1259/bjr.20180136>
3. Fullmer T, Cabanillas ME, Zafereo M. Novel Therapeutics in Radioactive Iodine-Resistant Thyroid Cancer. *Front Endocrinol (Lausanne)* 2021; 12:720723. <https://doi.org/10.3389/fendo.2021.720723>
4. Wang TS, Dubner S, Sznyter LA, Heller KS. Incidence of metastatic well-differentiated thyroid cancer in cervical lymph nodes. *Arch Otolaryngol Head Neck Surg* 2004;130(1):110-3. <https://doi.org/10.1001/archotol.130.1.110>
5. Capdevila J, Galofré J, Grande E, et al. Consensus on the management of advanced radioactive iodine-refractory differentiated thyroid cancer on behalf of the Spanish Society of Endocrinology Thyroid Cancer Working Group (GTSEEN) and Spanish Rare Cancer Working Group (GETHI). *Clin. Transl. Oncol* 2017; 19:279-87. <https://doi.org/10.1007/s12094-016-1554-5>
6. Kiyota N, Robinson B, Shah M, et al. Defining Radioiodine-Refractory Differentiated Thyroid Cancer: Efficacy and Safety of Lenvatinib by Radioiodine-Refractory Criteria in the SELECT Trial. *Thyroid* 2017;27(9):1135-41. <https://doi.org/10.1089/thy.2016.0549>
7. Ganly I, Nixon IJ, Wang LY, et al. Survival From Differentiated Thyroid Cancer: What Has Age Got to Do With it? *Thyroid* (2015) 25(10):1106-14. <https://doi.org/10.1089/thy.2015.0104>
8. Haugen BR, Alexander EK, Bible KC, Doherty GM, Mandel SJ, Nikiforov YE, et al. 2015 American Thyroid Association Management Guidelines for Adult Patients With Thyroid Nodules and Differentiated Thyroid Cancer: The American Thyroid Association Guidelines Task Force on Thyroid Nodules and Differentiated Thyroid Cancer. *Thyroid* 2016;26(1):1-133. <https://doi.org/10.1089/thy.2015.0020>
9. Eustatia-Rutten CFA, Corssmit EPM, Biermasz NR et al. Survival and death causes in differentiated thyroid carcinoma. *J Clin Endocrinol Metab* 2006; 91:313-9. <https://doi.org/10.1210/jc.2005-1322>
10. Tuttle RM, Ahuja S, Avram AM, et al. Controversies, Consensus, and Collaboration in the Use of (¹³¹I) Therapy in Differentiated Thyroid Cancer: A Joint Statement From the American Thyroid Association, the European Association of Nuclear Medicine, the Society of Nuclear Medicine and Molecular Imaging, and the European Thyroid Association. *Thyroid* 2019;29(4):461-70. <https://doi.org/10.1089/thy.2018.0597>
11. Budiawan H, Salavati A, Kulkarni HR, Baum RP. Peptide receptor radionuclide therapy of treatment-refractory metastatic thyroid cancer using (90)Yttrium and (177)Lutetium labeled somatostatin analogs: toxicity, response and survival analysis. *Am J Nucl Med Mol Imaging* 2014;4(1):39-52.
12. Atkinson H, England JA, Rafferty A, et al. Somatostatin receptor expression in thyroid disease. *Int J Exp Pathol* 2013;94(3):226-9. <https://doi.org/10.1111/iep.12024>
13. Czepczyński R, Matysiak-Grześ M, Gryczyńska M, et al. Peptide receptor radionuclide therapy of differentiated thyroid cancer: efficacy and toxicity. *Arch Immunol Ther Exp (Warsz)* 2015;63(2):147-54. <https://doi.org/10.1007/s00005-014-0318-6>

14. Van Nostrand D. Radioiodine Refractory Differentiated Thyroid Cancer: Time to Update the Classifications. *Thyroid* 2018; 28(9): 1083-93. <https://doi.org/10.1089/thy.2018.0048>
15. Leboulleux S, Schroeder PR, Schlumberger M, Ladenson PW. The role of PET in follow-up of patients treated for differentiated epithelial thyroid cancers. *Nat Clin Pract Endocrinol Metab* 2007;3:112-21. <https://doi.org/10.1038/ncpendmet0402>
16. Giammarile F, Hafdi Z, Bournaud C, et al. Is [¹⁸F]-2-fluoro-2-deoxy-d-glucose (FDG) scintigraphy with non-dedicated positron emission tomography useful in the diagnostic management of suspected metastatic thyroid carcinoma in patients with no detectable radioiodine uptake? *Eur J Endocrinol*. 2003;149:293-300. <https://doi.org/10.1530/eje.0.1490293>
17. Choi SJ, Jung KP, Lee SS, et al. Clinical Usefulness of F-18 FDG PET/CT in Papillary Thyroid Cancer with Negative Radioiodine Scan and Elevated Thyroglobulin Level or Positive Anti-thyroglobulin Antibody. *Nucl Med Mol Imaging* 2016;50(2):130-6. <https://doi.org/10.1007/s13139-015-0378-5>
18. Larg MI, Barbus E, Gabora K, et al. ¹⁸F-FDG PET/CT IN DIFFERENTIATED THYROID CARCINOMA. *Acta Endocrinol (Buchar)* 2019;15(2):203-8. <https://doi.org/10.4183/aeb.2019.203>
19. Xu T, Zhu W, Wang P. Cervical ganglioneuroma: A case report and review of the literature. *Medicine (Baltimore)*. 2019;98(15):e15203. <https://doi.org/10.1097/MD.00000000000015203>
20. Geoerger B, Hero B, Harms D, et al. Metabolic activity and clinical features of primary ganglioneuromas. *Cancer* 2001;91(10):1905-13. [https://doi.org/10.1002/1097-0142\(20010515\)91:10<1905::AID-CNCR1213>3.0.CO;2-4](https://doi.org/10.1002/1097-0142(20010515)91:10<1905::AID-CNCR1213>3.0.CO;2-4)
21. Tan EH, Goh SW. Exploring new frontiers in molecular imaging: Emergence of Ga PET/CT. *World J Radiol* 2010;2(2):55-67. <https://doi.org/10.4329/wjr.v2.i2.55>
22. Kogner P, Borgström P, Bjellerup P, et al. Somatostatin in neuroblastoma and ganglioneuroma. *Eur J Cancer* 1997; 33:2084-9. [https://doi.org/10.1016/S0959-8049\(97\)00212-8](https://doi.org/10.1016/S0959-8049(97)00212-8)

Article info

Received: October 21, 2023

Revised: February 12, 2024

Accepted: March 12, 2024

Online first: November 13, 2024

Redak slučaj koegzistencije cervikalnog ganglioneuroma i metastatskog limfnog čvora papilarnog karcinoma štitaste žlezde: mogućnost pogrešne dijagnoze karcinoma štitaste žlezde refraktornog na radiojodnu terapiju

Katarina Vuleta Nedić¹, Vladimir R. Vukomanović¹, Ana Ranković², Vesna D. Ignjatović¹, Svetlana Kocić³

¹Univerzitet u Kragujevcu, Fakultet medicinskih nauka, Centar za nuklearnu medicinu, Kragujevac, Srbija

²Univerzitetski klinički centar Kragujevac, Služba za radiološku dijagnostiku, Kragujevac, Srbija

³Kliničko-bolnički centar Zemun, Služba za radiološku dijagnostiku, Beograd, Srbija

SAŽETAK

Uvod. Dobro diferentovani karcinomi štitaste žlezde kod većine bolesnika uspešno se leče primenom adekvatne hirurške procedure, radiojodnom terapijom i supresijom sekrecije tireoidnog stimulišućeg hormona (TSH). Međutim, u 2% – 4% slučajeva tokom praćenja se detektuju metastaze u lateralnim limfnim čvorovima vrata. Oko dve trećine ovakvih slučajeva postaje rezistentno na radiojodnu terapiju, što je pojava poznata kao „dobro diferentovani karcinomi štitaste žlezde refraktorni na radiojodnu terapiju“, koja ima lošu prognozu i ograničene terapijske mogućnosti. U ovom radu se prikazuje slučaj u kojem se zbog incidentalnog nalaza koegzistirajućeg cervikalnog ganglioneurinoma pogrešno posumnjalo na radiojodnu refraktornost.

Prikaz slučaja. Četrdesetčetvorogodišnjem muškarcu je na našem odeljenju data druga doza radiojoda zbog postojanja lokoregionalnih metastatskih limfnih čvorova papilarnog karcinoma štitaste žlezde. U toku kliničkog praćenja, tendencija porasta tireoglobulina u uslovima TSH supresije, negativna dijagnostička scintigrafija celog tela sa ¹³¹I i negativna pozitronska emisiona tomografija / kompjuterizovana tomografija sa ¹⁸F-fluorodeoksiglukozom (¹⁸F-FDG PET/CT) pobudili su sumnju u postojanje tzv. dobro diferentovanog karcinoma štitaste žlezde refraktornog na radiojodnu terapiju. Iako se razmatralo sprovođenje peptid-receptor radionuklidne terapije (PRRT), prvenstveno zbog pozitivnog nalaza dobijenog iz vrata bolesnika na ^{99m}Tc-Hynic-TOC imidžingu (Tektrotyd scan), nakon dodatne morfološke dijagnostike prednost je data hirurškoj terapijskoj proceduri. Histopatološki nalaz uklonjene tumorske mase u vratu potvrdio je prisustvo jednog metastatskog limfnog čvora papilarnog karcinoma štitaste žlezde i koegzistirajućeg ganglioneurinoma.

Zaključak. Autori ovog rada želeli su ukazati na značaj multidisciplinarnog pristupa u dijagnostici i terapiji u slučajevima kada se sumnja na gubitak svojstva diferencijacije dobro diferentovanih karcinoma štitaste žlezde. Takođe, istaknuto je koliko je važno da kliničari budu svesni postojanja asimptomatskih retkih tumora.

Ključne reči: radiojodna terapija, dobro diferentovani karcinom štitaste žlezde refraktorni na radiojodnu terapiju, ganglioneurinom