

Original article

Sexual Dimorphism of the Mental Foramen Position in the Population of Southeast Serbia: A Cone Beam Computed Tomography Study

Antonije Stanković¹, Jelena Popović^{1,2}, Marija Daković Bjelaković³, Aleksandar Mitić^{1,2},
Nenad Stošić^{1,2}, Marija Nikolić^{1,2}

¹University of Niš, Faculty of Medicine, Niš, Serbia

²Clinic of Dental Medicine, Department of Restorative Dentistry and Endodontics, Niš, Serbia

³University of Niš, Faculty of Medicine, Department of Anatomy, Niš, Serbia

SUMMARY

Introduction/Aim. Knowing the precise position of the mental foramen is of great clinical importance in dentistry due to significant anatomical structures that pass through this foramen. The aim of this study was to examine the sexual dimorphism of the horizontal and vertical position of the mental foramen in relation to constant anatomical landmarks in the population of southeast Serbia using cone beam computed tomography (CBCT).

Materials and methods. Thirty-two CBCT images of male and 34 CBCT images of female patients were used. The horizontal distance from the anterior border of the mental foramen to the skeletal middle line was measured, as well as the vertical distance from the anterior and inferior borders of the mental foramen to the tangential line, which touches the base of the mandible.

Results. Sexual dimorphism of horizontal position of the mental foramen was observed on the right side ($t = 3.69$; $p < 0.001$). When measuring the vertical position from the superior border of the foramen, sexual dimorphism was observed on both the left ($t = 4.31$; $p < 0.001$) and right side ($t = 4.22$; $p < 0.001$). Similarly, when measured from the inferior border of the foramen, sexual dimorphism was evident on both the left ($t = 5.61$; $p < 0.001$) and right side ($t = 4.01$; $p < 0.001$).

Conclusion. The observed sexual dimorphism of the mental foramen position can facilitate dental treatments and surgical interventions on the mandible in patients of different genders.

Keywords: CBCT, mental foramen, skeletal midline, base of mandible, sexual dimorphism

Corresponding author:

Antonije Stanković

e-mail: stankovicantonije@gmail.com

INTRODUCTION

In a large number of anatomical and anthropological research, a significant focus is directed towards the analysis of variations in the morphology of the facial bones and skulls between males and females. In the conclusions of numerous studies, the results of which showed sexual dimorphism on the mandibles and mandibular canines, it is emphasized that the mandible can provide very useful data when determining gender in forensics (1–3).

The mental foramen – the end of the external branch of the mandibular canal, located on the outside of the mandible, represents an important anatomical structure. The reasons for that are significant anatomical elements that pass through it, including blood vessels that vascularize the lower lip and chin, as well as nerve structures that innervate the lower lip. Neglecting the position of this foramen can lead to various complications during surgical interventions in this region, but also to wrong diagnoses during the interpretation of radiological images. The projection of the mental foramen on radiographs at the level of the tooth root apex could be mistaken for a periapical lesion, which can lead inexperienced clinicians to a wrong diagnosis and unnecessary endodontic treatment (4).

The impossibility of palpation of the mental foramen in patients and difficulties in visualizing this foramen on retroalveolar radiographs impose the need for studies dealing with the most common positions of this foramen (5). Knowing the individual variations in the position of the mental foramen can help dentists and surgeons adjust their techniques and treatments to achieve the best results for patients. A review of the literature indicated that cone beam computed tomography (CBCT) studies, dealing with the 3D analysis of orofacial structures, provide extremely useful information in the precise identification of the mental foramen, which has clinical significance (6).

The aim of this study was to examine the sexual dimorphism of the horizontal and vertical position of the mental foramen in relation to constant anatomical landmarks in the population of southeast Serbia using cone beam computed tomography.

PATIENTS AND METHODS

This study was approved by the Ethics Committee of the Clinic of Dental Medicine in Niš, Serbia

with decision No. 01-728/23. The research was carried out at the Clinic of Dental Medicine in Niš. The study included 32 males and 34 females. Sixty-six CBCT scans of patients from southeast Serbia were used in the research. Patients allowed access to their CBCT images for additional analysis, after being informed of how the study would be conducted. The state of the dentition of the patients was not an exclusive factor in this research, because the anatomical landmarks, in relation to which the position of the mental foramen was determined, did not depend on the state of the dentition and age-related changes in the mandibles. Criteria for exclusion from the study were pathological lesions in the mandible and incomplete ossification of the examined region.

Measurements on CBCT images were performed in the GALILEOS program (Sirona Dental Systems, USA) by two independent clinicians with many years of experience in interpreting CBCT images. Two therapists separately measured the same distances on the same images, and the recorded distance represented the absolute middle of these two values. In this way, subjectivity was avoided, and the recorded result represented a compromise between two therapists.

The vertical and horizontal position of the mental foramen was measured on the CBCT images. To measure the horizontal position, the skeletal midline was established by identifying the lingual canals on the cross-sectional view, whose direction aligns with the skeletal midline (Figure 1). Once the skeletal midline, corresponding to the medial plane, was determined through the lingual canals, a line representing the vertical distance of the foramen was constructed and measured (Figure 2). This line originated from the anterior border of the mental foramen and extended perpendicularly to the skeletal midline (FMa-SM) (Figure 3 and 4).

In order to measure the vertical dimensions of the mental foramen, a tangential line touching the base of the mandible at its lowest point, was established. Distances were then measured from the superior border of the mental foramen to the tangential line (FMs-BM), and from the inferior border of the mental foramen to the tangential line (FMi-BM), both of which were perpendicular to the tangential line (Figure 4). The height of the mental foramen (FMs-FMi) was calculated by subtracting the distance from the inferior border of the mental foramen to the tangential line from the distance from

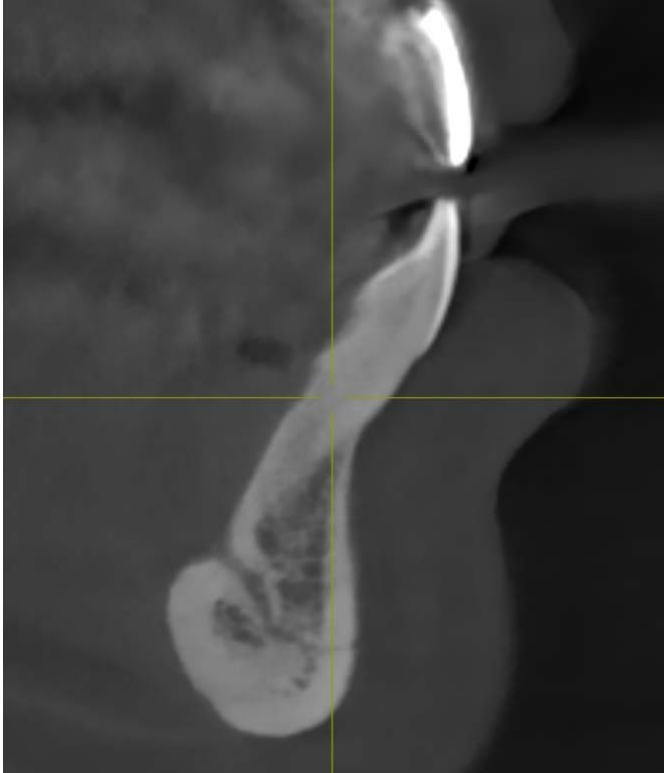


Figure 1. Skeletal midline (sagittal plane)

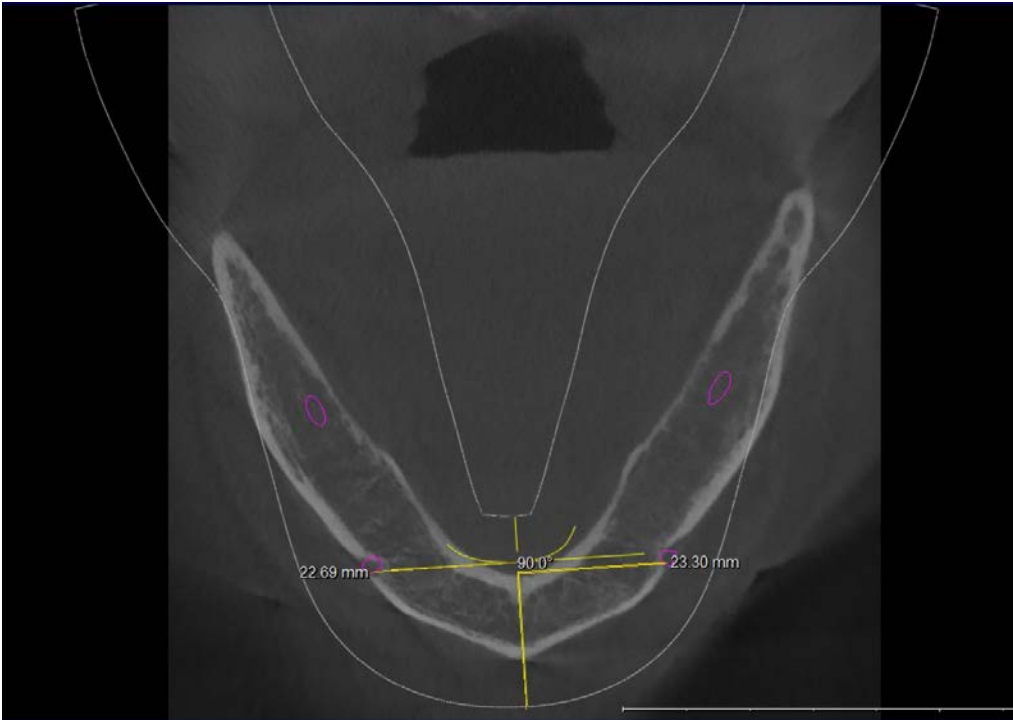


Figure 2. Horizontal position of mental foramen (axial plane)

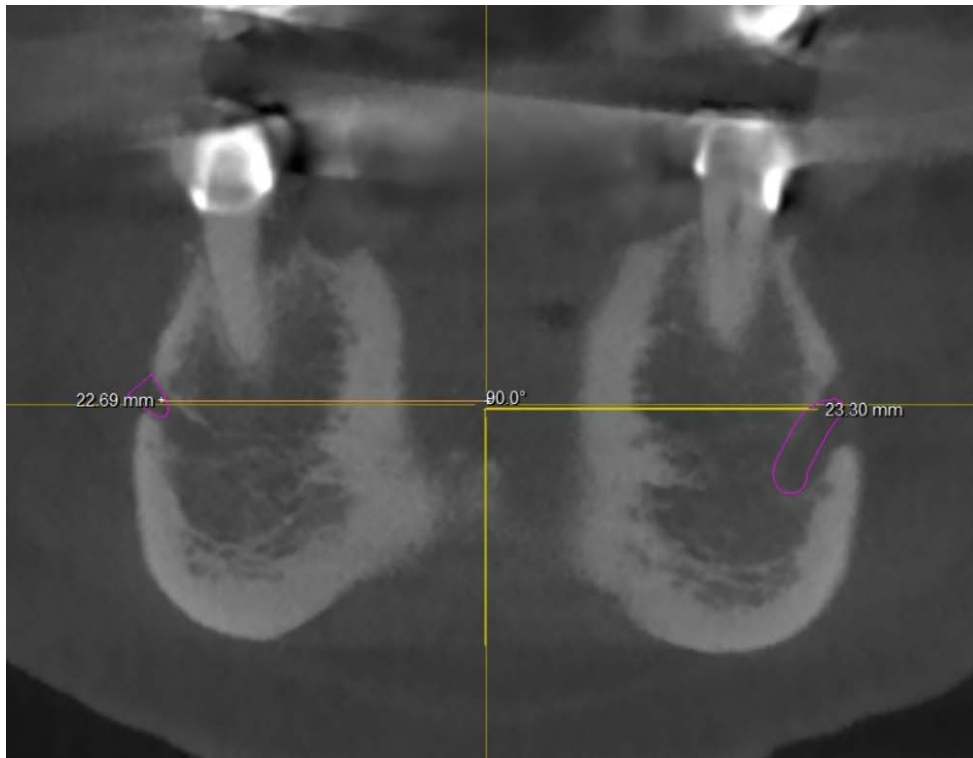


Figure 3. Horizontal position of mental foramen (tangential plane)

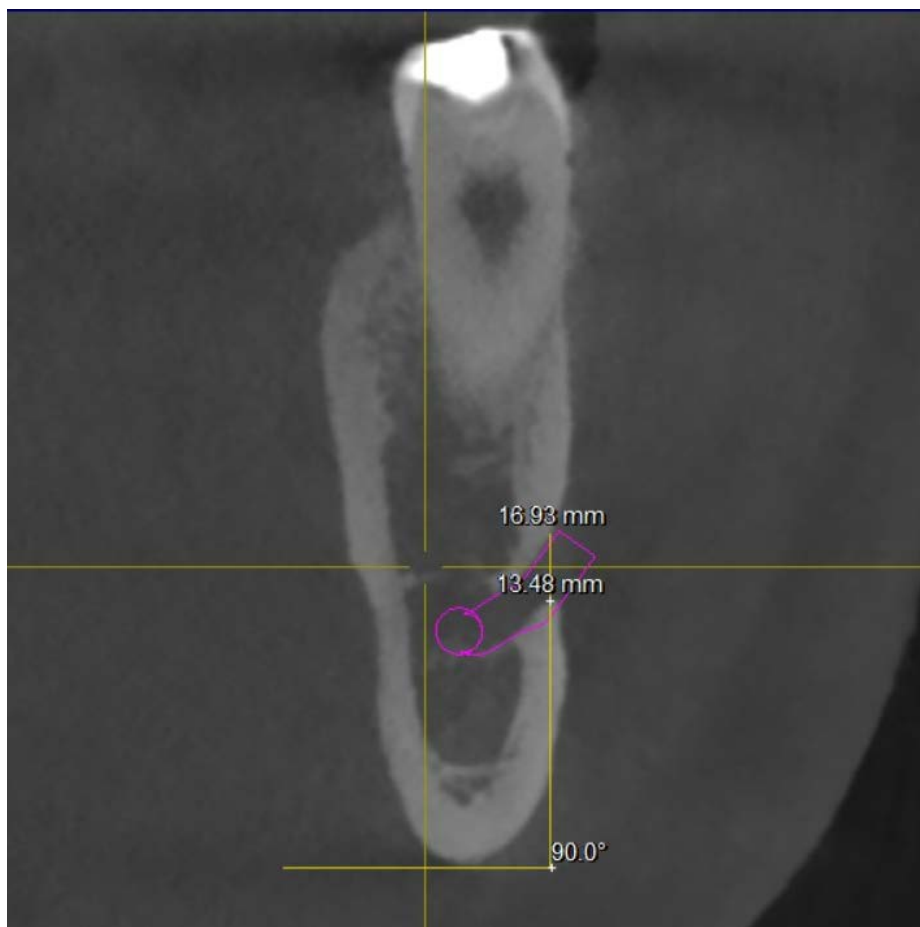


Figure 4. Vertical position of mental foramen (cross sectional)

Table 1. Abbreviations of distance measured in this research

| | |
|--|---------|
| Horizontal distance from the anterior border of the mental foramen to the skeletal midline | FMa-SM |
| Vertical distance from the superior border of the mental foramen to the base of the mandible | FMs-BM |
| The vertical distance from the inferior border of the mental foramen to the base of the mandible | FMi-BM |
| The height of the mental foramen | FMs-FMi |

FMa – anterior border of mental foramen, SM – skeletal midline, FMs – superior border of mental foramen, BM – base of mandible, FMi – inferior border of mental foramen

the superior border of the mental foramen to the tangential line.

Table 1 shows the distances which were measured in this research as well as their abbreviations, which were used in this paper.

For the purpose of comparing the measured values on the left and right sides, as well as between males and females, the Student's t-test with a significance of $p < 0.001$ was used in the IBM SPSS version 26.0 program. To calculate sexual dimorphism, the following formula was used: $(X_m/X_f - 1) \cdot 100\%$, by Anuthama et al. (7) who investigated dental sexual dimorphism.

RESULTS

The average horizontal distance from the anterior border of the mental foramen to the midline of the mandible was 21.64 mm. In males, this distance was on average 21.99 mm, while in females it was 21.30 mm. The highest value was recorded on the right side in males, while the lowest value was observed on the right side in females. The highest va-

riability of the distance was observed in males on the left side, while the lowest variability was recorded on the right side in males (Table 2). Analyzing the results in relation to gender, a statistically significant difference was observed in the values of the distance from the anterior of the mental foramen to the midline of the mandible between males and females on the right side (Table 3).

The recorded average vertical distance from the superior border of the mental foramen to the base of the mandible was 16.16 mm. In male patients, this distance was on average 16.97 mm, while in female patients it was 15.40 mm. The maximum value was observed in males on the left side, while the minimum value was observed in females, also on the left side. The greatest variability in distances was observed among females on the left side, while the smallest variability was observed among males on the left side (Table 4). A statistically significant difference was observed in the values of the distance from the superior border of the mental foramen to the base of the mandible between males and females, both on the right and left side (Table 5).

Table 2. Horizontal distance from the anterior border of the mental foramen to the skeletal midline of the mandible (FMa-SM) expressed in mm

| Sex | Anatomic side | n | X_{\max} | X_{\min} | \bar{X} | SD | CV |
|--------|---------------|-----|------------|------------|-----------|------|-------|
| Male | Left | 32 | 24.73 | 18.82 | 21.91 | 1.63 | 7.43% |
| | Right | 32 | 25.14 | 19.21 | 22.08 | 1.41 | 6.39% |
| Female | Left | 34 | 23.71 | 18.80 | 21.82 | 1.45 | 6.65% |
| | Right | 34 | 22.69 | 17.78 | 20.78 | 1.43 | 6.88% |
| Total | | 132 | 25.14 | 17.78 | 21.64 | 1.55 | 7.16% |

n – number of samples, X_{\max} – maximum, X_{\min} – minimum, \bar{X} – average value, SD – standard deviation, CV – coefficient of variation

Table 3. Student's *t*-test of comparison of the mean values of the horizontal distance from the anterior border of the mental foramen to the midline of the mandible

| | | t | df | p |
|--|-------------------|------|----|-------|
| Comparison of FMa-SM between males and females | On the left side | 0.23 | 64 | 0.82 |
| | On the right side | 3.69 | 64 | 0.00* |
| Comparison of FMa-SM between the left and right side | In males | 0.44 | 62 | 0.66 |
| | In females | 2.96 | 66 | 0.04 |

t – independent sample t-test value, df - degree of freedom value, p – the p-value of probability value, FMa – anterior border of mental foramen, SM – skeletal midline, * – statistical significance at > 0.001

Table 4. Vertical distance of the superior border of the mental foramen to the base of the mandible (FMs-BM) expressed in mm

| Sex | Anatomic side | n | X _{max} | X _{min} | X̄ | SD | CV |
|--------|---------------|-----|------------------|------------------|-------|------|--------|
| Male | Left | 32 | 19.07 | 15.63 | 17.29 | 1.10 | 6.36% |
| | Right | 32 | 18.60 | 14.06 | 16.65 | 1.36 | 8.17% |
| Female | Left | 34 | 18.84 | 12.82 | 15.70 | 1.79 | 11.4% |
| | Right | 34 | 17.98 | 12.99 | 15.11 | 1.60 | 10.59% |
| Total | | 132 | 19.07 | 12.82 | 16.16 | 1.7 | 10.52% |

n – number of samples, X_{max} – maximum, X_{min} – minimum, X̄ – average value, SD – standard deviation, CV – coefficient of variation

Table 5. Student's *t*-test of comparison of the mean values of vertical distance of the superior border of the mental foramen to the base of the mandible

| | | t | df | p |
|--|-------------------|------|----|-------|
| Comparison of FMs-BM between males and females | On the left side | 4.31 | 64 | 0.00* |
| | On the right side | 4.22 | 64 | 0.00* |
| Comparison of FMs-BM between the left and right side | In males | 2.04 | 62 | 0.46 |
| | In females | 1.45 | 66 | 0.15 |

t – independent sample t-test value, df - degree of freedom value, p – the p-value of probability value, FMs – superior border of mental foramen, BM – base of mandible, * – statistical significance at > 0.001

Table 6. Vertical distance of the inferior border of the mental foramen to the base of the mandible (FMi-BM) expressed in mm

| Sex | Anatomic side | n | X _{max} | X _{min} | X̄ | SD | CV |
|--------|---------------|-----|------------------|------------------|-------|------|--------|
| Male | Left | 32 | 16.61 | 12.98 | 15.53 | 1.04 | 6.7% |
| | Right | 32 | 16.93 | 10.60 | 13.92 | 1.65 | 11.85% |
| Female | Left | 34 | 16.52 | 8.96 | 12.69 | 1.56 | 12.29% |
| | Right | 34 | 15.46 | 10.19 | 12.38 | 1.46 | 11.79% |
| Total | | 132 | 16.93 | 8.96 | 14.01 | 2.18 | 15.56% |

n – number of samples, X_{max} – maximum, X_{min} – minimum, X̄ – average value, SD – standard deviation, CV – coefficient of variation

The average value of the vertical distance from the inferior border of the mental foramen to the base of the mandible was 14.01 mm. For males, this value was on average 14.22 mm and 12.53 mm for females. In male patients, the maximum value was observed on the right side, while the minimum value was registered in the female patients on the left side. Among the female patients, the greatest variability of the distance was observed on the left side and the smallest variability on the right side (Table 6). A statistically significant difference was observed in the examined values between males and females, both on the right and left side (Table 7).

The height of the mental foramen was 2.82 mm on average. In males, the mean value was 2.75

mm and 2.86 mm in females. Both the highest and lowest recorded values were observed in females on the left side. In males, the greatest variability of these values was found on the left side, while the lowest variability was found among females on the right side (Table 8). The analysis of the mental foramen height in relation to gender did not show significant differences between male and female respondents, nor between sides (Table 9).

The greatest sexual dimorphism was observed in the value of the distance between the inferior border of the mental foramen and the base of the mandible on the left side, while the smallest sexual dimorphism was observed in the height of the right mental foramen (Table 10).

Table 7. Student's *t*-test of comparison of the mean values of vertical distance of the inferior border of the mental foramen to the base of the mandible

| | | t | df | p |
|--|-------------------|------|----|-------|
| Comparison of FMi-BM between males and females | On the left side | 5.61 | 64 | 0.00* |
| | On the right side | 4.01 | 64 | 0.00* |
| Comparison of FMi-BM between the left and right side | In males | 1.79 | 62 | 0.08 |
| | In females | 0.85 | 64 | 0.31 |

t – independent sample t-test value, df - degree of freedom value, p – the p-value of probability value, FMi – inferior border of foramen mentale, BM – base of mandible, * – statistical significance at >0.001

Table 8. Height of mental foramen (FMs-FMi) expressed in mm

| Sex | Anatomic side | n | X _{max} | X _{min} | X̄ | SD | CV |
|--------|---------------|-----|------------------|------------------|------|------|--------|
| Male | Left | 32 | 4.11 | 1.56 | 2.75 | 0.85 | 30.91% |
| | Right | 32 | 4.05 | 1.63 | 2.74 | 0.77 | 28.10% |
| Female | Left | 34 | 4.77 | 1.56 | 3.01 | 1.03 | 34.22% |
| | Right | 34 | 3.45 | 1.81 | 2.73 | 0.50 | 18.31% |
| Total | | 132 | 4.77 | 1.56 | 2.82 | 0.81 | 28.72% |

n – number of samples, X_{max} – maximum, X_{min} – minimum, X̄ – average value, SD – standard deviation, CV – coefficient of variation

Table 9. Student's *t*-test of comparison of the mean values of the height of the mental foramen

| | | t | df | P |
|---|-------------------|------|----|------|
| Comparison of FMs-FMi between males and females | On the left side | 1.11 | 64 | 0.27 |
| | On the right side | 0.08 | 64 | 0.94 |
| Comparison of FMs-FMi between the left and right side | In males | 0.07 | 62 | 0.95 |
| | In females | 1.45 | 66 | 0.15 |

t – independent sample t-test value, df - degree of freedom value, p – the p-value of probability value, FMs – superior border of mental foramen, FMi – inferior border of mental foramen

Table 10. Percentage and ranks of sexual dimorphism in examined values

| Distance | Anatomic side | Male | Female | Difference | Percent | Rank |
|----------|---------------|-------|--------|------------|---------|------|
| FMa-SM | Left side | 21.91 | 21.82 | 0.1 | 0.41% | 7. |
| | Right side | 22.08 | 20.78 | 1.3 | 6.26% | 6. |
| FMs-BM | Left side | 17.29 | 15.70 | 1.59 | 10.13% | 4. |
| | Right side | 16.65 | 15.11 | 1.54 | 10.19% | 3. |
| FMi-BM | Left side | 14.53 | 12.69 | 1.84 | 14.5% | 1. |
| | Right side | 13.92 | 12.38 | 1.54 | 12.44% | 2. |
| FMs-FMi | Left side | 2.75 | 3.01 | 0.26 | 8.64% | 5. |
| | Right side | 2.74 | 2.73 | 0.01 | 0.37% | 8. |

FMa – anterior border of mental foramen, SM – skeletal midline, FMs – superior border of mental foramen, BM – base of mandible, FMi – inferior border of mental foramen

DISCUSSION

Sexual dimorphism is considered an extremely important aspect in the wider study of human anatomy and anthropology. When analyzing sexual dimorphism, the population differences of examiners can affect the obtained results (8).

Different methods for determining of the mental foramen position in relation to various anatomical structures, such as analysis of panoramic X-ray and retroalveolar radiographs, have been described in the literature. However, the cone beam computed tomography (CBCT) technique has been recognized as a highly accurate method for precise determination of the position of the mental foramen. The use of CBCT helps avoid inconsistencies on two-dimensional radiographs, such as the potential misinterpretation of the mental foramen as part of the mandibular canal (9). With the three-dimensional representation of bone structures in CBCT images, it becomes possible to analyze and measure distances between all points on the bone in sagittal, vertical, and horizontal (tangential, cross-sectional, axial) planes. This eliminates ambiguities that may arise in two-dimensional images (10).

Numerous authors point to a large percentage of edentulous patients in the population of Serbia (11, 12), so the aim of this research was to present a representative sample of the population, including both edentulous individuals and those with a full dentition.

Varying values of the distance from the alveolar ridge to the mental foramen were observed in CBCT studies (8, 13, 14), where the horizontal po-

sition of the mental foramen was determined. This variability can be explained by bone resorption resulting from tooth loss. Moreover, no sexual dimorphism in the investigated values was noted in the mentioned studies, indicating that bone resorption is not dependent on sexual characteristics but rather on the dental condition. Tooth loss leads to bone resorption, causing irreversible changes in the mandible. After tooth loss, there is atrophy in the supporting apparatus of the tooth and the pars alveolaris of the mandible, affecting the position of the mandibular canal and the mental foramen (15). In addition to that, the appearance of the mental foramen at the top of the edentulous alveolar ridge was reported in extreme cases recorded in the literature (15). This is why in our study we used parameters such as the skeletal midline and the base of the mandible, which remain relatively constant and are not prone to changes during lifetime, nor are they influenced by tooth loss (16).

The results of this research showed that the distance from the anterior border of the mental foramen to the skeletal midline was 21.64 mm on average, which is not in agreement with studies where this distance was measured on dry skulls (17–19). This discrepancy could be explained by different reference points in relation to which the measurements were made, such as the center of the mental foramen as opposed to the anterior border of the mental foramen, which was used in our study. Regardless of the mentioned disagreement in the obtained values, significantly higher values in males, which were registered on the right side, are in agreement with the results obtained from the analysis of

dry skulls in the study of Apinhasmit et al. (17), where significantly higher values were also registered in males than females.

The distance from the anterior border of the mental foramen to the skeletal midline, recorded in this study, is smaller than the distance reported by Sheikhi et al. (20) who examined the position of the mental foramen in the Iranian population. This is in agreement with the data from the literature which indicate that, unlike the population of Iran, where in most cases this foramen is observed in the region of the second premolar, in the population of Europeans the foramen is placed significantly more mesially (21). The clinical significance of this is reflected in the fact that great care should be taken when placing the implant in the interforaminal zone. This area is otherwise considered safe due to the absence of larger anatomical structures, but in the studied population is shorter compared to other populations.

Difficulties in accurately differentiating the superior border of the mental foramen from the rest of the mandible body on CBCT images, which were observed in the study by Subash et al. (9), can explain the incomplete agreement between the results of the distance from the superior border of the mental foramen to the base of the mandible with data from the literature (16). However, the obtained sexual dimorphism in the distance from the superior border of the mental foramen to the base of the mandible is in agreement with studies where these distances were measured on panoramic radiograph and CBCT images in other populations (16, 22). The average distance from the inferior border of the foramen to the base of the mandible obtained in this study is similar to the results reported in the study that used an identical method to analyze this distance (8, 20). The analysis of the obtained results showed that the distance from the inferior border of the foramen to the base of the mandible was significantly greater in males, which is in agreement with the data from the literature (8, 20).

The sexual dimorphism of the vertical position of the foramen could be explained by the summary of numerous studies that emphasize the difference in the size of the mandibles in males and females, which is reflected in the greater vertical length of the mandibles in males (3). These differences could be caused by sex hormones, which affect bone growth, but also by different masticatory forces in males and females, which result in different growth of the mandible (22). The brachiocephalic shape of the skull,

which according to some research is more common in females, can also explain the smaller vertical dimension of the mandible, because this type of skulls is characterized by a shorter distance from the base of the mandible to the superior or inferior border of the mental foramen (22). Also, the development of the mandible in females ends at a younger age than in males, which means that the active period of growth in females begins and ends earlier than in males (23).

The average height of the mental foramen was 2.82 mm. This result is similar to the values of the vertical size of the mental foramen reported in the study by Von Arx et al. (13) who measured this value on CBCT images. The absence of sexual dimorphism of the vertical size of the foramen is not in agreement with some data from the literature. This can be explained by different ways of measuring this distance, which have been used in the literature. The distance in this research was calculated by subtracting the value obtained by measuring the distance of the inferior border of the mental foramen from the base of the mandible from the value obtained by measuring the distance from the superior border of the mental foramen to the base of the mandible, while in the literature the results of direct measurement of the distance between the superior and the inferior border could be found (24).

No statistically significant difference in the examined values was observed, neither in females nor in males, between the left and right side. These results are in agreement with the data from the literature, which indicates that these values do not exhibit significant differences between the two sides in individuals of the same sex (25). A literature review revealed a considerable number of studies in which authors, assuming a negligible difference between the left and right side, investigated the sexual dimorphism of the mental foramen by examining its position on one side only (22, 26).

CONCLUSION

The CBCT technique proved to be an extremely useful method for determining the sexual dimorphism of the mental foramen in the examined population. Sexual dimorphism was observed in the horizontal position of the mental foramen on the right side, and the vertical position of the mental foramen on the left and right side. Understanding the variations in the position of the mental foramen,

based on the patient's sex, can facilitate the diagnosis of pathological conditions, and enhance planning and execution of dental interventions on the mandible.

Acknowledgment

The research was supported by the scientific research project of the Faculty of Medicine of the University of Niš, Serbia financed by the Ministry of Education, Science and Technological Development of the Republic of Serbia (451-03-47/2023-01/200113).

References

1. Aggarwal B, Gorea RK, Gorea A, et al. Comparative analysis of clinical and experimental methods for determination of sexual dimorphism of mandibular canines. *J Forensic Leg Med* 2016;44:20-3.
<https://doi.org/10.1016/j.jflm.2016.08.014>
2. Alarcón JA, Bastir M, Rosas A. Variation of mandibular sexual dimorphism across human facial patterns. *Homo* 2016;67(3):188-202.
<https://doi.org/10.1016/j.jchb.2015.11.004>
3. Vodanović M, Dumančić J, Demo Ž, et al. Determination of Sex by Discriminant Function Analysis of Mandibles From two Croatian Archaeological Sites. *Acta Stomatol Croat* 2006;40:263-77.
4. Petrovski M, Jovevska S, Terzieva-Petrovska O, et al. Radiographic analysis of the mental foramen and mandibular canal localization. *J Hyg Eng Des* 2020;30:125-9.
5. Philips JL, Weller RN, Kulild JC. The mental foramen: Part II. Radiographic position in relation to the mandibular second premolar. *J Endod* 1992;18(6):271-4.
[https://doi.org/10.1016/S0099-2399\(06\)80953-2](https://doi.org/10.1016/S0099-2399(06)80953-2)
6. Pelé A, Berry PA, Evanno C, et al. Evaluation of Mental Foramen with Cone Beam Computed Tomography: A Systematic Review of Literature. *Radiol Res Pract* 2021;2021:1-10.
<https://doi.org/10.1155/2021/8897275>
7. Anuthama K, Shankar S, Ilayaraja V, et al. Determining dental sex dimorphism in South Indians using discriminant function analysis. *Forensic Sci Int* 2011;212(1-3):86-9.
<https://doi.org/10.1016/j.forsciint.2011.05.018>
8. Rodríguez-Cárdenas Y, Casas-Campana M, Arriola-Guillén L, et al. Sexual dimorphism of mental foramen position in Peruvian patients: A cone-beam-computed tomography study. *Indian J Dent Res* 2020;31(1):103.
https://doi.org/10.4103/ijdr.IJDR_557_18
9. Subash T, Balaraj B, Hema C. Determination of sex by cone-beam computed tomography analysis of mental foramen in South Indian Population. *Int J Forensic Odontol* 2019;4(1):21.
https://doi.org/10.4103/ijfo.ijfo_33_18

10. Kaasalainen T, Ekholm M, Siiskonen T, et al. Dental cone beam CT: An updated review. *Phys Med* 2021;88:193-217.
<https://doi.org/10.1016/j.ejimp.2021.07.007>
11. Pejčić A, Kostić M, Igić M, et al. Tooth loss and periodontal status in patients with cardiovascular disease in the Serbian population: A randomized prospective study. *Int J Dent Hyg* 2023;21(2):317-27.
<https://doi.org/10.1111/idh.12663>
12. Zdravković D, Milosavljević M, Stojić V, et al. Epidemiological survey of dental prosthetic restorations in central Serbian population. *Timok Medical Gazette* 2018;43(4):161-9.
<https://doi.org/10.5937/tmg1804161Z>
13. Von Arx T, Friedli M, Sendi P, et al. Location and Dimensions of the Mental Foramen: A Radiographic Analysis by Using Cone-beam Computed Tomography. *J Endod* 2013;39(12):1522-8.
<https://doi.org/10.1016/j.joen.2013.07.033>
14. Haktanır A, Ilgaz K, Turhan-Haktanır N. Evaluation of mental foramina in adult living crania with MDCT. *Surg Radiol Anat* 2010;32(4):351-6.
<https://doi.org/10.1007/s00276-009-0572-1>
15. Avila-Ortiz G, Chambrone L, Vignoletti F. Effect of alveolar ridge preservation interventions following tooth extraction: A systematic review and meta-analysis. *J Clin Periodontol* 2019;46(S21):195-223.
<https://doi.org/10.1111/jcpe.13057>
16. Renjith G, Mary DP, Soe K, et al. Sex estimation by discriminant function analysis using anatomical location of mental foramen. *Forensic Science International: Reports*. 2019;1:100018.
<https://doi.org/10.1016/j.fsir.2019.100018>
17. Apinhasmit W, Methathrathip D, Chompoopong S, et al. Mental foramen in Thais: an anatomical variation related to gender and side. *Surg Radiol Anat* 2006;28(5):529-33.
<https://doi.org/10.1007/s00276-006-0119-7>
18. Neiva RF, Gapski R, Wang H. Morphometric Analysis of Implant-Related Anatomy in Caucasian Skulls. *J Periodontol* 2004;75(8):1061-7.
<https://doi.org/10.1902/jop.2004.75.8.1061>
19. Agthong S, Huanmanop T, Chentanez V. Anatomical Variations of the Supraorbital, Infraorbital, and Mental Foramina Related to Gender and Side. *J Oral Maxillofac Surg* 2005;63(6):800-4.
<https://doi.org/10.1016/j.joms.2005.02.016>
20. Sheikhi M, Kheir MK. CBCT Assessment of Mental Foramen Position Relative to Anatomical Landmarks. *Int J Dent* 2016;2016:1-4.
<https://doi.org/10.1155/2016/5821048>
21. Khojastepour L, Mirbeigi S, Mirhadi S, et al. Location of Mental Foramen in a Selected Iranian Population: A CBCT Assessment. *Iran Endod J* 2015;10(2):117-21.
22. Khalifa S, Salem H. Sex determination by morphometric analysis of the mental foramen from digital panoramic radiography. *Egypt Dent J* 2022;68(3):2189-97.
<https://doi.org/10.21608/edj.2022.124669.2002>
23. Akgül AA, Toygar TU. Natural craniofacial changes in the third decade of life: A longitudinal study. *Am J Orthod Dentofacial Orthop* 2002;122(5):512-22.
<https://doi.org/10.1067/mod.2002.128861>
24. Alsoleihat F, Al-Omari FA, Al-Sayyed AR, et al. The mental foramen: A cone beam CT study of the horizontal location, size and sexual dimorphism amongst living Jordanians. *Homo* 2018;69(6):335-9.
<https://doi.org/10.1016/j.jchb.2018.11.003>
25. Rani A, Kanjani V, Kanjani D, et al. Morphometric assessment of mental foramen for gender prediction using panoramic radiographs in the West Bengal population - A retrospective digital study. *J Adv Clin Res Insights* 2019;6(3):63-6.
<https://doi.org/10.15713/ins.jcri.262>

Article info

Received: April 4, 2024

Accepted: June 7, 2024

Online first: November 15, 2024

Polni dimorfizam pozicije bradnog otvora u populaciji jugoistočne Srbije: studija zasnovana na primeni kompjuterizovane tomografije konusnog zraka

Antonije Stanković¹, Jelena Popović^{1,2}, Marija Daković Bjelaković³, Aleksandar Mitić^{1,2}, Nenad Stošić^{1,2}, Marija Nikolić^{1,2}

¹Univerzitet u Nišu, Medicinski fakultet, Niš, Srbija

²Klinika za dentalnu medicinu, Odeljenje za bolesti zuba i endodonciju, Niš, Srbija

³Univerzitet u Nišu, Medicinski fakultet, Institut za anatomiju, Niš, Srbija

SAŽETAK

Uvod/Cilj. Poznavanje precizne pozicije bradnog otvora ima veliki klinički značaj u stomatologiji zbog važnih anatomskih struktura koje prolaze kroz ovaj otvor. Cilj ove studije bio je da se u populaciji jugoistočne Srbije korišćenjem kompjuterizovane tomografije konusnog zraka (engl. *cone beam computed tomography* – CBCT) ispita polni dimorfizam horizontalne i vertikalne pozicije bradnog otvora u odnosu na konstantne anatomske orijentire.

Materijali i metode. U istraživanju su korišćena 32 CBCT snimka muškaraca i 34 CBCT snimka žena. Mereno je horizontalno rastojanje od prednje ivice bradnog otvora do skeletne srednje linije, kao i vertikalno rastojanje od gornje i donje ivice bradnog otvora do tangencijalne linije, koja dodiruje bazu mandibule.

Rezultati. Polni dimorfizam horizontalne pozicije bradnog otvora uočen je na desnoj strani ($t = 3,69$; $p < 0,001$). Kada se vertikalna pozicija merila od gornje ivice otvora, polni dimorfizam uočen je na levoj ($t = 4,31$; $p < 0,001$) i na desnoj strani ($t = 4,22$; $p < 0,001$); tako je bilo i kada je merenje sprovedeno od donje ivice otvora na levoj ($t = 5,61$; $p < 0,001$) i na desnoj strani ($t = 4,01$; $p < 0,001$).

Zaključak. Uočeni polni dimorfizam pozicije bradnog otvora može olakšati izvođenje stomatoloških tretmana i hirurških intervencija na mandibuli kod pacijenata oba pola.

Ključne reči: kompjuterizovana tomografija konusnog zraka, bradni otvor, skeletna srednja linija, baza mandibule, polni dimorfizam