

Original article

Evaluation of the Mandibular Canal Course in Southeast Serbian Population: A Cone Beam Computed Tomography Study

Kosta Todorović^{1,2}, Marija Daković-Bjelaković³, Jelena Popović^{1,4}, Aleksandar Mitić^{1,4},
Antonije Stanković¹, Ana Todorović^{1,5}, Nenad Stošić^{1,4}, Marija Nikolić^{1,4}

¹University of Niš, Faculty of Medicine, Niš, Serbia

²Clinic of Dental Medicine, Department of Oral Surgery, Niš, Serbia

³University of Niš, Faculty of Medicine, Department of Anatomy, Niš, Serbia

⁴Clinic of Dental Medicine, Department of Restorative Dentistry and Endodontics, Niš, Serbia

⁵Clinic of Dental Medicine, Department of Orthodontics, Niš, Serbia

SUMMARY

Introduction/Aim. Oral surgical interventions in the mandibular region require detailed knowledge of the position and course of the mandibular canal. The aim of this study was to determine the most common course of mandibular canal on cone beam computed tomography (CBCT) images in the population of Southeast Serbia.

Material and method. One hundred ninety-four mandibular canals on CBCT images of 97 patients (48 male and 49 female) aged 18-65 years were analyzed in the study. According to Worthington, courses of mandibular canals are classified into catenary, descending, and straight. The obtained results were analyzed in relation to the gender and the age of the patients as well as to the left and right side of the mandible.

Results. The most common course of mandibular canal on the analyzed images was catenary (41.2%), then straight (37.1%), while the least was descending (21.6%). The most common type in males was the catenary (46.9%), while the straight type was the most common in females (39.6%). Statistical analysis showed no significant difference in the distribution of the mandibular canal course in relation to the gender, age of the patients, and the side of the mandible.

Conclusion. The observed variations emphasize the importance of careful individual preoperative analysis of CBCT images of each patient as well as planning different treatment modalities in the region of the mandible.

Keywords: mandible, mandibular canal, anatomical variation, CBCT

Corresponding author:

Kosta Todorović

e-mail: kosta_todorovic@yahoo.com

INTRODUCTION

Oral surgical interventions require detailed knowledge of anatomical structures in the orofacial region. The mandibular canal is a very important anatomical detail of the mandible, due to the importance of the neuro-vascular elements that pass through it. On the inner side of the ramus of the mandible is the initial opening of this canal—the mandibular foramen, into which the inferior alveolar nerve, artery, and vein enter. This canal extends together with inferior alveolar neurovascular bundle along the entire body of the mandible towards the mental foramen, while its branch continues into the contralateral side (1).

Knowledge of variations in the position and course of this canal is of great clinical importance in the prevention of complications caused by iatrogenic injuries of the canal and its contents during surgical teeth extractions (2). Also, precise knowledge and identification of the exact localization of the mandibular canal is extremely important in planning the position of dental implants, which are becoming an increasingly common choice for lost teeth replacing (3). Surgical removal of periapical lesions, which are located on the roots of the teeth in the immediate vicinity of the mandibular canal, in some cases described in the literature, is accompanied by post-operative neurosensitive complaints (4).

Cone beam computed tomography (CBCT) is one of the most useful diagnostic procedures in oral surgery because it shows a very precise insight into the localization of the anatomical structures of the examined area (5). Using this method, numerous authors have described the different relationships of the mandibular canal with the roots of premolars and molars, where the most common finding is that the mandibular canal is closest to the second molar (6, 7). The literature review also points out that the mandibular canal is closer to the buccal cortex of the mandible on the right side (7). The variations of the different types of mandibular canal course are precisely described by the classification according to Worthington (8), who stated that the mandibular

canal can be classified as catenary, descending, and straight.

The aim of this study was to determine the most common course of the mandibular canal on CBCT images in the population of Southeast Serbia.

MATERIAL AND METHOD

Undertaking of this study was approved by the Ethics Committee of the Clinic for Dental Medicine in Niš (01-728/23). The study analyzed 194 CBCT images of the mandibular canals from 97 adults (48 male and 49 female) aged 18-65 years, who came to the Clinic of Dental Medicine in Niš. The inclusion criteria for examining the images were alveolar processes of the mandible with full dentition where the entire mandibular canals were visible, while edentulous jaws and mandibles with pathological conditions, supernumerary, and impacted teeth were not analyzed. The images were taken with the Galileos Comfort Plus scanner (Sirona Dental Systems, Germany). In order to avoid subjectivity and non-uniformity in classifications, mandibular canals on CBCT images were examined and classified by one experienced oral surgeon. The analysis of the images was performed in the Galileos program (Sirona Dental Systems, Germany). The course of the canal was monitored based on the software marking on the projection of the image in the sagittal plane. In this way, canals were located and classified according to Worthington (8) into catenary, descending, and straight. The catenary canal was in the form of U-like shape, the descending canal was in the form of plunging progressive curve, while the straight canal was step ascent along with root apexes (Figure 1). The obtained results were analyzed in relation to the gender and the age of the patients, but also in relation to the left and right side of the mandible. The obtained data were analyzed in IBM SPSS version 26.0 using the Chi-square test with a significance of $p < 0.05$.

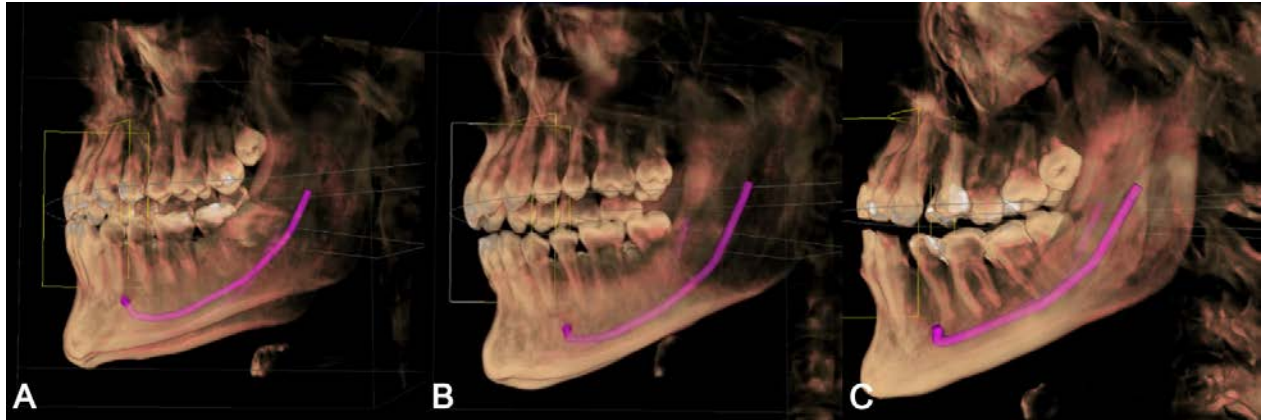


Figure 1. Different types of mandibular canals courses (A – catenary, B – descending, C – straight) (Original CBCT)

RESULTS

The results showed that the most common type of mandibular canal on the analyzed images was catenary (41.2%), then straight (37.1%), while the least present type was descending (21.6%).

The analysis of the results in relation to gender showed that the catenary type was the most common in males with 46.9%, while the most common type in females was straight (39.8%). However, statistical analysis did not show a significant difference in the frequency distribution of mandibular canal course types in relation to gender (Table 1).

The analysis of the results in relation to the age of the patients showed that the catenary type of

canal was most often found in patients aged 34-48 and 49-65 years, while in patients aged 18-33 years, the distribution of catenary and straight type was equal. Statistical analysis showed that there was no significant difference in the distribution of canal types in relation to the age of the patients (Table 2).

The analysis of the results in relation to the left and right side of the mandible showed that the most common canal course on the left side was the catenary type (44.3%), while the most common type on the right side was straight (40.2%), however, this difference in the types of courses was not statistically significant (Table 3).

Table 1. Frequency distribution of mandibular canal types according to gender

			Canal types			Total	Chi - square
			Catenary	Descending	Straight		
Gender	Male	Count	45	18	33	96	χ ² = 2.587 df = 2 p = 0.274
		%	46.9%	18.8%	34.4%		
	Female	Count	35	24	39	98	
		%	35.7%	24.5%	39.8%		
Total		Count	80	42	72	194	
		%	41.2%	21.6%	37.1%		100%

χ² – Chi –square test value; df – degree of freedom value, p – the value of the probability of the Chi-square test

Table 2. Frequency distribution of mandibular canal types according to age group

			Canal types			Total	Chi - square
			Catenary	Descending	Straight		
Age group	18-33	Count	20	16	20	56	$\chi^2 = 4.220$ df = 4 p = 0.377
		%	35.7%	28.6%	35.7%	100%	
	34-48	Count	27	16	25	68	
		%	39.7%	23.5%	36.8%	100%	
	49-65	Count	33	10	27	70	
		%	47.1%	14.3%	38.6%	100%	
Total		Count	80	42	72	194	
		%	41.2%	21.6%	37.1%	100%	

χ^2 – Chi –square test value; df – degree of freedom value, p – the value of the probability of the Chi-square test

Table 3. Frequency distribution of mandibular canal types according to anatomic side of mandible

			Canal types			Total	Chi - square	
			Catenary	Descending	Straight			
Anatomic side	Left side	Count	43	21	33	97	$\chi^2 = 0.950$ df = 2 p = 0.622	
		%	44.3%	21.6%	34.0%	100%		
	Right side	Count	37	21	39	97		
		%	38.1%	21.6%	40.2%	100%		
	Total		Count	80	43	71		194
			%	41.2%	21.6%	37.1%		100%

χ^2 – Chi –square test value; df – degree of freedom value, p – the value of the probability of the Chi-square test

DISCUSSION

Although panoramic images are most often used in planning oral surgical interventions, the impossibility of three-dimensional visualization of certain anatomical structures makes the CBCT technology necessary in everyday practice. Due to the growing need for more precise identification of these structures, many researchers have proven that CBCT technology is irreplaceable in determining anatomical and morphological variations (5).

The advantage of this method of imaging is reflected in the fact that patients are exposed to a lower dose of radiation during imaging with CBCT technology compared to imaging using the traditional computerized tomography (CT) method (9). The study of Jung and Cho (10), which examined the visibility of the mandibular canal on X-ray images,

concluded that the visibility of the mandibular canal is better on images obtained by CBCT technology than on panoramic images. CBCT technology provides the possibility of viewing the position of the canal in three dimensions, which makes it possible to determine its bucco-oral position (5).

The results of this study showed that the most common course of the mandibular canal in the population of Southeast Serbia was catenary (41.2%). This course was also the most common in the research of Ozturk et al. (11) who determined the direction of the mandibular canal on dry skulls. The studies of Jung and Cho (10) as well as Liu et al. (12), conducted on CBCT and panoramic images, where the canals were classified into four types, showed that the most frequent mandibular canal type was

the one that corresponded to the catenary canal type. The root apices of premolars and molars are further apart from the mandibular catenary type canal compared to the other types, which greatly reduces complications in form of accidental opening of the canal during the extractions of these teeth. The catenary type of canal is also the most suitable type for placing implants, according to the greatest distance of the mandibular canal from the apex of the lower first molar (13), which, due to frequent extractions, is the tooth that most often needs to be replaced with an implant (14). The importance of this is reflected in the fact that injuries of the mandibular canal are manifested by bleeding or paresthesia and complications that would require additional surgical interventions in order to treat them (2).

The results of this study showed that 37.1% of the respondents had a straight canal type. Data from the literature showed that this type of canal proved to be the most inconvenient during oral surgical interventions, due to the proximity of the premolars and molars to the mandibular canal (13). A similar prevalence of this type of canal was observed in a study by Mirbeigi et al. (15), who examined the mandibular canal course in the Iranian population using the Worthington classification (8). However, in contrast to the results of our study, where the catenary type was the most common, the aforementioned study by Mirbeigi et al. (15) showed that all three types of canals were equally prevalent among patients.

The least represented canal type in this study was the descending type with 21.6%. However, data from the literature showed that this type of canal was dominant in studies in the populations of India and Kenya, where the same methodology was used to classify the course of the mandibular canal on CBCT images (13, 16). Such discrepancies could be explained by population differences, which reflect in different types of mandibular growth (17). Numerous studies highlight such differences between the populations of Europe, India, Israel and South Korea, regarding the different relationships of the posterior teeth with the mandibular canal (18) and the mental foramen (19).

Although the results of this study showed that the catenary type was more common in males, while

the straight type was more common in females, statistical analysis showed no significant difference in the frequency distribution of examined types of mandibular canal between gender and the age groups. This result is in agreement with numerous studies, that examined the sexual dimorphism of the course of the mandibular canal as well as the frequency of different courses of the mandibular canals in different age groups (13, 15, 20). The analysis of the course in relation to the side of the mandible in this study showed that catenary type was more prevalent on the left side, while the straight one was more common on the right side, however, this difference was not statistically significant. On the contrary, in the study by Viera et al. (20), catenary and descending types were observed significantly more often on the right side.

The limitation of the study is reflected in the impossibility of a wider analysis of patients who had to meet the criteria for participation in the study. Considering that in the population of Serbia, a significant number of people do not have full dentition due to frequent tooth extractions (21), a large number of patients could not participate in the study.

CONCLUSION

Although the catenary type of the mandibular canal was present in the largest number of examined patients within the population of Southeast Serbia, a significant number of patients were identified with the straight type of the mandibular canal, which represents a very challenging situation for oral surgical interventions. This emphasizes the importance of careful individual preoperative analysis of CBCT images of each patient as well as planning of different treatment modalities in the region of the mandible.

Acknowledgment

The study was supported by the scientific research project of the Faculty of Medicine of the University of Niš, Serbia financed by the Ministry of Education, Science and Technological Development of the Republic of Serbia (451-03-47/2023-01/200113).

References

1. Asghar A, Priya A, Ravi KS, et al. An evaluation of mandibular canal variations: a systematic review and meta-analysis. *Anat Sci Int* 2023;98(2):176-84.
<https://doi.org/10.1007/s12565-022-00682-7>
2. Valenzuela-Fuenzalida JJ, Cariseo C, Gold M, et al. Anatomical variations of the mandibular canal and their clinical implications in dental practice: a literature review. *Surg Radiol Anat* 2021;43(8):1259-72.
<https://doi.org/10.1007/s00276-021-02708-7>
3. Alghamdi HS, Jansen JA. The development and future of dental implants. *Dent Mater J* 2020;39(2):167-72.
<https://doi.org/10.4012/dmj.2019-140>
4. Zahedi S, Mostafavi M, Lotfirikan N. Anatomic Study of Mandibular Posterior Teeth Using Cone-beam Computed Tomography for Endodontic Surgery. *J Endod* 2018;44(5):738-43.
<https://doi.org/10.1016/j.joen.2018.01.016>
5. Jacobs R, Salmon B, Codari M, et al. Cone beam computed tomography in implant dentistry: recommendations for clinical use. *BMC Oral Health* 2018;18(1):88.
<https://doi.org/10.1186/s12903-018-0523-5>
6. Kovisto T, Ahmad M, Bowles WR. Proximity of the Mandibular Canal to the Tooth Apex. *J Endod* 2011;37(3):311-5.
<https://doi.org/10.1016/j.joen.2010.11.030>
7. Kawashima Y, Sakai O, Shosho D, et al. Proximity of the Mandibular Canal to Teeth and Cortical Bone. *J Endod* 2016;42(2):221-4.
<https://doi.org/10.1016/j.joen.2015.11.009>
8. Worthington P. Injury to the inferior alveolar nerve during implant placement: a formula for protection of the patient and clinician. *Int J Oral Maxillofac Implants* 2004;19(5):731-4.
9. Razi T, Emamverdizadeh P, Nilavar N, et al. Comparison of the Hounsfield Unit in CT scan with the Gray Level in cone-beam CT. *J Dent Res Dent Clin Dent Prospects* 2019;13(3):177-82.
<https://doi.org/10.15171/joddd.2019.028>
10. Jung YH, Cho BH. Radiographic evaluation of the course and visibility of the mandibular canal. *Imaging Sci Dent* 2014;44(4):273.
<https://doi.org/10.5624/isd.2014.44.4.273>
11. Ozturk A, Potluri A, Vieira AR. Position and course of the mandibular canal in skulls. *Oral Surg Oral Med Oral Pathol Oral Radiol* 2012;113(4):453-8.
<https://doi.org/10.1016/j.tripleo.2011.03.038>
12. Liu T, Xia B, Gu Z. Inferior alveolar canal course: a radiographic study. *Clin Oral Implants Res* 2009;20(11):1212-8.
<https://doi.org/10.1111/j.1600-0501.2009.01736.x>
13. Okiriamu A, Butt F, Opondo F, et al. Morphology and Variant Anatomy of the Mandibular Canal in a Kenyan Population: A Cone-Beam Computed Tomography Study. *Craniomaxillofac Res Innov* 2023;8:275284642311827.
<https://doi.org/10.1177/27528464231182775>
14. Almahdi HM, Alabdrabulridha Z, AlAbbas J, et al. Permanent First Mandibular Molar: Loss Prevalence and Pattern among Saudis in Al-Ahsa. *Eur J Dent* 2023;17(03):840-4.
<https://doi.org/10.1055/s-0042-1757904>
15. Mirbeigi S, Kazemipoor M, Khojastepour L. Evaluation of the Course of the Inferior Alveolar Canal: The First CBCT Study in an Iranian Population. *Pol J Radiol* 2016;81:338-41.
<https://doi.org/10.12659/PJR.896229>
16. Jesudas PC, Seelam M, Santhosh Kumar MP. Assessment of Relation and Course of Inferior Alveolar Nerve Using CBCT-A Retrospective Study of 120 Cases. *Int J Dent Oral Sci* 2021;4320-5.

<https://doi.org/10.19070/2377-8075-21000879>

17. Mangla R, Singh N, Dua V, et al. Evaluation of mandibular morphology in different facial types. *Contemp Clin Dent* 2011;2(3):200.
<https://doi.org/10.4103/0976-237X.86458>
18. Lvovsky A, Bachrach S, Kim HC, et al. Relationship between Root Apices and the Mandibular Canal: A Cone-beam Computed Tomographic Comparison of 3 Populations. *J Endod* 2018;44(4):555-8.
<https://doi.org/10.1016/j.joen.2017.12.020>
19. Tabinda H. Characteristics of The Mental Foramen In Different Populations. *Internet J Biol Anthropol* 2011;4(2):1-7.

<https://doi.org/10.5580/f30>

20. Vieira CL, Veloso SAR, Lopes FF. Location of the course of the mandibular canal, anterior loop and accessory mental foramen through cone-beam computed tomography. *Surg Radiol Anat* 2018;40(12):1411-7.
<https://doi.org/10.1007/s00276-018-2081-6>
21. Čanković D, Čanković M, Ukropina S, et al. Association of health determinants and depressive symptoms with tooth loss in the Serbian adult population: A cross-sectional study. *Vojnosanit Pregl* 2019;76(10):985-97.
<https://doi.org/10.2298/VSP171011182C>

Article info

Received: December 29, 2023

Accepted: January 30, 2024

Online first:

Evaluacija toka mandibularnog kanala u populaciji jugoistočne Srbije: studija kompjuterizovane tomografije konusnog zraka

Kosta Todorović^{1,2}, Marija Daković-Bjelaković³, Jelena Popović^{1,4}, Aleksandar Mitić^{1,4},
Antonije Stanković¹, Ana Todorović^{1,5}, Nenad Stošić^{1,4}, Marija Nikolić^{1,4}
Anton. bol zuba

¹Univerzitet u Nišu, Medicinski fakultet, Niš, Srbija

²Klinika za dentalnu medicinu Niš, Odeljenje za oralnu hirurgiju, Niš, Srbija

³Univerzitet u Nišu, Medicinski fakultet, Institut za anatomiju, Niš, Srbija

⁴Klinika za dentalnu medicinu Niš, Odeljenje za bolesti zuba i endodonciju, Niš, Srbija

⁵Klinika za dentalnu medicinu Niš, Odeljenje za ortopediju vilica, Niš, Srbija

SAŽETAK

Uvod. Oralnohirurške intervencije u regiji mandibule zahtevaju detaljno poznavanje položaja i toka mandibularnog kanala. Cilj ovog rada bio je da se odredi najčešći tok mandibularnog kanala na snimcima dobijenim pomoću kompjuterizovane tomografije konusnog zraka (*cone-beam computed tomography* – CBCT) u populaciji jugoistočne Srbije.

Materijal i metode. U studiji je analizirano 194 CBCT snimaka mandibularnih kanala 97 pacijenta (48 muškaraca i 49 žena) starih od 18 do 65 godina. Mandibularni kanali se prema Worthingtonu klasifikuju na zakrivljene, poniruće i prave. Dobijeni rezultati su analizirani u odnosu na pol i starost pacijenata, kao i u odnosu na levu i desnu stranu mandibule.

Rezultati. Najčešći tok mandibularnog kanala na analiziranim snimcima bio je zakrivljeni (41,2%), potom pravi (37,1%), dok je najmanje zastupljen bio ponirući kanal (21,6%). Kod muškaraca je najzastupljeniji bio zakrivljeni tip (46,9%), dok je kod žena najzastupljeniji bio pravi tip kanala (39,6%). Statistička analiza nije pokazala značajnu razliku u distribuciji različitih tokova mandibularnog kanala u odnosu na pol i starost pacijenata, kao i u odnosu na stranu mandibule.

Zaključak. Uočene varijacije naglašavaju značaj pažljive individualne preoperativne analize CBCT snimaka svakog pacijenta, kao i planiranja različitih operativnih pristupa u regiji mandibule.

Ključne reči: mandibula, mandibularni kanal, anatomske varijacije, kompjuterizovana tomografija konusnog zraka