

Review article

The Latest Recommendations in the Prophylaxis and Treatment of Bleeding from Esophagogastric Varices

Ivan Grgov¹, Daniela Benedeto Stojanov^{2,3}, Biljana Radovanović Dinić^{2,3}, Milica Grgov⁴,
Saša Grgov⁵, Tomislav Tasić⁶

¹General Hospital Leskovac, Department of General Surgery with Traumatology, Leskovac, Serbia

²University Clinical Center Niš, Clinic of Gastroenterology and Hepatology, Niš, Serbia

³University of Niš, Faculty of Medicine, Niš, Serbia

⁴University Clinical Center Niš, Clinic of Pulmonology, Niš, Serbia

⁵Primary Healthcare Center VIP Medical, Leskovac, Serbia

⁶General Hospital Leskovac, Department of Gastroenterology and Hepatology, Leskovac, Serbia

SUMMARY

Introduction/Aim. Esophagogastric varices develop in 50-60% of patients with liver cirrhosis, and 30% of them have one episode of variceal hemorrhage within two years of variceal diagnosis. The aim of the paper was to present the latest attitudes in the treatment of esophagogastric varices.

Literature review. Prevention of first bleeding from esophageal varices (EV) involves the use of non-selective beta blockers (NSBB) or carvedilol, while in case of their intolerance or contraindications for their use, endoscopic band ligation (EBL) should be performed. In acute variceal bleeding, endoscopy should be performed, preferably within 12 hours of the presentation of the bleeding, and EBL should be applied. In case of refractory hemorrhage (about 20%), repeated endoscopy and hemostasis or balloon tamponade, self-expanding metal stent (SEMS), transjugular intrahepatic portosystemic shunt (TIPS) and surgical therapy are required. Bleeding from gastric varices (GV) is less common than bleeding from EV but is significantly more severe with higher mortality and more frequent treatment failure. The therapy of choice is the application of cyanoacrylate (CYA), which can be applied under endoscopic ultrasonography (EUS) control. In the trial is the administration of coil injections with or without CYA. In the secondary prophylaxis of bleeding from EV, NSBB should be used in combination with EBL. In the secondary prophylaxis of bleeding from cardiofundal varices, the approach is individual.

Conclusion. The therapy of choice for the primary prevention of bleeding from EV is NSBB, while the combined therapy (NSBB and EBL) is for the secondary prophylaxis of bleeding. CYA is the therapy of choice for GI bleeding. Refractory variceal hemorrhage requires the application of many therapeutic modalities.

Keywords: esophagogastric varices, prophylaxis, treatment

Corresponding author:

Ivan Grgov

e-mail: grgovivan@gmail.com

INTRODUCTION

Portal hypertension (PH) develops as a consequence of increased portal flow resistance, which is also contributed to by an increase in collateral portal blood flow resistance. The obstruction of portal flow can be at different levels: pre-sinusoidal (e.g., due to schistosomiasis, portal vein thrombosis); sinusoidal (for example, advanced chronic liver disease); post-sinusoidal (e.g., Budd-Chiari syndrome) (1).

Although patients with cirrhosis and portal hypertension may bleed at various sites, ruptured esophagogastric varices are the most severe and common cause of gastrointestinal (GI) bleeding, accounting for nearly 80% of bleeding episodes in these patients. Moreover, about 60-80% of bleeding in patients with liver cirrhosis is from esophageal varices (EV), and about 7% from gastric varices (GV). Varicose veins develop in 50-60% of patients with liver cirrhosis, and 30% of them have one episode of variceal hemorrhage within two years of variceal diagnosis. Variceal bleeding accounts for 2-20% of all GI bleeding and 50% of severe, persistent bleeding. The greatest risk of bleeding from varices is within 6-12 months from their discovery.

About 5-8% of patients die within 24 hours due to uncontrolled variceal bleeding. Significant prognostic indicators of inability to control variceal bleeding are: active bleeding during emergency endoscopy, bacterial infection, and portosystemic pressure gradient greater than 20 mmHg. The mentioned factors, together with low serum albumin values and kidney failure, are significant prognostic indicators of the risk of early rebleeding from varices. After the initial bleeding, the incidence of early rebleeding within the first six weeks varies from 30-40%. The greatest risk is within the first five days, during which 40% of all rebleeding episodes occur (2, 3).

Mortality from variceal bleeding is estimated at six weeks. Earlier studies showed that the mortality was 30-50%. However, with the development of more effective therapeutic measures, mortality has fallen to 15-20% today. Very important prognostic indicators of the risk of death are the severity of liver disease, renal insufficiency, persistent variceal bleeding, and recurrent bleeding (4).

The aim of this review paper was to show the latest recommendations regarding the primary prophylaxis of bleeding from esophagogastric varices (in patients who had not had previous bleeding from

varices), treatment of acute bleeding and secondary prophylaxis of variceal bleeding, i.e., prevention of rebleeding in patients who had survived the first episode of bleeding.

DIAGNOSIS OF ESOPHAGOGASTRIC VARICES AND RISK STRATIFICATION

The gold standard in the diagnosis of esophagogastric varices is esophagogastroduodenoscopy (EGD), which, in addition to diagnosing varices, also stratifies the risk of bleeding from varices based on their size and high-risk stigmata. EV are classified according to size into small, medium, and large, with or without the presence of risk signs of bleeding in the form of various forms of red spots (1). GV typically occur in the advanced stage of portal hypertension. Sarin's classification of GV includes four types of varices: gastroesophageal varices type 1 (GOV1) are the most common (74%), they extend 2 to 5 cm below the gastroesophageal junction and are continuous with the EV; gastroesophageal varices type 2 (GOV2) are in the cardia and fundus of the stomach and are in continuity with the EV; isolated GV type 1 (IGV1) are varices that occur in the fundus of the stomach in the absence of EV; isolated GV type 2 (IGV2) occur in the body of the stomach, antrum or pylorus (Figure 1) (5). The risk factors for bleeding from GV are: 1. Localization of varices—bleeding is more common in GOV2 and IGV1, which are usually called "cardiofundal varices", than in the other two types of GV; 2. Varicose size—larger veins (> 20 mm) bleed more often than smaller ones; 3. The presence of risk signs or the so-called "red spots" on the varicose veins; 4. Severity of liver disease—MELD score over 17 (3, 6).

Hepatic venous pressure gradient (HVPG) is the gold standard for assessing clinically significant portal hypertension that is present if values are greater than 10 mmHg (7). In practice, non-invasive tests are increasingly used to assess clinically significant portal hypertension, such as the assessment of liver fibrosis by elastography, platelet count, and spleen size (8-10). According to the Baveno VII consensus, EGD is not necessary as a screening for varices if liver fibrosis values on elastography are less than 20 Kpa and the platelet count is more than $150 \times 10^9/L$, because these values indicate a very low probability (< 5%) that the patient has high risky varicose veins. If a patient with diagnosed liver cirrhosis does not meet these criteria, endoscopic screening for varices is recommended (11).

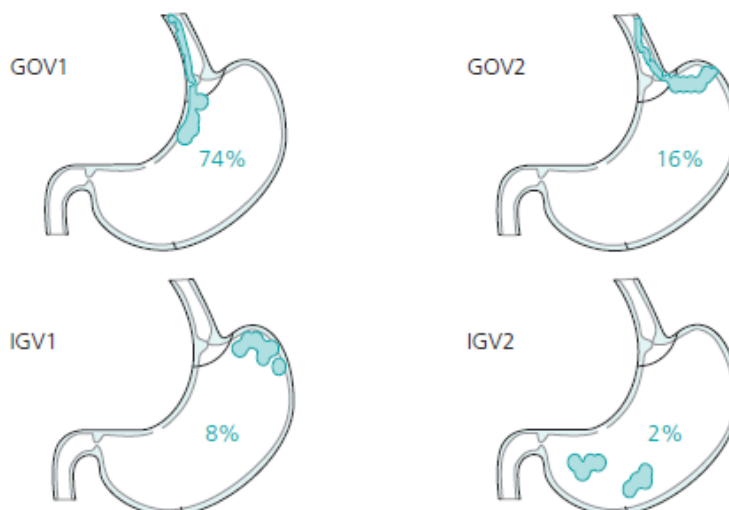


Figure 1. Different types of gastric varices according to Sarin's classification (GOV, gastroesophageal varices; IGV, isolated gastric varices) (5)

PRIMARY PROPHYLAXIS OF VARICEAL BLEEDING

The indication for primary prophylaxis of variceal hemorrhage is an advanced chronic liver disease (ACLD) and endoscopically diagnosed high-risk varices. Non-selective beta blockers (NSBB) or endoscopic band ligation (EBL) significantly reduce the risk of a first episode of variceal bleeding (1).

According to the recommendations of the European Society for GI Endoscopy (ESGE), patients with compensated ACLD (caused by viruses, alcohol and/or non-alcoholic steatohepatitis in non-obese population with BMI < 30 kg/m²) and clinically significant portal hypertension with HVPG > 10 mmHg and/or liver fibrosis on elastography > 25 Kpa should be on NSBB, primarily carvedilol, for the prevention of variceal bleeding. Screening endoscopy is not necessary in patients with compensated liver cirrhosis who use NSBB in the primary prophylaxis of variceal hemorrhage. In case of intolerance to NSBB or contraindications for their use, EBL is indicated as the therapy of choice. EBL should be repeated every 2-4 weeks until the complete eradication of the varix. EGD should be repeated every 3-6 months in the first year after varix eradication (strong recommendation, medium level of evidence) (12). Similar recommendations were given in the Baveno VII consensus, according to which if ascites and low-risk small varices (< 5 mm), as well as high-risk large varices, are present, the therapeutic choice

is NSBB or carvedilol. Dose reduction or discontinuation of NSBB and carvedilol is required when systolic blood pressure falls below 90 mmHg, mean arterial pressure below 65 mmHg and/or the development of hepatorenal syndrome. After stabilization of these parameters, NSBB or carvedilol can be reintroduced into therapy. Also, the recommendation for the use of EBL in the primary prophylaxis of variceal hemorrhage is only for intolerance to NSBB (11). This position has been significantly modified in relation to the Baveno VI consensus recommendations (13).

Comparing the effect of NSBB and EBL, the studies have showed that side effects are more common with EBL, but discontinuation due to intolerance is more common with NSBB. The benefit in terms of survival is greater with NSBB compared to EBL, which is most likely due to the effect of reducing portal pressure. The efficiency of NSBB and EBL in reducing the incidence of first bleeding from EV is similar (12). Thus, meta-analysis by Sharma et al. (14) showed similar efficiency of NSBB and EBL in reducing the risk of first variceal bleeding. This analysis included 3,362 patients with liver cirrhosis and large EV. Another meta-analysis by Villanueva et al. (15) that included 11 randomized controlled trials (RCT) showed that the risk of mortality was lower in the group treated with NSBB than in the group of patients treated with EBL ($p = 0.02$), probably as a consequence reducing the risk of ascites. The risk of first variceal bleeding was similar be-

tween the treated groups of patients ($p = 0.86$). According to other authors, there was no difference in terms of mortality when using EBL and NSBB (16).

The advantage of carvedilol over classic NSBB in the primary prophylaxis of variceal bleeding is that it leads to a greater reduction in portal pressure, but there are not enough randomized studies that would deal with the comparative analysis of carvedilol and NSBB. A study by Reiberger et al. (17) showed that the use of carvedilol in primary prophylaxis in patients who did not respond to propranolol achieved hemodynamic response, which led to improved outcomes in terms of prevention of variceal bleeding, hepatic decompensation, and death. A recent meta-analysis by Tian et al. (18) compared the effect of carvedilol and EBL in the primary prophylaxis of variceal bleeding and found no significant differences in terms of variceal bleeding, mortality, and especially mortality related to variceal bleeding.

Primary prophylaxis of bleeding from GV

In the primary prophylaxis of GV bleeding, ESGE recommends to patients with Sarin GOV2 and IGV1, who do not tolerate NSBB, the option of only observation without treatment, injection of cyanoacrylate (CYA) or endoscopic ultrasound-guided coil therapy with CYA in centers experienced in the application of this technique (weak recommendation, low level of evidence) (12). CYA was shown to be more effective than propranolol in preventing the first bleeding from large GOV2 and IGV; however, there was no difference in survival. There are no indications for the use of balloon-occluded retrograde transvenous obliteration (BRTO) or transjugular intrahepatic portosystemic shunt (TIPS) for primary prophylaxis of GV bleeding (1).

TREATMENT OF ACUTE VARICEAL BLEEDING

Hemodynamic resuscitation

Rupture of esophagogastric varices presents with severe hemorrhage, i.e., hematemesis and/or melena, severe anemia and possible confusion of consciousness. This requires urgent patient care in the intensive care unit. Initially, the patient should be hemodynamically stabilized in order to improve

tissue perfusion, correct intravascular hypovolemia and prevent multiorgan dysfunction. Crystalloid solutions in limited quantities are recommended, which reduce mortality and adverse renal effects compared with saline (19). According to the Baveno VII consensus, red blood cell transfusions should achieve hemoglobin target values of 7-8 g/dl, although other factors such as cardiovascular disorders, age, hemodynamic status and bleeding intensity should be taken into account when assessing hemoglobin target values. Intubation of the patient is indicated before endoscopy in patients with impaired consciousness and active blood vomiting. Extubation should be done as soon as possible after endoscopy (11). In the event of suspected variceal bleeding in patients who are on antiplatelet and anticoagulant therapy, the attitude regarding the discontinuation of this therapy is based on the assessment of the risk of bleeding and thrombosis. According to recently published British Society for Gastroenterology (BSG) and European Society for Gastrointestinal Endoscopy (ESGE) guidelines, aspirin should be discontinued and not reintroduced if given as primary prophylaxis (12, 20, 21). If aspirin is given as secondary cardiovascular prophylaxis, reintroduction of aspirin should be considered in the context of assessing the risk of variceal rebleeding and the risk of thrombosis.

It should be noted that the restoration of normal platelet function after discontinuation of aspirin occurs minimally after 5-7 days. P2Y12 receptor antagonists in patients with coronary artery stents should be returned to therapy within five days because of the high risk of stent occlusion (22).

Vasoactive drugs

In suspected variceal hemorrhage, vasoactive drugs, such as terlipressin or octreotide, should be started as soon as possible and continued for 2-5 days (11). According to some studies that evaluated the effectiveness and safety of vasoactive drugs in acute variceal bleeding, the use of these drugs affected the reduction of in-hospital mortality, overall mortality, better control of variceal bleeding, reduction of variceal rebleeding and reduction of the need for blood transfusions. Octreotide is as effective as terlipressin and vasopressin, but with fewer side effects, especially compared to vasopressin (1, 23, 24).

Antibiotic prophylaxis

Patients with acute variceal bleeding are at high risk of bacterial infection. According to ESGE recommendations, antibiotic prophylaxis with ceftriaxone 1 g per day for up to 7 days is indicated, which implies knowledge of local antibiotic resistance and the patient's possible allergy to this drug (12). The use of ceftriaxone is especially recommended for patients with quinolone-resistant bacterial infections and patients who have previously received quinolones. Bacterial infections lead to an increased risk of varices rebleeding and increase overall mortality. Despite antibiotic prophylaxis, 14% of patients develop bacterial infections, mostly respiratory, within 14 days of bleeding (25). The risk of bacterial infection is very low in patients with Child-Pugh A liver cirrhosis. Chang et al. (26) showed that the incidence of bacterial infection within 14 days and overall mortality within 42 days were not different in patients with Child-Pugh stage A cirrhosis who received antibiotics prophylactically and who received them on an as-needed basis. However, more prospective studies are needed before concluding that antibiotic prophylaxis is not necessary in this subgroup of patients.

Timing of upper gastrointestinal endoscopy

According to ESGE recommendations, in case of suspected variceal hemorrhage, endoscopy should be performed within 12 hours of the presentation of bleeding in a hemodynamically stabilized patient (12). In case of impossibility of hemodynamic stabilization, endoscopy should be performed as soon as possible (11). A systematic review and meta-analysis by Bai et al. (27) on 2,824 patients showed that overall mortality was significantly lower in early endoscopy (within 12 h) compared to delayed endoscopy (after 12 h).

Endoscopic treatment of acute variceal bleeding

A strict recommendation with a high quality of evidence by the ESGE is for the use of EBL in acute variceal bleeding (12). Varicose strangulation, thrombosis, and obliteration are achieved with ligatures. Rings are placed first on varices with signs of recent bleeding or active bleeding. It usually starts from the esophagogastric junction and spirals pro-

ximally for about 2 cm until all varices are ligated (Figure 2 and 3). The interval between ligation sessions is usually 14 days until the varices are completely obliterated or their size reduced to the first degree. After the eradication of the varix, control endoscopies are performed every 3-6 months. With EBL, control of active variceal bleeding is achieved in about 90% of cases (1, 28, 29). Meta-analyses have shown that EBL is superior to endoscopic variceal sclerotherapy (EVS) in terms of rebleeding, complications, and eradication of varices, however, there was no difference in mortality (30). Nevertheless, EBL is associated with a higher incidence of variceal recurrence because obliteration of paraesophageal varices is not possible. Therefore, in many studies, the simultaneous application of EBL and EVS was attempted, but no benefit of the combined therapy was shown, and the participation of complications was increased. Therefore, the conclusion is that simultaneous combined therapy of EBL and EVS is not recommended (31-33). Another approach to the combined therapy of EBL and EVS is the application of a smaller amount of sclerosing agent after size reduction of the varix using EBL. Fewer recurrences of varices would be expected considering that paraesophageal varices are obliterated by sclerotherapy. Also, the use of a smaller amount of sclerosing agent should reduce the frequency of sclerotherapy complications. Thus, according to some studies, EVS can be beneficial if applied to very small varices left after EBL (34-36). Our study showed that in the group of the combination of ligatures and sclerotherapy, there was less recurrence of varices compared to ligation alone (16% vs. 21.7%, respectively), but the difference was not statistically significant. Rebleeding from varices was identical in both groups of patients. The conclusion of our study was that combined therapy has no advantage over EBL alone (37).

Complications after ligation of varices are less frequent and easier than after sclerotherapy. Chest pain and dysphagia after ligation are transient. After sclerotherapy, there are numerous complications: dysphagia, chest pain, feverishness, pleural effusions, ulcers, and esophageal strictures (38).

Hemostatic spray/powder has recently been introduced in the treatment of GI bleeding, primarily bleeding from ulcers and tumors. It is applied through a special catheter. Hemospray is an inert mineral-based powder that absorbs water in contact with blood and adheres to the damaged area. Ac-

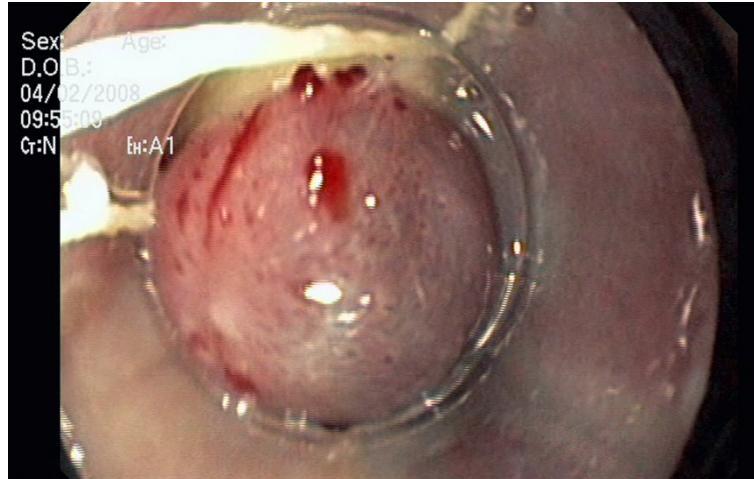


Figure 2. Suction of the esophageal mucosa, submucosa, and the varix (Grgov S)

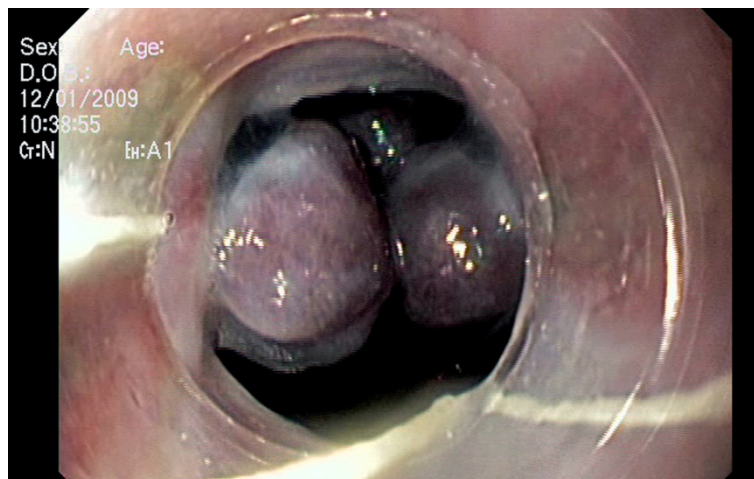


Figure 3. Three ligated varices at the bottom of the esophagus (Grgov S)

According to ESGE recommendations, Hemospray can be used as a bridge to definitive therapy of bleeding from varices (12). This therapy can stabilize a patient with variceal bleeding until definitive endoscopic treatment. For now, the application of hemostatic powders cannot be recommended as the first line of endoscopic therapy due to the lack of evidence of benefit (11).

TREATMENT OF REFRACTORY VARICEAL HEMORRHAGE

Up to 20% of variceal hemorrhage can be refractory to standard therapy due to massive bleeding, inability to establish endoscopic hemostasis or rapid onset of rebleeding (1). Mortality in such cases is 30–50% (39). There are several therapeutic options: repeat endoscopy and hemostasis, balloon tamponade, self-expanding metal stent (SEMS), TIPS, and surgical therapy (Figure 4).

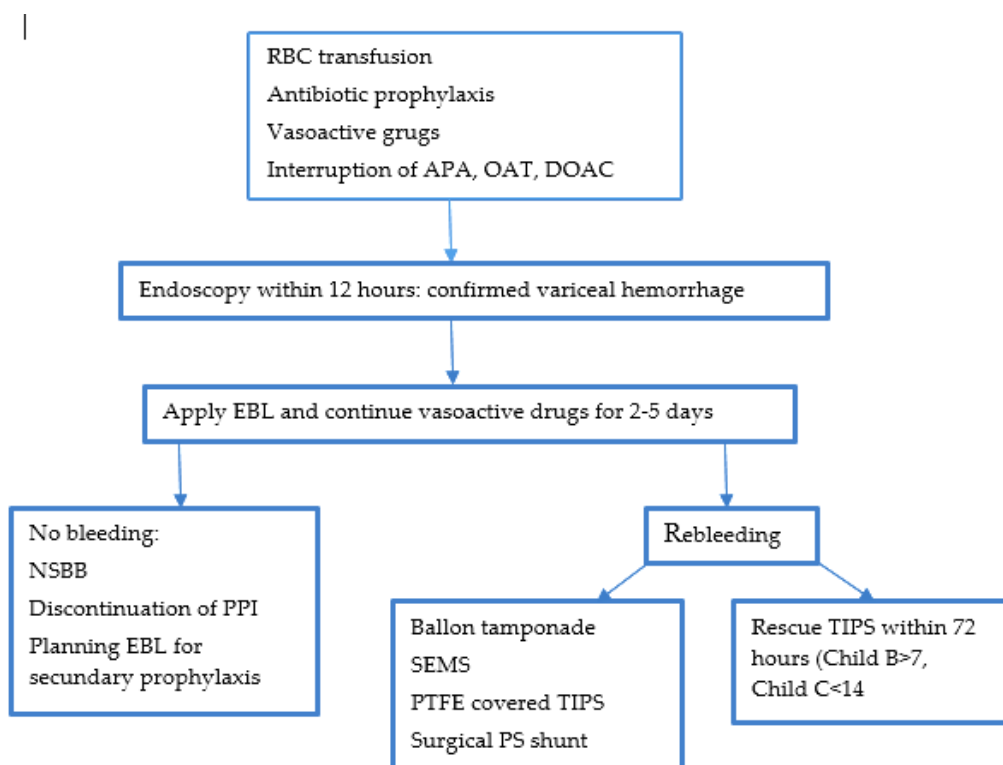


Figure 4. Suspected variceal bleeding (RBC– rubber blood cell; APA–antiplatelet agents; OAT–oral anticoagulant therapy; DOAC–direct oral anticoagulant; EBL–endoscopic band ligation; NSBB–non-selective beta blocker; PPI–proton pump inhibitor; SEMS–self expanding metallic stent; PTFE–covered TIPS, polytetrafluoroethylene-covered TIPS; PS–potosystemic

Balloon tamponade

Balloon tamponade involves the use of a Sengstaken-Blakemore or Minnesota probe. It represents an effective temporary measure in case of failure of endoscopic hemostasis or impossibility of applying endoscopic hemostasis. Balloon tamponade controls bleeding in about 80% of cases. Adverse effects can be serious, such as esophageal ulceration, esophageal perforation, or aspiration pneumonia in up to 20% of patients (3). Balloon tamponade should be stopped in no more than 24 hours, but the rate of rebleeding after removal of balloon tamponade is about 50% (12).

Self-expanding metal stent (SEMS)

The ESGE recommendation for persistent variceal hemorrhage despite the use of vasoactive drugs and endoscopic hemostasis is the use of SEMS, rather than balloon tamponade. The stent can remain in the esophagus for up to 14 days allowing definitive treatment to be planned. Possible side effects

are stent migration and ulceration. SEMS is more expensive option compared to balloon tamponade (12). A systematic review and meta-analysis of five studies showed that the application of SEMS achieved hemostasis in 93.5% of cases, whereas rebleeding was present in 13.2% of cases (40).

Transjugular intrahepatic portosystemic shunt (TIPS)

TIPS is presented as intrahepatic (endovascular) shunt procedure. TIPS is recommended for refractory variceal hemorrhage and a better option is the new version of polytetrafluoroethylene covered TIPS (PTFE-covered TIPS). Rescue TIPS within 72 h, ideally within 24 h, of variceal bleeding is a good option if there are possibilities for it, i.e. if the bleeding is from EV or from type 1 and 2 GV, as well as if the patient is in Child-Pugh C class of liver cirrhosis with less of 14 points, Child-Pugh B class with over 7 points or with HVPG over 20 mmHg at the time of bleeding. TIPS would be ineffective if the patient is in Child-Pugh C cirrhosis with over 14 points, MELD

score over 30, and lactate over 12 mmol/L, even if liver transplantation is certain in the short term. The decision to use TIPS in these patients is case-specific (11).

A retrospective study by Maimore et al. (41) on 144 patients, with a mean MELD score of 18.5 ± 8.3 , of which 8% were in Child-Pugh A class, 38% in Child-Pugh B class and 54% in Child-Pugh C class of cirrhosis, showed failure of TIPS treatment in 16% of cases. Six-week and 12-month mortality was 36% and 42%, respectively. Salvage TIPS was futile in patients with a Child-Pugh score of 14-15.

Surgical treatment

Emergency surgery has limited options in acute variceal bleeding and can be considered as rescue therapy in case of failure of all non-surgical methods including TIPS. Surgery may also be an option in refractory variceal hemorrhage in centers that do not apply radiological interventional procedures (1).

Surgical methods include non-shunt and shunt operations

Non-shunt operations include esophagogastric devascularization, esophageal transection, and splenectomy (Sugiura procedure). These surgeries are rarely the treatment of choice in acute variceal bleeding, but may be salvage therapy when non-surgical and radiologic procedures fail. Also, in cases where it is not possible to perform shunt operations due to extensive portal, splenic, and mesenteric venous thrombosis, devascularization procedures should be considered. Operative mortality is high, especially in patients in the Child C stage of liver cirrhosis, and the Child C stage is also a relative contraindication for this procedure (42). Recent trials have focused on the comparative analysis of laparoscopic and open splenectomy and esophagogastric devascularization. Deng et al. (43) in a retrospective study found no significant difference in hospital mortality due to variceal bleeding between laparoscopic and open surgery. However, with open surgery, there was more intraoperative blood loss, longer hospitalization, and a higher rate of postoperative complications. Luo et al. (44) in a retrospective study that included 30 patients who underwent laparoscopic surgery and 38 patients who underwent open surgery, showed that in both groups of

patients there was a significant improvement of varices, evaluated endoscopically. In the laparoscopic group, there was a shorter operative time, less intraoperative bleeding and fewer postoperative complications. In both groups of patients, there was no rebleeding from the varices and no death one year after surgical treatment.

Surgical shunt operations (extrahepatic shunts) are indicated in patients in Child A class with recurrent variceal bleeding despite the application of all non-surgical methods. Decompressive shunts include total portosystemic shunt, partial portosystemic shunt, and other selective shunts.

To create a lateral-lateral total portocaval shunt, the portal vein and the inferior vena cava are mobilized after dissection and anastomosed. All portal flow is directed through the shunt, which is over 10 mm in diameter, with the portal vein itself serving to drain obstructed hepatic sinusoids. With this intervention, good control of variceal bleeding and ascites is achieved in over 90% of cases. Encephalopathy and progressive liver failure are possible in 40-50% of cases.

The partial portosystemic shunt is with a reduced size of the lateral lateral shunt anastomosis to 8 mm. Portal pressure is reduced to 12 mm Hg and portal flow is maintained in 80% of cases. Prospective randomized controlled studies have shown the control of variceal bleeding in 90% of cases, while maintenance of portal flow reduces the incidence of encephalopathy and liver failure.

Selective shunts enable selective decompression of varices with the aim of controlling bleeding and at the same time maintaining portal hypertension while preserving portal flow of the liver. The most commonly used shunt of this type in refractory variceal hemorrhage and in patients with good liver function is the distal splenorenal shunt (Warren shunt). With this shunt, varix decompression is achieved through the short gastric veins and the splenic vein to the left renal vein. In this way, long-term maintenance of portal flow and liver function is ensured with a significantly lower incidence of encephalopathy (10-15%) compared to total portosystemic shunts (45).

TREATMENT OF ACUTE BLEEDING FROM GV

The initial treatment of bleeding from GV does not differ from the treatment of bleeding from EV (restrictive approach to blood transfusions, vasoactive

drugs, antibiotic prophylaxis). Bleeding from GV is less frequent than bleeding from EV but is significantly more severe with higher mortality and more frequent treatment failure (46).

Initial hemostasis in bleeding from GOV1 is achieved with approximately equal efficacy with cyanoacrylate (CYA) tissue adhesive and EBL. In terms of rebleeding from GOV1, CYA has an advantage over EBL. In GOV2 and IGV, the therapy of choice is CYA, which is in the standard form of N-butyl-2-cyanoacrylate. A better alternative is 2-octyl cyanoacrylate, which has a longer polymerization period (11).

CYA injections can also be administered under endoscopic ultrasound (EUS) control. According to many studies, EUS-guided injection of CYA allows for a smaller volume of given CYA, which may affect lower number of complications and less involvement of variceal rebleeding (47, 48).

Recently, the use of EUS-guided coil injections with or without CYA has begun. Coil enables primary hemostasis, keeping CYA inside the varix, thus reducing the risk of embolization. According to a larger retrospective study by Bhat et al. (49), which analyzed 152 patients over a six-year period, it was shown that combined therapy with EUS-guided coil injections and CYA, in high-risk fundic varices, is highly effective in the hemostasis of active bleeding both in primary and secondary bleeding prophylaxis. After the obliteration of the varix was achieved during a longer follow-up period, rebleeding occurred in only 3% of cases. The conclusion of this study is that combination therapy appears to be safe and may reduce the risk of embolization with CYA.

In case of failure of endoscopic hemostasis and early recurrent bleeding from GV according to ESGE recommendations, rescue therapy would be TIPS and balloon-occluded retrograde transvenous embolization (BRTO). Comparing TIPS and BRTO, it can be said that TIPS is associated with a higher risk of encephalopathy, while BRTO is associated with EV deterioration over a longer period of time. Patient selection is important, but due to insufficient comparative data, specific selection criteria are lacking (12).

One randomized controlled trial showed that portocaval shunt surgery demonstrated better control of variceal bleeding, longer survival, and less involvement of encephalopathy compared with emergency TIPS procedure (50). However, further studies are needed before making a decision on the use of portocaval shunt surgery as a salvage proce-

dure after failure of initial treatment of variceal bleeding.

SECONDARY PROPHYLAXIS OF VARICEAL BLEEDING

The indication for the use of secondary prophylaxis of variceal bleeding is the prevention of rebleeding, which occurs in 60% of cases in the first year with a mortality rate of 33%. After repair of acute variceal bleeding, the recommendation of ESGE is that in order to prevent secondary bleeding, NSBB (propranolol) or carvedilol should be used in combination with EBL (strict recommendation, high level of evidence) (12). This position is based on several meta-analyses, according to which combined therapy with NSBB and EBL is superior to monotherapy in EV bleeding (51–53). In the case of recurrent ascites, the treatment of choice in the secondary prophylaxis of variceal bleeding is the application of TIPS. The benefit of TIPS should be evaluated even without the presence of recurrent ascites in case of intolerance or lack of response to NSBB (11).

Regarding the secondary prophylaxis of bleeding from cardiofundal varices (GOV2, IGV1), there is a lack of well-documented data that would be based on evidence from larger studies, and the approach is individual and includes the use of endoscopic CYA injections with or without NSBB, EUS-guided coil injections and CYA, TIPS, and BRTO (12).

CONCLUSION

The most common and severe cause of GI bleeding in patients with portal hypertension is ruptured esophagogastric varices. In patients with advanced liver disease and endoscopically diagnosed high-risk varices, primary prophylaxis of bleeding from varices is carried out using NSBB (propranolol) or carvedilol, while in case of intolerance to NSBB or contraindications to their use, EBL should be used. NSBB or EBL significantly reduce the risk of a first episode of variceal bleeding. In the primary prophylaxis of GV bleeding, in patients with Sarin GOV2 and IGV1, who do not tolerate NSBB, the option of only monitoring without treatment, CYA injections or EUS-guided coil therapy with CYA in centers with experience in the application of this technique is possible. Treatment of acute variceal bleeding involves hemodynamic re-

suscitation of the patient, antibiotic prophylaxis and the earliest possible application of vasoactive drugs. Endoscopy after hemodynamic stabilization would ideally be performed within 12 hours of the presentation of bleeding and EBL applied. Further studies of the role of hemostatic spray/powder in the treatment of acute and refractory variceal hemorrhage are needed. In case of failure of the initial endoscopic treatment, repeat endoscopy and hemostasis should be attempted, followed by balloon tamponade, SEMS, TIPS, and surgical therapy. SEMS may be a better option than balloon tamponade, but larger studies are needed to evaluate the cost-effectiveness of SEMS. Rescue TIPS within 72 h, ideally within 24 h, of variceal bleeding is a good option if the bleeding is from EV or from type 1 and 2 GV, as well as if the patient is in Child-Pugh C class of liver cirrhosis with less than 14 points, Child-Pugh B class with over 7 points or with HVPG over 20 mmHg at the

time of bleeding. Emergency surgery (shunt and non-shunt operations) has limited possibilities in acute variceal bleeding and can be considered as rescue therapy in case of failure of all non-surgical methods including TIPS. Surgery may also be an option in refractory variceal hemorrhage in centers that do not apply radiological interventional procedures. In GOV2 and IGV, the therapy of choice is CYA. Further trials of EUS-guided coil injections with or without CYA in the treatment of GV bleeding are needed. The latest recommendation for secondary prophylaxis of EV bleeding is combined therapy with NSBB or carvedilol and EBL. In case of recurrent ascites, the therapy of choice is TIPS. In the secondary prophylaxis of bleeding from cardiofundal varices (GOV2, IGV1), the approach is currently individual due to the lack of more valid evidence from larger studies on the type of therapy.

References

1. Pallio S, Melita G, Shahini E, et al. Diagnosis and management of esophagogastric varices. Review. *Diagnostics (Basel)* 2023; 13(6):1031. <https://doi.org/10.3390/diagnostics13061031>
2. Nusrat S, Khan, MS, Fazili J, et al. Cirrhosis and its complications: Evidence based treatment. *World J Gastroenterol* 2014; 20(18):5442–60. <https://doi.org/10.3748/wjg.v20.i18.5442>
3. Garcia-Tsao G, Abraldes JG, Berzigotti A, et al. Portal hypertensive bleeding in cirrhosis: Risk stratification, diagnosis, and management: 2016 practice guidance by the American Association for the study of liver diseases. *Hepatology* 2017; 65(1):310-35. <https://doi.org/10.1002/hep.28906>
4. Yue X, Wang Z, Li J, et al. Esophageal variceal ligation plus sclerotherapy vs. ligation alone for the treatment of esophageal varices. *Front Surg* 2022; 9:928873. <https://doi.org/10.3389/fsurg.2022.928873>
5. Sarin SK, Lahoti D, Saxena SP, et al. Prevalence, classification and natural history of gastric varices: A long-term follow-up study in 568 portal hypertension patients. *Hepatology* 1992; 16(6):1343-9. <https://doi.org/10.1002/hep.1840160607>
6. Mishra SR, Sharma BC, Kumar A, et al. Primary prophylaxis of gastric variceal bleeding comparing cyanoacrylate injection and beta blockers: A randomized controlled trial. *J Hepatol* 2011; 54(6):1161-7. <https://doi.org/10.1016/j.jhep.2010.09.031>
7. Biecker E. Portal hypertension and gastrointestinal bleeding: diagnosis, prevention and management. *World J Gastroenterol* 2013; 19(31):5035-50. <https://doi.org/10.3748/wjg.v19.i31.5035>
8. Ding NS, Nguyen T, Iser, DM, et al. Liver stiffness plus platelet count can be used to exclude high-risk oesophageal varices. *Liver Int* 2016; 36(2):240-5. <https://doi.org/10.1111/liv.12916>
9. Robic, MA, Procopet B, Métivier S, et al. Liver stiffness accurately predicts portal hypertension related complications in patients with chronic liver disease: A prospective study. *J Hepatol* 2011; 55(5):1017-24. <https://doi.org/10.1016/j.jhep.2011.01.051>
10. Paternostro R, Reiberger T, Bucsics T. Elastography-based screening for esophageal varices in patients with advanced chronic liver disease. *World J Gastroenterol* 2019; 25(3):308-29. <https://doi.org/10.3748/wjg.v25.i3.308>
11. De Franchis R, Bosch J, Garcia-Tsao G, et al. Baveno VII - renewing consensus in portal hypertension. *J Hepatol* 2022; 76(4):959-74. <https://doi.org/10.1016/j.jhep.2021.12.022>
12. Gralnek IM, Duboc MC, Garcia-Pagan JC, et al. Endoscopic diagnosis and management of esophagogastric variceal hemorrhage: European Society of Gastrointestinal Endoscopy (ESGE) Guideline. *Endoscopy* 2022; 54(11):1094-120. <https://doi.org/10.1055/a-1939-4887>
13. De Franchis R; Baveno VI Faculty. Expanding consensus in portal hypertension Report of the Baveno VI consensus workshop: stratifying risk and individualizing care for portal hypertension. *J Hepatol* 2015; 63(3):743-52. <https://doi.org/10.1007/978-3-319-23018-4>
14. Sharma M, Singh S, Desai V, et al. Comparison of therapies for primary prevention of esophageal variceal bleeding: a systematic review and network meta-analysis. *Hepatology* 2019; 69(4):1657-75. <https://doi.org/10.1002/hep.30220>
15. Villanueva C, Sapena V, Lo GH, et al. Stratified efficacy of first-line therapy to prevent first variceal bleeding according to previous

- decompensation of cirrhosis. A competing-risk meta-analyses of individual participant data. *J Hepatol* 2022; 77(S1):625-6.
[https://doi.org/10.1016/S0168-8278\(22\)01568-9](https://doi.org/10.1016/S0168-8278(22)01568-9)
16. Funakoshi N, Dunny Y, Valats JC, et al. Meta-analysis: beta-blockers versus banding ligation for primary prophylaxis of esophageal variceal bleeding. *Ann Hepatol* 2012; 11(3):369-83.
[https://doi.org/10.1016/S1665-2681\(19\)30934-2](https://doi.org/10.1016/S1665-2681(19)30934-2)
17. Reiberger T, Ulbrich G, Ferlitsch A, et al. Carvedilol for primary prophylaxis of variceal bleeding in cirrhotic patients with haemodynamic non-response to propranolol. *Gut* 2013; 62(11):1634-41.
<https://doi.org/10.1136/gutjnl-2012-304038>
18. Tian S, Li R, Guo Y, et al. Carvedilol vs endoscopic band ligation for the prevention of variceal bleeding: A meta-analysis. *Ther Clin Risk Manag* 2019; 15:191-200.
<https://doi.org/10.2147/TCRM.S193196>
19. Hammond DA, Lam SW, Rech MA, et al. Balanced Crystalloids Versus Saline in Critically Ill Adults: A Systematic Review and Meta-analysis. *Ann Pharmacother* 2020; 54(1):5-13.
<https://doi.org/10.1177/1060028019866420>
20. Veitch AM, Radaelli F, Alikhan R, et al. Endoscopy in patients on antiplatelet or anticoagulant therapy: British Society of Gastroenterology (BSG) and European Society of Gastrointestinal Endoscopy (ESGE) guideline update. *Gut* 2021; 70(9):1611-28.
<https://doi.org/10.1136/gutjnl-2021-325184>
21. Dasa O, Pepine CJ, Pearson TA. Aspirin in primary prevention: what changed? A critical appraisal of current evidence. *Am J Cardiol* 2021; 141:38-48.
<https://doi.org/10.1016/j.amjcard.2020.11.014>
22. Eisenberg MJ, Richard PR, Libersan D, Filion KB. Safety of short-term discontinuation of antiplatelet therapy in patients with drug-eluting stents. *Circulation* 2009; 119(12):1634-42.
<https://doi.org/10.1161/CIRCULATIONAHA.108.813667>
23. Huaranga-Marcelo J, Huaman MR, Brañez-Condorena A, et al. Vasoactive Agents for the Management of Acute Variceal Bleeding: A Systematic Review and Meta-analysis. *J. Gastrointestin. Liver Dis* 2021; 30(1):110-21.
<https://doi.org/10.15403/jgld-3191>
24. Yan P, Tian X, Li J. Is additional 5-day vasoactive drug therapy necessary for acute variceal bleeding after successful endoscopic hemostasis?: A systematic review and meta-analysis. *Medicine (Baltimore)* 2018; 97(41):e12826.
<https://doi.org/10.1097/MD.00000000000012826>
25. Lee S, Saxinger L, Ma M, et al. Bacterial infections in acute variceal hemorrhage despite antibiotics—a multicenter study of predictors and clinical impact. *United Eur Gastroenterol* 2017; 5(8):1090-9.
<https://doi.org/10.1177/2050640617704564>
26. Chang TS, Tsai YH, Lin YH, et al. Limited effects of antibiotic prophylaxis in patients with Child-Pugh class A/B cirrhosis and upper gastrointestinal bleeding. *PLoS One* 2020; 15(2):e0229101.
<https://doi.org/10.1371/journal.pone.0229101>
27. Bai Z, Wang R, Cheng G, et al. Outcomes of early versus delayed endoscopy in cirrhotic patients with acute variceal bleeding: A systematic review with meta-analysis. *Eur J Gastroenterol Hepatol* 2021; 33(1S Suppl 1):e868-76.
<https://doi.org/10.1097/MEG.0000000000002282>
28. Kovacs TOG, Jensen DM. Varices: Esophageal, Gastric, and Rectal. *Clin Liver Dis* 2019; 23(4):625-42.
<https://doi.org/10.1016/j.cld.2019.07.005>
29. Nett A, Binmoeller KF. Endoscopic Management of Portal Hypertension-related Bleeding. *Gastroint Endosc Clin N Am* 2019; 29(2):321-37.
<https://doi.org/10.1016/j.giec.2018.12.006>
30. Dai C, Liu WX, Jiang M, Sun MJ. Endoscopic variceal ligation compared with endoscopic injection sclerotherapy for treatment of esophageal variceal hemorrhage: A meta-analysis. *World J Gastroenterol* 2015; 21(8):2534-41.
<https://doi.org/10.3748/wjg.v21.i8.2534>

31. Karsan HA, Morton SC, Shekelle PG, et al. Combination endoscopic band ligation and sclerotherapy compared with endoscopic band ligation alone for the secondary prophylaxis of esophageal variceal hemorrhage: a meta-analysis. *Dig Dis Sci* 2005; 50(2):399-406. <https://doi.org/10.1007/s10620-005-1618-9>
32. Djurdjević D, Janošević S, Dapčević B, et al. Combined ligation and sclerotherapy versus ligation alone for eradication of bleeding esophageal varices: a randomized and prospective trial. *Endoscopy* 1999; 31(4):286-90. <https://doi.org/10.1055/s-1999-22>
33. Singh P, Pooran N, Indaram A, Bank S. Combined ligation and sclerotherapy versus ligation alone for secondary prophylaxis of esophageal variceal bleeding: a meta-analysis. *Am J Gastroenterol* 2002; 97(3):623-9. <https://doi.org/10.1111/j.1572-0241.2002.05540.x>
34. Lo GH, Lai KH, Cheng JS, et al. The additive effect of sclerotherapy to patients receiving repeated endoscopic variceal ligation: a prospective, randomized trial. *Hepatology* 1998; 28(2):391-5. <https://doi.org/10.1002/hep.510280215>
35. Hou MC, Chen WC, Lin HC, et al. A new "sandwich" method of combined endoscopic variceal ligation and sclerotherapy versus ligation alone in the treatment of esophageal variceal bleeding: a randomized trial. *Gastrointest Endosc* 2001; 53(6):572-8. <https://doi.org/10.1067/mge.2001.114058>
36. Cheng YS, Pan S, Lien GS, et al. Adjuvant sclerotherapy after ligation for the treatment of esophageal varices: a prospective, randomized long-term study. *Gastrointest Endosc* 2001; 53(6):566-71. <https://doi.org/10.1067/mge.2001.114061>
37. Grgov S, Stamenković P. Does sclerotherapy of remnant little oesophageal varices after endoscopic ligation have impact on the reduction of recurrent varices? Prospective study. *Srp Arh Celok Lek* 2011; 139(5-6):328-32. <https://doi.org/10.2298/SARH1106328G>
38. Bosch J, Berzigotti A, Garcia-Pagan JC, Abraldes JG. The management of portal hypertension: rational basis, available treatments and future options. *J Hepatol* 2008; 48(Suppl 1):S68-92. <https://doi.org/10.1016/j.jhep.2008.01.021>
39. Escorse À, Pavel O, Cárdenas A, et al. Esophageal balloon tamponade versus esophageal stent in controlling acute refractory variceal bleeding: A multicenter randomized, controlled trial. *Hepatology* 2016; 63(6):1957-67. <https://doi.org/10.1002/hep.28360>
40. Shao XD, Qi XS, Guo XZ. Esophageal Stent for Refractory Variceal Bleeding: A Systemic Review and Meta-Analysis. *Bio Med Res Int* 2016; 2016:4054513. <https://doi.org/10.1155/2016/4054513>
41. Maimone S, Saffioti F, Filomia R, et al. Predictors of Re-bleeding and Mortality Among Patients with Refractory Variceal Bleeding Undergoing Salvage Transjugular Intrahepatic Portosystemic Shunt (TIPS). *Dig Dis Sci* 2019; 64(5):1335-45. <https://doi.org/10.1007/s10620-018-5412-x>
42. Selzner M, Tuttle-Newhall JE, Dahm F, et al. Current indication of a modified Sugiura procedure in the management of variceal bleeding. *J Am Coll Surg* 2001; 193(2):166-73. [https://doi.org/10.1016/S1072-7515\(01\)00937-1](https://doi.org/10.1016/S1072-7515(01)00937-1)
43. Deng ZC, Jiang WZ, Chen L, et al. Laparoscopic VS. Open splenectomy and oesophagogastric devascularisation for liver cirrhosis and portal hypertension: A retrospective cohort study. *Int J Surg* 2020; 80:79-83. <https://doi.org/10.1016/j.ijssu.2020.06.026>
44. Luo HP, Zhang ZG, Long X, et al. Combined Laparoscopic Splenectomy and Esophagogastric Devascularization versus Open Splenectomy and Esophagogastric Devascularization for Portal Hypertension due to Liver Cirrhosis. *Curr Med Sci* 2020; 40(1):117-22. <https://doi.org/10.1007/s11596-020-2154-8>
45. Rodge GA, Goenka U, Goenka M. Management of refractory variceal bleed in cirrhosis. *J Clin Exp Hepatol* 2022; 12(2):595-602. <https://doi.org/10.1016/j.jceh.2021.08.030>
38. Bosch J, Berzigotti A, Garcia-Pagan JC, Abraldes JG. The management of portal hypertension:

46. Garcia-Pagán JC, Barrufet, M, Cardenas A, Escorsell A. Management of gastric varices. *Clin Gastroenterol Hepatol* 2014; 12(6):919-e52. <https://doi.org/10.1016/j.cgh.2013.07.015>
47. Gubler C, Bauerfeind, P. Safe and successful endoscopic initial treatment and long-term eradication of gastric varices by endoscopic ultrasound-guided Histoacryl (N-butyl-2-cyanoacrylate) injection. *Scand J Gastroentero* 2014; 49(9):1136-42. <https://doi.org/10.3109/00365521.2014.929171>
48. Bick BL, Al-Haddad M, Liangpunsakul S, et al. EUS-guided fine needle injection is superior to direct endoscopic injection of 2-octyl cyanoacrylate for the treatment of gastric variceal bleeding. *Surg Endosc* 2019; 33(6):1837-45. <https://doi.org/10.1007/s00464-018-6462-z>
49. Bhat YM, Weilert F, Fredrick RT, et al. EUS-guided treatment of gastric fundal varices with combined injection of coils and cyanoacrylate glue: a large U.S. experience over 6 years. *Gastrointest Endosc* 2016; 83(6):1164-72. <https://doi.org/10.1016/j.gie.2015.09.040>
50. Orloff MJ, Hye RJ, Wheeler HO, et al. Randomized trials of endoscopic therapy and transjugular intrahepatic portosystemic shunt versus portacaval shunt for emergency and elective treatment of bleeding gastric varices in cirrhosis. *Surgery* 2015; 157(6):1028-45. <https://doi.org/10.1016/j.surg.2014.12.003>
51. Cheung J, Zeman M, van Zanten SV, Tandon P. Systematic review: secondary prevention with band ligation, pharmacotherapy or combination therapy after bleeding from oesophageal varices. *Aliment Pharmacol Ther* 2009; 30(6):577-88. <https://doi.org/10.1111/j.1365-2036.2009.04075.x>
52. Thiele M, Krag A, Rohde U, Gluud LL. Meta-analysis: banding ligation and medical interventions for the prevention of rebleeding from oesophageal varices. *Aliment Pharmacol Ther* 2012; 36(10):1155-65. <https://doi.org/10.1111/j.1365-2036.2012.05074.x>
53. Puente A, Hernández-Gea V, Graupera I, et al. Drugs plus ligation to prevent rebleeding in cirrhosis: an updated systematic review. *Liver Int* 2014; 34(6):823-33. <https://doi.org/10.1111/liv.12452>

Article info

Received: March 31, 2024

Revised: July 18, 2024

Accepted: August 23, 2024

Online first: March 13, 2025

Najnovije preporuke u profilaksi i lečenju krvarenja iz ezofagogastričnih variksa

Ivan Grgov¹, Daniela Benedeto Stojanov^{2,3}, Biljana Radovanović Dinić^{2,3}, Milica Grgov⁴,
Saša Grgov⁵, Tomislav Tasić⁶

¹Opšta bolnica Leskovac, Služba opšte hirurgije sa traumatologijom, Leskovac, Srbija

²Univerzitetski klinički centar Niš, Klinika za gastroenterologiju i hepatologiju, Niš, Srbija

³Univerzitet u Nišu, Medicinski fakultet, Niš, Srbija

⁴Univerzitetski klinički centar Niš, Klinika za pulmologiju, Niš, Srbija

⁵Dom zdravlja „VIP Medical“, Leskovac, Srbija

⁶Opšta bolnica Leskovac, Služba interne medicine, Odeljenje gastroenterologije i hepatologije, Leskovac, Srbija

SAŽETAK

Uvod. Ezofagogastrični variksi razvijaju se kod 50%–60% bolesnika sa cirozom jetre, a 30% njih ima jednu epizodu hemoragije variksa u periodu od dve godine nakon postavljanja dijagnoze variksa. Cilj rada bio je da prikaže najnovije stavove u tretmanu ezofagogastričnih variksa.

Pregled literature. Prevencija prvog krvarenja iz ezofagijalnih variksa (EV) podrazumeva primenu neselektivnih beta-blokatora (engl. *non-selective beta-blockers* – NSBB) ili karvedilola. U slučaju netolerancije ili kontraindikacija prilikom primene treba uraditi endoskopsko ligiranje prstenovima (engl. *endoscopic band ligation* – EBL). Prilikom akutnog krvarenja iz variksa treba uraditi endoskopiju, najpogodnije unutar 12 sati od prezentacije krvarenja, i primeniti EBL. U slučaju refraktarne hemoragije (oko 20%) potrebni su ponovna endoskopija i hemostaza ili tamponada balonom, samoekspandirajući metalni stent (engl. *self-expandable metallic stent* – SEMS), TIPS (engl. *transjugular intrahepatic portosystemic shunt* – TIPS) i hirurška terapija. Krvarenje iz gastričnih variksa (GV) ređe je od krvarenja iz EV-a, ali je i znatno teže, sa višim mortalitetom i češćim neuspelim tretmanima. Terapija izbora jeste primena cijanoakrilata (engl. *cyanoacrylates* – CYA), koji se može aplikovati pod kontrolom endoskopske ultrasonografije (engl. *endoscopic ultrasound* – EUS). U ispitivanju su korišćene injekcije kalemovima sa cijanoakrilatom ili bez cijanoakrilata. Kod sekundarne profilakse krvarenja iz EV-a treba primeniti NSBB u kombinaciji sa EBL-om. Kod sekundarne profilakse krvarenja iz kardiofundalnih variksa pristup je individualan.

Zaključak. Terapiju izbora kod primarne prevencije krvarenja iz EV-a predstavlja NSBB, dok je kombinovana terapija (NSBB i EBL) terapija izbora kod sekundarne profilakse krvarenja. CYA je terapija izbora kod krvarenja iz GV-a. Refraktarna variksna hemoragija zahteva primenu mnogih terapijskih modaliteta.

Ključne reči: ezofagogastrični variksi, profilaksa, tretman