

ASYMPTOMATIC "GIANT" PHEOCHROMOCYTOMA DISCOVERED AS ADRENAL INCIDENTALOMA-CASE REPORT AND LITERATURE REVIEW*Danijela Radojković^{1,2}, Milan Radojković^{1,3}*

Adrenal gland tumours, revealed during radiological procedures in patients without previous suspicion for adrenal disease, are known as adrenal incidentalomas (AI). Asymptomatic pheochromocytoma-incidentoma is usually smaller than 10 mm. Incidentally found large pheochromocytoma without any clinical signs is the rarity.

Herein, a young woman is presented, with a tumour in the right adrenal gland, size 60x70 mm, discovered on the abdominal sonogram, performed during a regular systematic examination. Computed tomography confirmed "giant" tumour, size 70x74 mm, with cystic and necrotic areas and inhomogeneous contrast captivity. Besides discrete elevated vanillylmandelic acid (VMA) level in 24 hours diuresis, all the results of the endocrine evaluation were in normal range. The patient underwent [¹³¹I]-meta-iodobenzylguanidine ([¹³¹I]-MIBG) scintigraphy which was indicative for right pheochromocytoma. After adequate preoperative preparation, right adrenalectomy was performed. The procedure and postoperative course went without complications, and pheochromocytoma was confirmed by histopathological examination.

It appears that frequency of AI is constantly rising in the last few decades, thanks to widely used radiological diagnostic techniques. Even though the most of AI are nonfunctional, we should always keep in mind that under clinical "mute" adrenal tumours, malignant or secreting lesions could hide. A thorough examination of each incidentally revealed adrenal mass can prevent potential oversight and provide proper treatment.

Acta Medica Medianae 2019;58(2):82-88.

Key words: *asymptomatic pheochromocytoma, incidentaloma*

¹University of Niš, Faculty of medicine, Niš, Serbia

²Clinic of Endocrinology, Diabetes and Metabolic Disorders, Clinical Centre Niš, Niš, Serbia

³Surgery Clinic, Clinical Centre Niš, Niš, Serbia

Contact: Danijela Radojković
Sestre Baković 14/28, 18000 Niš, Serbia
E-mail: dr.danijela3@gmail.com

Introduction

Tumours localised in adrenal gland, revealed during radiological procedures in patients without previous suspicion for adrenal disease are known as adrenal incidentalomas (AI).

Along with technology advances and frequent radiological imaging, detection of AI is significantly increased (1). After diagnosed AI, two crucial tasks are:

1. to distinguish functional from nonfunctional adrenal tumour and

2. to conclude whether it is benign or malignant one. Usually, AI are hormonal inactive adenomas (74-82.2 %), followed by Cushing syndrome (CS 6-7 %), pheochromocytoma (4.7-7.2 %), aldosteronomas (1.2-4.6 %), adrenocortical carcinoma (ACC 4.8 %), and metastatic lesions (2.3 %) (2, 3).

Pheochromocytomas are tumours that arise from the adrenal medulla. The most common localization is the abdomen, where adrenal glands are target places for 90 % of these tumours, usually unilateral. Since the majority of pheochromocytomas produce and secrete catecholamines, hallmarks of clinical presentation are symptoms associated with catecholamine excesses like hypertension, headache, sweating, tachycardia, pallor and panic attacks. Therefore, each incidentally revealed adrenal mass should be thoroughly examined and screened for pheochromocytoma.

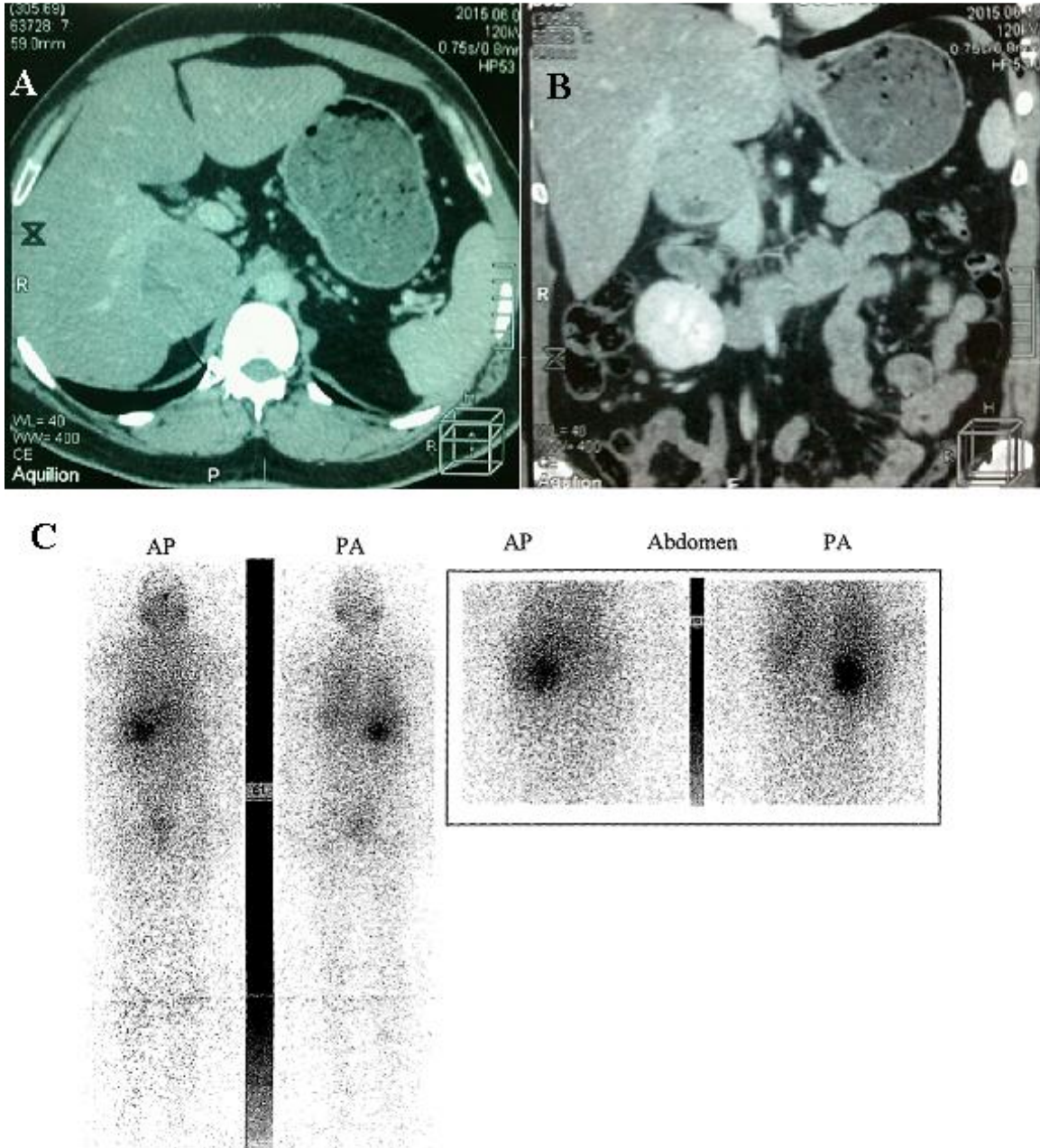
Herein, we present a young woman with clinically "silent" pheochromocytoma and discuss diagnostic procedures along with treatment.

The patient has given informed consent that all data about her diagnostic procedures and treatment could be collected and published. All procedures performed in the study were in accordance with the ethical standards of the institutional and national research committee.

Patient case report

During regular systematic examination in a young woman (32 years old) an abdominal sonogram was performed, which revealed the right adre-

nal mass, size 60x70 mm. Computed tomography (CT) confirmed "giant" tumour, size 70x74 mm, with cystic and necrotic areas and inhomogeneous contrast captivity (Figure 1A and 1B).



A. CT scan of right adrenal tumour, transverse plane. B. CT scan of right adrenal tumour, coronal plane. C. [131I]-MIBG scan of right adrenal pheochromocytoma

Figure 1. Visualization diagnostic procedures

She was admitted to Endocrinology Clinic, Clinical Centre, Niš for further examination. The patient's medical history of any relevant illnesses, including hypertension, was negative. Even though physical examination revealed obesity (BMI 32) body weight was stable, without weight gain. There were no symptoms and signs such as hirsutism, purple striae, hair loss, or oedema. The blood pressure (120/80 mmHg) heart rate (80/min) and respiratory rate (18/min) were normal. Family history was positive for diabetes mellitus type 2, hypertension and obesity (patient's parents). Initial laboratory testing (blood cell count, electrolytes, urea, creatinine, hepatogram, amylase, lipids, and glycaemia) was normal, except for increased fasting plasma glucose (6.4 mmol/l). Performed oral glucose tolerance test (OGTT) revealed impaired glucose tolerance (IGT) with hyperinsulinemia in the second hour of the

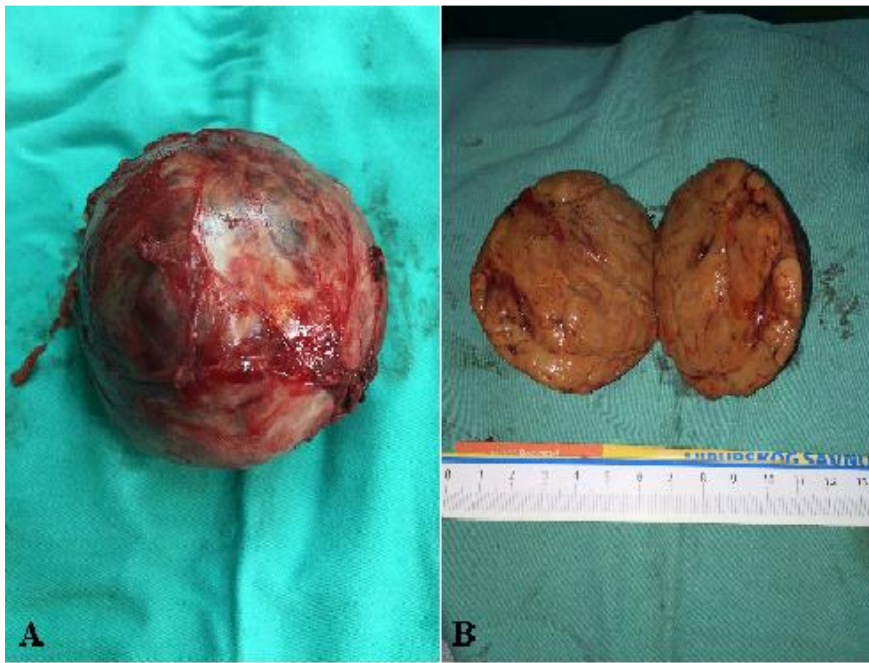
OGTT (plasma glucose level was 8.4 mmol/l and insulin concentration was 172.7 uU/ml; reference value: 2.6-24.90 uU/ml). Further endocrine evaluation included plasma cortisol assay, adrenocorticotrophic hormone (ACTH), plasma catecholamines (adrenaline, noradrenaline and dopamine), 24 hours urinary catecholamine metabolite (vanillylmandelic acid – VMA), sodium, potassium, calcium, phosphorus, parathyroid hormone (PTH), calcitonin, chromogranin A (CgA), thyroid stimulating hormone (TSH) and insulinemia during OGTT. Beside discrete elevated VMA level, all the results of the endocrine evaluation were in normal range and shown in Table 1. Basal cortisol level was significantly suppressed after low-dose dexamethasone (1 mg) test (cortisol level was 470.2 nmol/l before DST and 52 nmol/l after; reference range 150-638 nmol/l).

Table 1. Initial endocrine evaluation

Parameter	Result	Reference range
Plasma Cortisol at 08, 16 and 23h (nmol/L)	470.2/ 225.6/ and 96.0	150 - 638, 80 - 388
VMA (µmol/D24h)	68.7	0 - 68.6
plasmaAdrenalin (pg/mL)	78.0	<100
plasmaNoradrenalin (pg/mL)	523.3	<600
plasmaDopamine (pg/mL)	102.7	<100
ACTH (pg/mL)	31.52	7.2 - 63.3
PTH (pg/mL)	42	8 - 76
TSH (mIU/L)	4.296	0.4 - 4.60
Calcium (mmol/L)	2.43	2.2 - 2.65
Phosphorus (mmol/L)	0.98	0.80 - 1.55
Potassium (mmol/L)	4.3	3.5 - 5.5
Calcitonin (pg/mL)	0.1	<10
Chromogranin (ng/mL)	12.0	19 - 98

Further investigation included [¹³¹I]-meta-iodobenzylguanidine ([¹³¹I]-MIBG) scintigraphy which was indicative for right adrenal pheochromocytoma. (Figure 1C). According to the institution protocol, which we reported in our previous publication standard preoperative preparation was started with 10mg phenoxybenzamine daily (4). The dose was gradually increased up to 60 mg (30 mg two times a day). Following two weeks, during thorough blood pressure monitoring, nor hypertension, neither orthostatic hypotension was verified. Performed ECG and echocardiography were normal. Right adrenalectomy was performed, with no significant change in

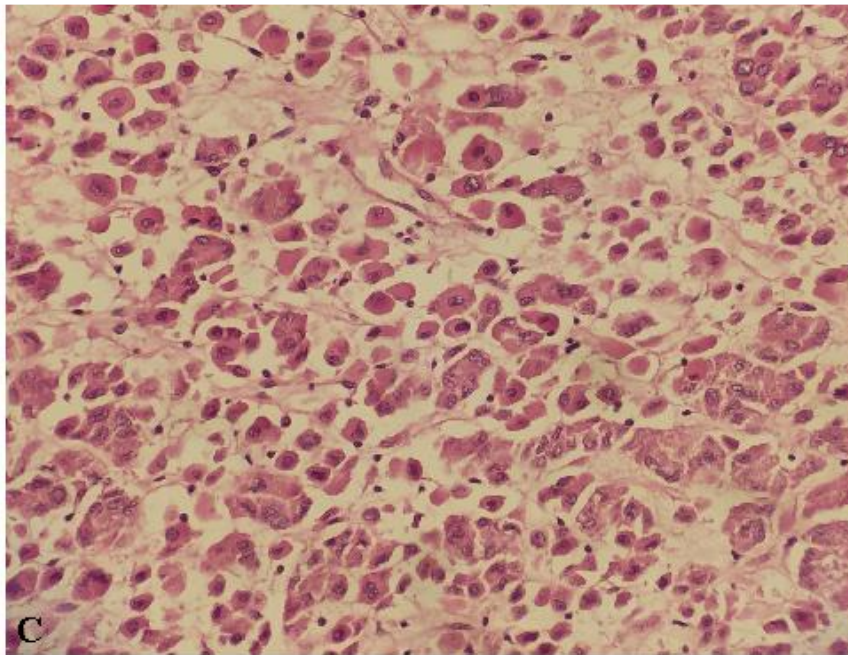
blood pressure during the procedure. The tumour was firm and well encapsulated. Areas of haemorrhages and necrosis within the tumour, typical for larger pheochromocytomas, gave spotted and dark red appearance. There were no intraoperative signs of tumour growing into nearby areas or spreading to lymph nodes. The surgical diagnosis was localized benign adrenal tumour, highly suspicious of pheochromocytoma (Figure 2 A and B). The procedure and postoperative period went without complications, and pheochromocytoma was confirmed by histopathological examination (Figure 2C).



A. Adrenal gland with the tumour.

B. Intersected adrenal gland with tumour

Figure 2A, 2B. Macroscopic and histopathological findings



C. Histopathological examination: pheochromocytoma

Figure 2C. Macroscopic and histopathological findings

Discussion

A number of newly diagnosed patients with AI is growing along with technological advances and available radiology imaging for various reasons. Once verified, AI requires appropriate diagnostic approach. Biochemical and endocrine evaluation should reveal if the tumour has hormonal activity, and further imaging examination will estimate its size and potential malignancy. Based on these features, the decision about surgical removal should be made.

Imaging examination

Abdominal ultrasonography (USG) is usually the first radiology procedure which discovers AI. Enlargement of adrenal glands greater than 2 cm can be detected by USG, but this radiological technique cannot characterize adrenal lesions with high precision (5). Based on the USG findings adrenal tumour was suspected in our patient and CT was performed. This radiological method is much more informative than USG. Unenhanced adrenal CT can provide data about tumour features such as size, shape, radiation attenuation coefficient (in Hounsfield units - HU) and structure homogeneity. Benign tumours are usually smaller than 4cm, with smooth borders, which are well-distinguished from adjacent organs and attenuation value less than 10 (6). Higher attenuation values (30-40 HU) due to low lipid component are indicative for pheochromocytoma or ACC, as well as heterogeneous cystic areas caused by necrosis and/or bleeding (1, 7). Adrenal CT with contrast administration assesses the absolute and relative washout values, features of the surrounding tissues infiltration, as well as the presence of liver metastases. Adenomas attenuation coefficient will return quickly to basic values, ACC attenuation coefficient will remain elevated and pheochromocytoma may present various washout characteristics (7). In our patient, after contrast administration, CT verified solid tumour, with well-defined borders, localized in right suprarenal gland, size 70x74 mm, with inhomogeneous contrast captivity which could be the result of necrosis and cystic degeneration, pathognomonic for pheochromocytoma.

Hormonal examination

It is a common opinion that incidentally found pheochromocytomas, size less than 1 cm, are usually clinically "mute". Even though our patient had "giant" adrenal tumour highly suspicious of pheochromocytoma on CT, there were no clinical symptoms or signs whatsoever. A possible explanation for this discrepancy could be the fact that large tumours gain in the size due to haemorrhagic necrosis and cystic formation and not always due to tissue that can produce catecholamines.

Recommended diagnostic procedures for pheochromocytoma always include measurements of urinary or plasma metanephrines (8). These tests have higher sensitivity and specificity than measurement of unfractionated catecholamines, since pheochromocytomas may secrete catecholamines episodically, but its degradation will be continuous. Unfortunately, those tests are not available in our institution.

Determination of the VMA is an old test, easy to perform, with specificity that goes up to 95 %. On the other hand, it has low sensitivity (64 %) which why it is no longer recommended for pheochromocytoma screening (5). However, increased VMA concentration in our patient, along with CT presentation, was helpful to be more certain that this AI was pheochromocytoma, even though serum unfractionated catecholamines were normal.

It is still unclear why some pheochromocytomas are "silent". It is possible that chronically elevated catecholamine levels lead to down regulation of the adrenergic receptors making them more tolerable. Also, besides catecholamines, pheochromocytomas may produce a variety of biologically active peptides. The majority will cause vasoconstriction such as neuropeptide Y, but some will show vasodilatation effects, which will prevent hypertension (6).

In the last decade CgA has become valuable diagnostic test for pheochromocytoma with reported sensitivity and specificity from 74 % - 96 % (9). False positive results could appear in patients with atrophic gastritis type A, in chronic therapy with proton pump inhibitors or H2 receptor blockers, or in the patients with prostate cancer and neuroendocrine tumours (9). More important is an awareness that CgA could be normal or false negative in patients with pheochromocytoma as it was in our case. Chromogranin is known to inhibit catecholamine secretion by the adrenal medulla. The CgA level correlates with catecholamine level during sympathetic or adrenal medulla stimulation, but it is not significant at rest and may be afflicted by various tissue factors (10). If we assume that clinically silent pheochromocytoma is due to the absence of increased catecholamine production and secretion, or presence of vasodilatation components produced in the same tumor, it is possible that silent pheochromocytoma produces smaller amounts of CgA.

Screening tests for multiple endocrine neoplasias (MEN) were also in the referent range (calcitonin and PTH). Cortisol-producing adenoma was excluded since cortisol levels, ACTH concentration and overnight DST were normal. Plasma aldosterone concentration and plasma renin activity were not determined, because potassium levels were in referent range.

Scintigraphy imaging

A further diagnostic procedure included [131I]-MIBG scan. It is useful for determining if the adrenal lesion is pheochromocytoma, to screen patients for metastases and to confirm if the extra-adrenal mass is paraganglioma or neuroblastoma. On the other hand, [131I]-MIBG can accumulate in normal adrenal medulla making the false-positive diagnosis of the pheochromocytoma (11). In our patient, together with characteristic CT findings and elevated VMA concentration MIBG was a very useful tool.

Histopathological examination

Histopathological examination of the specimen confirmed pheochromocytoma composed of large cells that are pink to mauve, arranged in cords or nests with capillaries in between (HE x 200).

Conclusion

Hormonally inactive asymptomatic pheochromocytomas are very rare. Even though diagnostic

algorithms are useful, physicians should always keep in mind that clinical signs could be absent and diagnostic tests false negative. Pheochromocytoma diagnosis should be made as stratification of all available radiological and hormonal tests in order to prevent potential oversight and provide proper treatment.

References

1. Young WF Jr. Clinical practice. The incidentally discovered adrenal mass. *N Engl J Med* 2007; 356:601-10. [\[PubMed\]](#) [\[CrossRef\]](#)
2. Andoulakis II, Kaltsas G, Piaditis G, Grossman AB. The clinical significance of adrenal incidentalomas. *Eur J Clin Invest* 2011; 41: 552-60. [\[PubMed\]](#) [\[CrossRef\]](#)
3. Kim J, Bae KH, Choi YK, Jeong JY, Park KG, Kim JG, et al. Clinical Characteristic for 348 patients with adrenal incidentaloma. *Endocrinol Metab* 2013; 28:20-5. [\[PubMed\]](#) [\[CrossRef\]](#)
4. Radojkovic D, Stojanovic M, Pesic M, Radojkovic M, Radenkovic S, Radjenovic Petkovic T, et al. Clinically „silent“ giant pheochromocytoma, case report. *Acta Endocrinol (Buc)* 2013; 9(1):121-30. [\[CrossRef\]](#)
5. Kanagarajah P, Ayyathurai R, Manoharan M, Narayanan G, Kava BR. Current concepts in the management of adrenal incidentalomas. *Urology Ann* 2012; 4(3): 137-44. [\[PubMed\]](#) [\[CrossRef\]](#)
6. Kasperlik-Zaluska AA, Otto M, Cichocki A, Rosłonowska E, Słowinska-Srzednicka J, Zgliczyński W, et al. 1161 patients with adrenal incidentalomas: indications for surgery. *Langenbecks Arch Surg* 2008; 393(2): 121-6. [\[CrossRef\]](#)
7. Sugawaea T, Hashimoto T, Owada M, Kawamura M. CT features of early pheochromocytoma. *Inte Med* 2011; 50:787. [\[PubMed\]](#) [\[CrossRef\]](#)
8. Fassnacht M, Arlt W, Bancos I, Dralle H, Newell-Price J, Sahdev A, et al. Management of adrenal incidentalomas: European Society of Endocrinology Clinical Practice Guideline in collaboration with the European Network for the Study of Adrenal Tumors. *Eur J Endocrinol* 2016; 175(2): 1-34. [\[PubMed\]](#) [\[CrossRef\]](#)
9. Unger N, Hinrichs J, Deutschbein T, Schmidt H, Walz MK, Mann K, et al. Plasma and Urinary Metanephrines Determined by an Enzyme Immunoassay, but not Serum Chromogranin A for the Diagnosis of Pheochromocytoma in Patients with Adrenal Mass. *Exp Clin Endocrinol Diabetes* 2012; 120(8):494-500. [\[PubMed\]](#) [\[CrossRef\]](#)
10. Louthan O. Chromogranin A in physiology and oncology. *Folia Biologica (Praha)* 2011; 57:173-81.
11. Ilias I, Pacak K. Current approaches and recommended algorithm for the diagnostic localization of pheochromocytoma. *J Clin Endocrinol Metab* 2004; 89: 479-91. [\[PubMed\]](#) [\[CrossRef\]](#)

Prikaz bolesnika**UDC: 616.452-006.6-073.7**
doi:10.5633/amm.2019.0214

ASIMPTOMATSKI "GIGANTSKI" FEOHROMOCITOM OTKRIVEN KAO ADRENALNI INCIDENTALOMA – PRIKAZ PACIJENTA I PREGLED LITERATURE

Danijela Radojković^{1,2}, Milan Radojković^{1,3}

¹Univerzitet u Nišu, Medicinski fakultet, Niš, Srbija

²Klinika za endokrinologiju, dijabetes i bolesti metabolizma, Klinički centar Niš, Niš, Srbija

³Hirurška klinika, Klinički centar Niš, Niš, Srbija

Kontakt: Danijela Radojković
Sestre Baković 14/28, 18000 Niš, Srbija
E-mail: dr.danijela3@gmail.com

Adrenalni incidentalomi (AI) definišu se kao tumori otkriveni radiološkim procedurama kod bolesnika kod kojih prethodno nije postojala sumnja na bolest nadbubrežnih žlezdi. Asimptomatski feohromocitom, otkriven na ovaj način, obično je manji od 10 mm. Slučajno otkrivanje feohromocitoma većih dimenzija, koji je uz to bez ikakvih kliničkih znakova, prava je retkost.

U ovoj studiji prikazana je mlada bolesnica sa tumorom desne nadbubrežne žlezde, promera 60x70 mm, otkrivenim ultrazvučnim pregledom abdomena u okviru sistematskog pregleda. Kompjuterizovanom tomografijom (CT) potvrđeno je prisustvo "gigantskog" tumora, veličine 70x74 mm, sa cističnim i nekrotičnim poljima i nehomogenom distribucijom kontrasta. Sem diskretno povišene koncentracije vanilmandelične kiseline (VMA) u 24-časovnom urinu, svi ostali rezultati endokrinološkog ispitivanja bili su u referentnom opsegu. Urađena je [¹³¹I] MIBG scintigrafija ([¹³¹I] meta-jod-benzil-gvanidin) koja je išla u prilog feohromocitoma desne nadbubrežne žlezde. Nakon adekvatne preoperativne pripreme, urađena je desnostrana adrenalektomija. Sama operacija i postoperativni tok protekli su uredno, a histopatološkim ispitivanjem potvrđen je feohromocitom.

Veća učestalost AI, koja se beleži u poslednjih nekoliko decenija, posledica je široke rasprostranjenosti brojnih radioloških dijagnostičkih tehnika. Iako je većina AI nefunkcionalna, uvek treba imati na umu da se iza klinički "nemog" nadbubrežnog tumora može kriji maligni proces ili hormonski aktivan tumor. Detaljno ispitivanje svakog AI sprečiće previde ovakve vrste, a bolesniku obezbediti adekvatnu terapiju.

Acta Medica Medianae 2019;58(2):82-88.

Ključne reči: *asimptomatski feohromocitom, incidentalom*