

HORMONE IMBALANCE IN A PATIENT WITH HYPOGONADISM AND CRANIAL BASE TOXOPLASMOSIS

Aleksandar Kostić^{1,2}, Jovan Ilić¹, Marija Ilić², Jagoš Golubović³,
Nikola Stojanović², Milica Mitić⁴, Marina Djordjević Spasić⁵

Toxoplasmosis is a globally prevalent infection caused by the protozoan parasite *Toxoplasma gondii* (*T. gondii*) and represents a widespread and highly adaptable parasitic disease. This case report describes alterations in endocrine function in a patient with *T. gondii* infection. A 45-year-old man was examined by a neurosurgeon due to visual impairment and intermittent headaches. Magnetic resonance imaging of the brain revealed an extracranial presentation characterized by symmetrical subcentimeter cystic lesions at the skull base. There were no signs of intracranial involvement or abnormalities of the *sella turcica*. The patient had secondary hypogonadism with decreased levels of both luteinizing hormone and follicle-stimulating hormone. However, *T. gondii* infection did not result in an increase in testosterone levels. This rare case of a patient with *T. gondii* infection and hypogonadism highlights the requirement for further research to better understand the pathophysiological mechanisms underlying endocrine alterations associated with this parasite.

Acta Medica Medianae 2025;64(4):63–68.

Key words: toxoplasmosis, hypogonadism, skull base

¹University Clinical Center of Niš, Department of Neurosurgery, Niš, Serbia

²University of Niš, Faculty of Medicine, Niš, Serbia

³University of Novi Sad, Faculty of Medicine, Novi Sad, Serbia

⁴University Clinical Center of Niš, Department of Pathology, Niš, Serbia

⁵University Clinical Center of Niš, Department of Infectious Diseases, Niš, Serbia

Contact: Jovan Ilić
112/12 Vizantijski Blvd., 18000 Niš, Serbia
E-mail: jovanilicneuro@gmail.com

dysfunction of the gonadal tissue, or central (secondary) hypogonadism, due to dysfunction of the hypothalamic-pituitary axis. Patients present with decreased serum testosterone levels, with variable levels of gonadotropin concentrations. Clinically, hypogonadism may manifest as infertility, reproductive dysfunction, decreased bone mineral density, reduced libido, emotional instability, and fatigue (5).

Recent evidence suggests that *T. gondii* infection may influence human behavior by affecting hormonal regulation, including alterations in testosterone levels. This case report examines endocrine alterations in a patient with *T. gondii* infection.

Introduction

Toxoplasmosis is a globally prevalent infection caused by the protozoan parasite *Toxoplasma gondii* (*T. gondii*) and represents a widespread and highly adaptable parasitic disease (1). This parasite can infect humans, but it is more commonly found in various animal species, with prevalence rates above 50% in dogs, rabbits, and sea otters, exceeding 60% in rodents and wild birds, and up to 70% in felines, bears, and deer (2, 3). Based on epidemiological assessments, it is highly likely that more than one-third of the global human population has been exposed to this parasite (4). Male hypogonadism is characterized by reduced or absent secretion of sex hormones and impaired reproductive function of the testicles. It is classified as primary hypogonadism due to

Case Presentation

A 45-year-old man was examined by a neurosurgeon due to visual impairment and intermittent headaches. Magnetic resonance imaging (MRI) of the pituitary gland revealed a microadenoma located in the left lateral aspect of the gland (Figure 1).

Brain MRI demonstrated an extracranial pattern characterized by symmetrical subcentimeter cystic lesions in both sphenoid bones, the retromaxillary region, the right medial and superior rectus muscles, as well as in both infratemporal fossae adjacent to the parotid glands (Figures 2 and 3). There were no signs of intracranial involvement or involvement of the *sella turcica*.

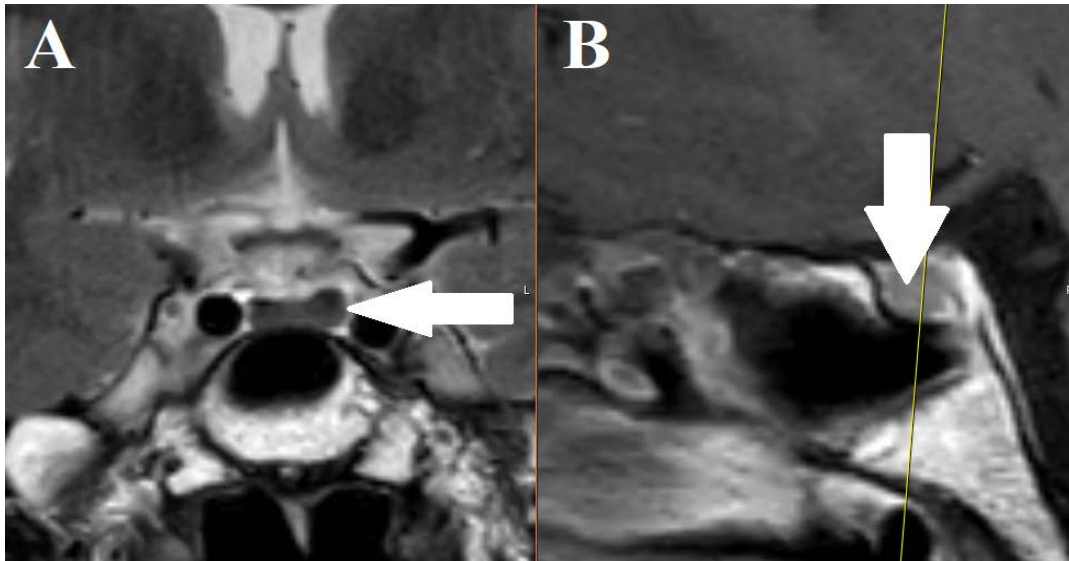


Figure 1. In the left lateral aspect of the adenohypophysis (A, B), an irregular T2-weighted hypointense lesion (arrow), measuring 3 x 5 mm, is observed. The lesion demonstrates delayed post-contrast enhancement and is consistent with a pituitary microadenoma

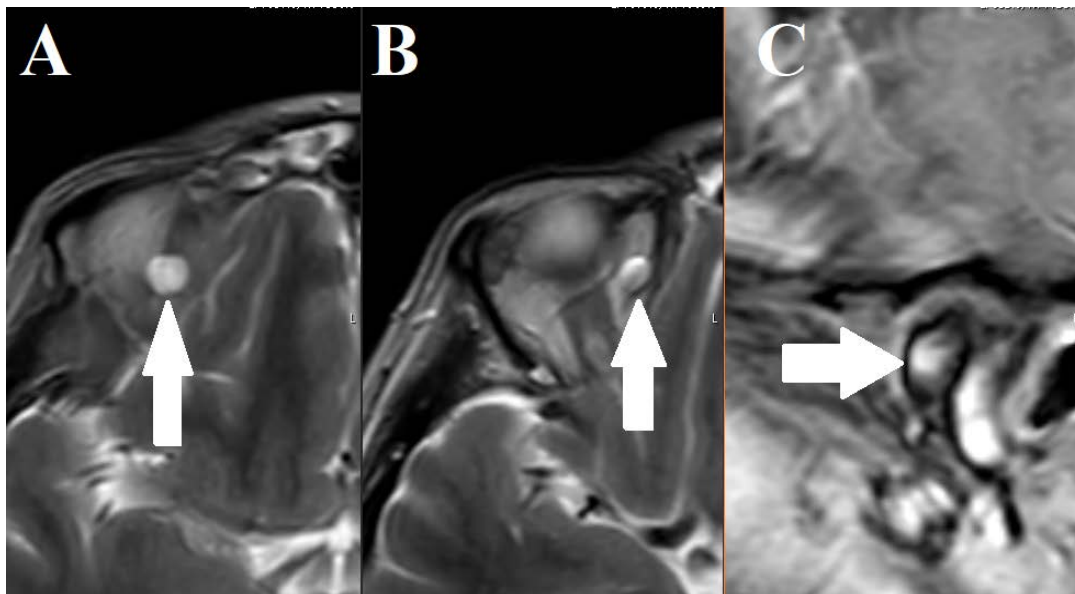


Figure 2. Multiple cystic lesions are present along the superior (A) and medial rectus muscles (B) of the right orbit, as well as within the deep lobe of the left parotid gland (C), as indicated by the white arrows

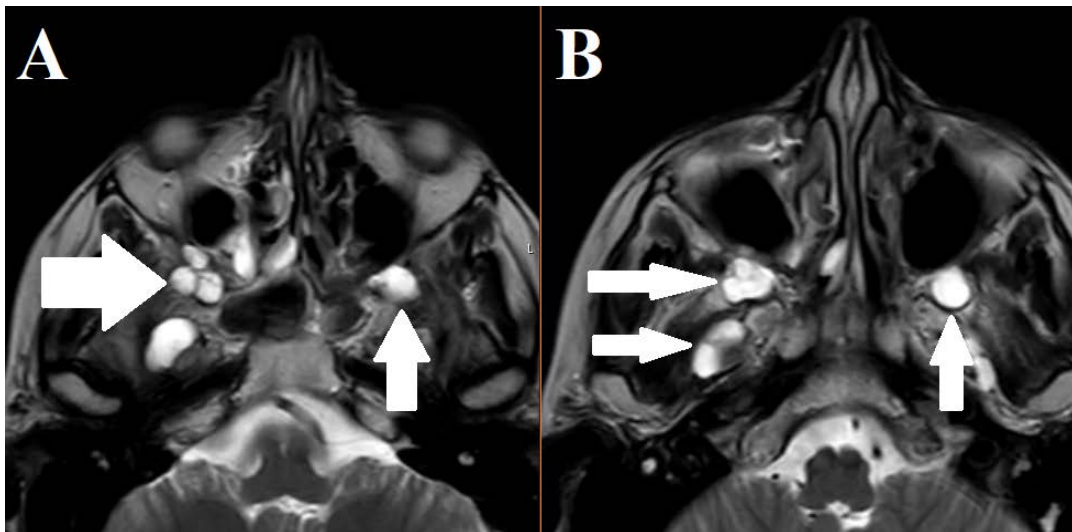


Figure 3. Multiple cystic lesions are present in the bilateral retromaxillary regions (A, B), as indicated by the white arrows

The physical appearance of the patient was specific. He exhibited tall stature, a slender physique, pale skin, and the absence of facial hair. Additionally, the patient had no children and reported no history of marriage or long-term relationships. For the past 20 years, he had lived with several cats. A complete neurological examination exhibited no abnormalities.

As the brain MRI showed no findings of surgical significance, the patient was referred to an infectious disease specialist. Western blot testing for *Toxoplasma gondii* immunoglobulin G and immunoglobulin M antibodies was positive, so conservative treatment was initiated with albendazole (400 mg twice daily for seven days) and prednisone (20 mg once daily for four weeks). In addition, gastroprotective agents, probiotics, and analgesic therapy were prescribed. Follow-up examination after one year showed no progression of disease on the control brain MRI.

Hormonal assessment was performed using an enzyme-linked immunosorbent assay (ELISA) test, with the following results: growth hormone 3.40 ng/ml (reference range < 2.47), serum oxytocin was 248.88 pg/ml (reference range 15.0–242), luteinizing hormone (LH) 0.2 IU/L (reference range 1.2–8.6), follicle-stimulating hormone (FSH) 0.4 IU/L (reference range 1.3–19.3), and testosterone 2.9 nmol/l (reference range 9.9–27.8). Levels of adrenocorticotropic hormone (ACTH), free thyroxine (FT4), thyroid-stimulating hormone (TSH), and prolactin were within the normal limits. The patient was referred to an endocrinologist for further assessment and management of secondary hypogonadism.

At the 12-month follow-up, control brain MRI showed no significant changes in the number or size of the cystic lesions, nor in the size of the microadenoma. Hormonal evaluation was repeated using the ELISA, with the following results: growth

hormone 2.97 ng/ml (reference range < 2.47), serum oxytocin was 165.1 pg/ml (reference range 15.0–242), LH 0.1 IU/L (reference values 1.2–8.6), FSH levels were 0.3 IU/L (reference range 1.3–19.3), and testosterone 1.22 nmol/l (reference range 9.9–27.8). The values of ACTH, FT4, TSH, and prolactin remained within the normal limits. Conservative management was continued with analgesic therapy as needed for occasional headaches.

Discussion

It has been estimated that approximately 20–60% of the population in Eastern Europe is infected with *T. gondii* (6). The parasite is most commonly transmitted through the consumption of undercooked food containing tissue cysts, contact with infected feline feces, or vertical transmission during pregnancy. In symptomatic individuals, the most common clinical manifestations are flu-like symptoms, headache, lymphadenopathy, fever, chills, malaise, and fatigue (7). In more severe cases, particularly in immunocompromised patients and neonates, encephalitis, chorioretinitis, and neurodevelopmental impairment may occur (8). Miscarriages and congenital anomalies are also frequently reported. However, in most cases, *T. gondii* infection is asymptomatic, whereas latent toxoplasmosis has been suggested to contribute to sex hormone imbalance and hypogonadism (9).

Furthermore, *Toxoplasma gondii* infection has been associated with various behavioral and psychological alterations in infected individuals (10). The sexual reproduction of this parasite occurs in the feline definitive host, while selective evolutionary pressures have favored mechanisms that enhance transmission from intermediate hosts (e.g., rodents) to cats, thus completing its life cycle. The neurotropic affinity of *T. gondii* for the central nervous system of intermediate hosts

is thought to contribute to host manipulation (11). Additional experimental studies have elaborated on these hypotheses, examining whether *T. gondii* infection alters rodent perception of the predators, particularly cat odor (12, 13). An experimental study analyzed how rodents react to cat odors, as cat odor induces a strong innate aversion, which persists even after multiple generations of laboratory breeding. The results showed that uninfected rats clearly avoided areas with cat odor, while infected rats showed a pathological, potentially suicidal, attraction to areas marked with cat-associated odors (13). Some studies have indicated changes in social and reproductive behavior, including increased interaction between uninfected females and infected males, resulting in a higher number of matings between them, which is one of the confirmed modes of transmission of this parasite (14).

Other studies have investigated the pathophysiology of behavioral changes in rats and have demonstrated a positive correlation between behavioral alterations and the expression of genes involved in testosterone synthesis in experimentally infected male rats (15).

Behavioral alterations in infected patients may be preceded by encephalitis, with different predilection sites depending on the *T. gondii* strains (16). Some authors have analyzed the effects of *T. gondii* infection on libido and perceived attractiveness in men and women, reporting increased libido and attractiveness among infected individuals (15). Some of the results in infected participants had lower fluctuating facial asymmetry, while women with *T. gondii* infection had lower body mass index, a higher number of sexual partners, and higher levels of self-rated attractiveness compared with uninfected controls.

On the other hand, one study reported that both *T. gondii*-infected men and women were rated as attractive and healthier by uninfected individuals (15). A potential route of interhuman transmission of the infection may include unprotected sexual intercourse and oral sex (17). These hypotheses are supported by studies involving female sex workers (18) and individuals with a history of multiple sexual partners (19) in Latin America. On the other hand, seropositive men infected with *T. gondii* are significantly more

promiscuous than uninfected men (19). Furthermore, *T. gondii* infection has been proposed as a potential contributing factor in the development of schizophrenia (10), depression, anxiety disorders, obsessive-compulsive disorder (19), and autism spectrum disorder (10, 20–22).

Numerous studies have shown a positive correlation between *T. gondii* infection and elevated testosterone levels (9). Most human studies have demonstrated elevated testosterone levels after latent toxoplasmosis in men with latent toxoplasmosis, while three studies have noted decreased levels, and two studies observed no significant changes. These discrepancies in results could be explained by the incompletely understood pathophysiological mechanisms of *T. gondii* infection in humans, which selectively stimulate libido and sexual behavior in ways that may facilitate transmission. Whether *T. Gondii* infection influences secondary hypogonadism and reduced libido remains unclear. In the present case report, no such association was observed. Although our patient had secondary (central) hypogonadism and pituitary microadenoma, with low levels of both LH and FSH, *T. gondii* infection did not lead to an increase in testosterone levels. During a two-year follow-up, the patient's clinical appearance and sex hormones remained unchanged. His serological findings showed the persistence of infection despite therapy, without any increase in testosterone levels.

Additionally, lower testosterone levels observed in infected humans and animals may contribute to infertility and lower libido. A potential explanation is that different *T. gondii* strains and varying intensities of infection—detected by serological tests, polymerase chain reaction, and microscopic methods—may play an important role in the observed variation in testosterone levels (23).

Conclusion

This rare case of a *Toxoplasma gondii* infection associated with hypogonadism highlights the need for further research to better understand the underlying pathophysiological mechanisms.

References

1. Boothroyd JC, Grigg ME. Population biology of *Toxoplasma gondii* and its relevance to human infection: do different strains cause different diseases? *Curr Opin Microbiol* 2002;5(4):438-42. [\[PubMed\]](#)
2. Lafferty KD. Can the common brain parasite, *Toxoplasma gondii*, influence human culture? *Proc R Soc B* 2006;273(1602):2749-55. [\[CrossRef\]](#) [\[PubMed\]](#)
3. Webster JP. Prevalence and transmission of *Toxoplasma gondii* in wild brown rats, *Rattus norvegicus*. *Parasitology* 1994;108(Pt 4):407-11. [\[CrossRef\]](#) [\[PubMed\]](#)
4. Tenter AM, Heckeroth AR, Weiss LM. *Toxoplasma gondii*: from animals to humans. *Int J Parasitol* 2000;30(12):1217-58. [\[CrossRef\]](#) [\[PubMed\]](#)
5. Barber TM, Kyrou I, Kaltsas G, Grossman AB, Randeve HS, Weickert MO. Mechanisms of Central Hypogonadism. *Int J Mol Sci* 2021;22(15):8217. [\[CrossRef\]](#) [\[PubMed\]](#)
6. Pappas G, Rousfos N, Falagas ME. Toxoplasmosis snapshots: global status of *Toxoplasma gondii* seroprevalence and implications for pregnancy and congenital toxoplasmosis. *Int J Parasitol* 2009;39(12):1385-94. [\[CrossRef\]](#) [\[PubMed\]](#)
7. Dubey JP, Jones JL. *Toxoplasma gondii* infection in humans and animals in the United States. *Int J Parasitol* 2008;38(11):1257-78. [\[CrossRef\]](#) [\[PubMed\]](#)
8. Flegr Jaroslav. Effects of *Toxoplasma* on human behavior. *Schizophr Bull* 2007;33(3): 757-60. [\[CrossRef\]](#) [\[PubMed\]](#)
9. Abdoli A, Ghaffarifar F, Sharifi Z, Taghipour A. *Toxoplasma gondii* infection and testosterone alteration: A systematic review and meta-analyses. *PLoS One* 2024;19(4):e0297362. [\[CrossRef\]](#) [\[PubMed\]](#)
10. Webster JP. The effect of *Toxoplasma gondii* on animal behavior: playing cat and mouse. *Schizophr Bull* 2007;33(3):752-6. [\[CrossRef\]](#) [\[PubMed\]](#)
11. Werner H, Masihi KN, Senk U. Latent *Toxoplasma* infection as a possible risk factor for CNS disorders. *Zentralbl Bakteriell Mikrobiol Hyg A* 1981;250(3):368-75. [\[CrossRef\]](#) [\[PubMed\]](#)
12. Berdoy M, Webster JP, Macdonald DW. Fatal attraction in *Toxoplasma*-infected rats: a case of parasite manipulation of its mammalian host. *Proc R Soc B* 2000;267(1452):1591-4. [\[CrossRef\]](#) [\[PubMed\]](#)
13. Webster JP, Lamberton PHL, Donnelly CA, Torrey EF. Parasites as causative agents of human affective disorders? The impact of anti-psychotic, mood-stabilizer, and anti-protozoan medication on *T. gondii*'s ability to alter host behaviour. *Proc Biol Sci* 2006;273(1589):1023-30. [\[CrossRef\]](#) [\[PubMed\]](#)
14. Dass SAH, Vasudevan A, Dutta D, Soh LJT, Sapolsky RM, Vyas A. Protozoan parasite *Toxoplasma gondii* manipulates mate choice in rats by enhancing attractiveness of males. *PLoS One* 2011;6(11):e27229. [\[CrossRef\]](#) [\[PubMed\]](#)
15. Lim A, Kumar V, Hari Dass SA, Vyas A. *Toxoplasma gondii* infection enhances testicular steroidogenesis in rats. *Mol Ecol* 2013;22(1):102-10. [\[CrossRef\]](#) [\[PubMed\]](#)
16. Borráz-León JI, Rantala MJ, Krams IA, Cerdá-Molina AL, Contreras-Garduño J. Are *Toxoplasma*-infected subjects more attractive, symmetrical, or healthier than non-infected ones? Evidence from subjective and objective measurements. *PeerJ* 2022;10:e13122. [\[CrossRef\]](#) [\[PubMed\]](#)
17. Flegr J, Klapilová K, Kaňková Š. Toxoplasmosis can be a sexually transmitted infection with serious clinical consequences. Not all routes of infection are created equal. *Med Hypotheses* 2014;83(3):286-9. [\[CrossRef\]](#) [\[PubMed\]](#)
18. Alvarado-Esquivel C, Sánchez-Anguiano LF, Hernández-Tinoco J, Arreola-Cháidez E, López J, Salcido-Meraz KI, et al. High seroprevalence of *Toxoplasma gondii* infection in female sex workers: a case-control study. *Eur J Microbiol Immunol* 2015;5(4):285-92. [\[CrossRef\]](#) [\[PubMed\]](#)
19. Alvarado-Esquivel C, Estrada-Martínez S, Ramos-Nevárez A, Pérez-Álamos AR, Beristain-García I, Alvarado-Félix AO, et al. Is *Toxoplasma gondii* Infection Associated with Sexual Promiscuity? A Cross-Sectional Study. *Pathogens* 2021;10(11):[1393 p]. [\[CrossRef\]](#) [\[PubMed\]](#)
20. Groër MW, Yolken RH, Xiao JC, Beckstead JW, Fuchs D, Mohapatra SS, et al. Prenatal depression and anxiety in *Toxoplasma gondii*-positive women. *Am J Obstet Gynecol* 2011;204(5):433. [\[CrossRef\]](#) [\[PubMed\]](#)
21. Nayeri Chegeni T, Sarvi S, Amouei A, Moosazadeh M, Hosseini Z, Aghayan S, et al. Relationship between toxoplasmosis and obsessive compulsive disorder: A systematic review and meta-analysis. *PLoS Negl Trop Dis* 2019;13(4):e0007306. [\[CrossRef\]](#) [\[PubMed\]](#)
22. Al Malki JS, Hussien NA, Al Malki F. Maternal toxoplasmosis and the risk of childhood autism: serological and molecular small-scale studies. *BMC Pediatr* 2021;21(1):133. [\[CrossRef\]](#) [\[PubMed\]](#)
23. Abdoli A. *Toxoplasma*, testosterone, and behavior manipulation: the role of parasite strain, host variations, and intensity of infection. *Front Biol* 2014;9(2):151-60. [\[CrossRef\]](#)

HORMONSKI DISBALANS KOD PACIJENTA SA HIPOGONADIZMOM I TOKSOPLAZMOZOM BAZE LOBANJE

Aleksandar Kostić^{1,2}, Jovan Ilić¹, Marija Ilić², Jagoš Golubović³, Nikola Stojanović², Milica Mitić⁴, Marina Đorđević Spasić⁵

¹Univerzitetski klinički centar Niš, Klinika za neurohirurgiju, Niš, Srbija

²Univerzitet u Nišu, Medicinski fakultet, Niš, Srbija

³Univerzitet u Novom Sadu, Medicinski fakultet, Novi Sad, Srbija

⁴Univerzitetski klinički centar Niš, Klinika za patologiju, Niš, Srbija

⁵Univerzitetski klinički centar Niš, Klinika za infektivne bolesti, Niš, Srbija

Kontakt: Jovan Ilić

Vizantijski bulevar 112/12, 18000 Niš, Srbija

E-mail: jovanilic94@gmail.com

Toksoplazmoza predstavlja globalno rasprostranjenu infekciju koju izaziva parazit *Toxoplasma gondii* (*T. gondii*), prilagodljiv i široko rasprostranjen organizam. Ovaj prikaz slučaja zasnovan je na ispitivanju promena u hormonskom disbalansu kod pacijenta sa infekcijom parazitom *T. gondii*. Kod četrdesetpetogodišnjeg muškarca, kojeg je neurohirurg pregledao zbog problema sa vidom i povremenih glavobolja, magnetnom rezonancom mozga utvrđeno je prisustvo ekstrakranijalnih simetričnih cističnih lezija manjih od jednog centimetra u bazi lobanje. Nije bilo znakova intrakranijalnog zahvatanja, kao ni zahvatanja u selarnoj regiji. Iako je ovaj pacijent imao sekundarni hipogonadizam, sa niskim vrednostima i luteinizirajućeg hormona (LH) i folikostimulirajućeg hormona (FSH), parazit *T. gondii* nije doveo do povećanja nivoa testosterona. Ovaj redak slučaj pacijenta sa infekcijom parazitom *T. gondii* i hipogonadizmom naglašava potrebu za daljim istraživanjem, koje je neophodno sprovesti da bi se bolje razumeli patofiziološki mehanizmi koji leže u osnovi infekcije ovim parazitom.

Acta Medica Medianae 2025; 64(4):63–68.

Ključne reči: toksoplazmoza, hipogonadizam, baza lobanje

"This work is licensed under a Creative Commons Attribution 4.0 International (CC BY 4.0) Licence".