

## ENLARGED MASTOID FORAMEN

Dragoslava Đerić<sup>1,2</sup>, Bojana Bukurov<sup>2</sup>, Srbislav Blažić<sup>2</sup>, Ljiljana Čvorović<sup>1,2</sup>

A superficial venous system of posterior neck region is very important as a possible source of complications during surgery, such as bleeding or air embolism. Despite the advances in anatomy and neurosurgery, detailed descriptions of mastoid foramen (MF) and mastoid emissary veins (MEV) are still lacking in literature.

Anatomical features of the mastoid region were examined on 150 samples of the temporal bones that were selected from our large cohort. In one temporal bone we found a very large mastoid foramen with wide communication to the sigmoid sinus. We reviewed the literature and discussed the importance of variation of vascularisation in the mastoid region. *Acta Medica Medianae* 2014;53(4):27-29.

**Key words:** mastoid foramen, variations, sigmoid sinus, tinnitus, surgical importance

---

University of Belgrade, School of Medicine, Serbia<sup>1</sup>  
Clinic for Otorhinolaryngology and Maxillofacial Surgery,  
Belgrade, Clinical Center of Serbia<sup>2</sup>

Contact: Dragoslava Đerić  
Clinic of Otorhinolaryngology and Maxillofacial Surgery, Clinical  
Center Serbia  
Pasterova 2, 11000 Belgrade  
Email: dragadj@beotel.rs

### Introduction

Temporal bone is generally known of its difficult anatomy and a large number of anomalies. One of the structures which detailed anatomy and description is still lacking in literature is the mastoid foramen (MF) and accompanying mastoid emissary veins (MEV). Emissary veins participate in extracranial venous drainage of dural sinuses in the posterior fossa, in addition to internal jugular vein or instead of this vein. Different emissary veins have been described according to their anatomical position, such as occipital, mastoid, parietal and frontal emissary veins. It is widely accepted that, in most of the cases, singular MEV as coursing through MF, connects the sigmoid sinus with either posterior auricular or occipital veins (2,6). According to the data published in literature, MF can vary from being absent to having four small openings, each transmitting the emissary vein (5). The purpose of this study was to present a case of temporal bone with enlarged MF and point out a clinical and surgical importance of this anatomical variation.

### Case report

For many years we have performed various anatomical studies on 1.000 samples of temporal bones of adults of both sexes. From this collection, we selected 150 temporal bones without signs of congenital malformation or disease and prepared them using classical anatomical techniques. Fixation was done in 6% formaldehyde, followed by decalcification in 5% solution of nitric acid, dehydration and washing in distilled water. The specimens were cut along three planes: 50 samples were cut sagittally, 60 frontally and 40 horizontally. These samples were examined using an operating microscope and the necessary documentation was made. Several anatomical features of the mastoid region were analyzed. We found that one temporal bone had extremely enlarged MF (6x5mm), which contained singular MEV (Figure 1.).

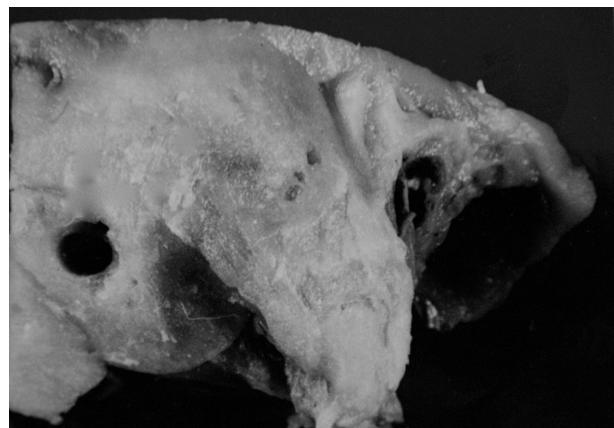


Figure 1. Enlarged mastoid foramen (6x5mm)

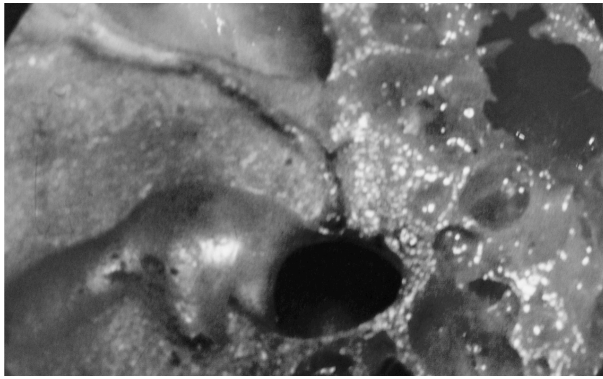


Figure 2. Frontal section of the bone. Wide communication between mastoid foramen and sigmoid sinus is shown

The wide communication of MF with sigmoid sinus was found on the frontal section of the bone (Figure 2.). All other bones showed very small MF and were not analyzed.

### Discussion

There are only few reports in literature that especially address MF and MEV. Most of the authors agree that MEV is present in most of the examined specimen with percent varying from 72% to 98% (5,7). Schelling et al. (9) found a MEV in 80% of almost nine hundred macerated skulls and concluded that the MEV is the most important accessory emissary veins. Luis et al. (5) observed the average diameter of the MEV to be 3.5mm. In the study of Reis et al. (7), the average MEV diameter was reported to be 2.15mm.

Research conducted by San Millan Ruiz et al. (8) demonstrated that emissary veins act as

the primary outflow route for venous drainage in the upright position, in comparison to the drain-age path followed in the prone position. In addition, they may act as a safety valve, protecting the brain from dangerous increases in intracranial pressure in patients with lesions of the neck or skull base and bilaterally obstructed internal jugular veins (1).

The reasons for enlargement of MF may be a highflow vascular malformations or severe hypoplasia or aplasia of the jugular veins, which may occur in malformations of the skull base such as cranio-synostosis (10).

Clinical manifestations due to the presence of developed MEV are usually poor, and they can be expressed in the form of tinnitus. Radiographic imaging (computed tomography of temporal bone and magnetic resonance imaging with angiogram) could provide profound analysis of head vascularisation (3). A detailed knowledge of normal anatomy and possible anomalies of temporal bone helps to avoid misinterpretation such as pathological lesions and iatrogenic bleedings (4). Clinical importance of MEV is possible prolonged bleeding during surgery in this region or an appearance of fine embolism. Also, MEV have direct communication with endocranial venous sinuses and the possibility of the spread of infection in the intracranial space. On the other hand, the infection from the skin to the endocranial spaces may spread over the venous system of the mastoid region. Precise knowledge of the aforementioned anatomical variation is important so as to avoid some difficulties and complications during ear surgery, especially in the mastoid region.

There are no conflicts of interest or potential conflicts or financial interest in preparing this study.

### References

- Braun JP, Tournade A. Venous drainage in the cranio cervical region. *Neuroradiology* 1977;13(3): 155-8. [[CrossRef](#)] [[PubMed](#)]
- Clemente CD. *Gray's anatomy*. 30th ed. Philadelphia: Lea & Febiger; 1985:815-6.
- Grewal AK, Kim HY, Comstock RH 3rd, Berkowitz F, Kim HJ, Jay AK. Clinical presentation and imaging findings in patients with pulsatile tinnitus and sigmoid sinus diverticulum/dehiscence. *Otol Neurotol* 2014; 35(1):16-21. [[CrossRef](#)] [[PubMed](#)]
- Koesling S, Kunkel P, Schul T. Vascular anomalies, sutures and small canals of temporal bone on axial CT. *Eur J Radiol* 2005;54(3):335-43. [[CrossRef](#)] [[PubMed](#)]
- Louis RG Jr, Loukas M, Wartmann CT, Tubbs RS, Apaydin N, Gupta AA, et al. Clinical anatomy of the mastoid and occipital emissary veins in the large series. *Surg Radiol Anat* 2009;31(2):139-44. [[CrossRef](#)] [[PubMed](#)]
- Moore KL, Dalley AF II. *Clinically oriented anatomy*. 5th ed. Baltimore: Lippincott Williams & Wilkins; 2006:915-6.
- Reis C, Deshmukh V, Zabramski JM, Crusius M, Deshmukh P, Spetzler RE, et al. Anatomy of the mastoid emissary vein and venous system of the posterior neck region: neurosurgical implications. *Neurosurgery* 2007;61(5 Suppl 2):193-201. [[CrossRef](#)] [[PubMed](#)]
- San Millan Ruiz D, Gailloud P, Rufenacht DA, Delavelle J, Henry F, Fasel JH. The craniocervical venous system in relation to cerebral venous drainage. *Am J Neuroradiol* 2002;23:1500-8. [[PubMed](#)]
- Schelling F. The emissaries of the human skull. *Anat Anz* 1978;43(4):340-82. German. [[PubMed](#)]
- Taylor WJ, Hayward RD, Lasjaunias P, Britto JA, Thompson DN, Jones BM, et al. Enigma of raised intracranial pressure in patients with complex craniosynostosis: the role of abnormal intracranial venous drainage. *J Neurosurg* 2001;94(3):377-85. [[CrossRef](#)] [[PubMed](#)]

## Proširen mastoidni foramen

*Dragoslava Đerić, Bojana Bukurov, Srbislav Blažić, Ljiljana Čvorović*

Površinski venski sistem zadnjeg predela vrata je veoma važan za mogućnost pojave komplikacija u toku operacije, kao što su krvarenje ili vazдушna embolija. Uprkos napretku na polju anatomije i neurohirurgije, detaljni opisi mastoidnog foramena (MF) i mastoidnih emisarnih vena (MEV) u literaturi su oskudni.

Anatomske karakteristike mastoidnog predela ispitivane su na 150 uzoraka temporalne kosti koje su odabrane iz velike kolekcije. U jednom slučaju temporalne kosti nađen je proširen mastoidni foramen koji je komunicirao sa sigmoidnim sinusom. Prikazana je literatura i diskutovano je o značaju varijacija vaskularizacije u predelu mastoida. *Acta Medica Medianae 2014;53(4):27-29.*

**Ključne reči:** *mastoidni foramen, varijacije, sigmoidni sinus, tinitus, hirurški značaj*