

ETIOPATHOGENESIS OF RECURRENT LARYNGEAL PAPILOMATOSIS AND CONTEMPORARY TREATMENT STRATEGIES

Marija Krstić¹, Jovana Pavlović², Petar Stanković³, Tanja Milenković⁴

Recurrent laryngeal papillomatosis is a rare and chronic disease of the larynx caused by infection with human papillomaviruses type 6 or 1. Larynx is the most common location of papillomas with changes in voice as the first presenting symptom. Patients suffer from wart-like growths in the aerodigestive tract, recurrences and possible life-threatening obstruction of the airway. The course of the disease is unpredictable. Although spontaneous remission is possible, variable clinical course may include frequent recurrence of disease, significant morbidity and frequent surgical procedures. The mechanisms responsible for the variability in the clinical course and the persistence of latent HPV infection remain unknown. It is considered that both adaptive and innate immune response made by patients with papillomatosis support chronic infection. Patients with laryngeal papillomas are unable to produce an effective HPV-specific T-cell response, as shown by an altered CD8+ subset and the Th1/Th2 cytokine imbalance with suppression of Th1 response. There is a genetic association between certain HLA type II genes with severe course of disease and downregulation of HLA type I genes. Surgical excision, including new methods such as microdebrider, aims to secure an adequate airway and improve and maintain an acceptable voice, but may cause serious complications like stenosis of the airway. When papillomas recur, old and new adjuvant methods may be tried. Intralesional cidofovir injection is shown as effective and secure in the majority of cases. Recent advances in immune system research may provide the improvement of our treatment modalities and prevention strategies. *Acta Medica Medianae* 2014;53(4):64-74.

Key words: recurrent laryngeal papillomatosis, human papillomavirus, operative management, adjuvant treatment, cidofovir

Ear, Nose, Throat Clinic, Clinical Center Niš, Serbia¹
General Hospital, Leskovac, Serbia²
Neurosurgery Clinic, Clinical Center Niš, Serbia³
University of Niš, Faculty of Medicine, Serbia⁴

Contact: Marija Krstić
Jeronimova 24/S2, 18000 Niš, Serbia
e-mail: modestinis10@yahoo.com

Introduction

Recurrent respiratory papillomatosis (RRP) is a rare chronic disease of viral etiology caused by human papillomavirus (HPV), most commonly types 6 and 11, which are also the cause of genital infections in 90% of the cases. In recurrent respiratory papillomatosis, papilloma is most frequently localized in the larynx (1). It is the most common benign neoplasm of the larynx in children and the second most common cause of hoarseness. The clinical course of the disease is unpredictable, especially in children, as it is more aggressive compared to the adult type, and the severity correlates with the child's age on diagnosis. Relapses are more frequent in the juvenile-onset type; the disease is spread more widely, affecting the airways distal to the larynx.

The disease may undergo spontaneous remission, which requires only periodic surgical treatment or it can be aggressive with the need for surgical procedures every few days or weeks, adjuvant therapy, and significant emotional and economic impact on the patient's family. Laryngeal papillomatosis is a disease whose incidence is increasing and whose molecular mechanisms of formation are still not fully explained (2).

In the United States, the incidence of RRP is 4.3/100 000 in children and 1.8/100 000 in adults. In the United States, the prevalence in children is 1.7 to 2.6/100 000 per year. There is no confirmed correlation between gender, ethnicity or socio-economic conditions and the appearance of papillomas or between early presentation of recurrent respiratory papillomatosis and clinical course (3,4). In about 75% of the cases, juvenile-onset laryngeal papillomatosis is diagnosed between the age of two and five, most frequently by the age of three and no later than seven, while in 25% of cases, it is diagnosed during the first year of life (5). If the disease is diagnosed before the age of three, the chance for frequent surgical interventions is 3.6 times higher, while the probability that papillomatosis is localized in more than two anatomical sites in the lower airways is 2 times

higher. Mortality is higher in the juvenile-onset type and occurs due to complications of frequent surgical interventions, respiratory failure, distal spread of the disease and potential malignant alteration. Prognosis is poor in neonatal age (6). The average number of surgical interventions per child is 5.1 per year, while the total annual number of surgical interventions, for both children and adults, in the United States is over 15 000. On average, patients with juvenile-onset type of the disease undergo 20 surgical interventions in their lifetime, the majority of which is in their childhood, while those with an aggressive form of RRP have up to 40 surgeries in their lifetime. There is a significantly higher number of surgical interventions in children diagnosed with RRP before the age of four in comparison to those older than four on diagnosis. Direct medical costs of juvenile-onset RRP in the United States are over \$150 million annually (7).

Pathological characteristics and malignant potential

Human papillomavirus (HPV) is a DNA virus that belongs to the Papovaviridae family. There are over 180 different types of HPV, classified according to their tendency to malignant alteration of the infected tissue as the "high-risk" types (HPV 16, 18, 31, 33, 35, 39, 45, 51, 52, 56, 58, 59, 68, 69 and 73), which have a greater malignant potential, and the "low-risk" (6,11,34,40,42,43, and 44), which are isolated in most benign cutaneous and anogenital lesions and have a lower malignant potential (8). HPV was isolated and confirmed a cause of recurrent respiratory papillomatosis for the first time in the early eighties (9). The DNA of the human papilloma virus was identified in each sample, most frequently types 6 and 11. HPV type 11 is the most common type (50%-100% of the samples) and has the most aggressive clinical course (10).

The infection may lead to the expression of the viral DNA, which results in the appearance of clinically manifested papillomatosis, or the infection may be latent, without the expression of the DNA, so that the squamous epithelium can be clinically and histopathologically unchanged. HPV activates the receptor pathway of the epidermal growth factor (EGF). It is believed that HPV influences cellular phenotype transformation, either by the constant activation of EGFR, an increase in the number of receptors or reduced degradation of the receptors, or a combination of all the above factors (11).

Papillomatosis arises from squamous epithelium in the areas where there is a junction of squamous and ciliated epithelium or in the areas with damaged ciliated epithelium and squamous metaplasia, which again represents a predilection site for papilloma. HPV genome consists of three regions: 1) regulatory region, 2) early (E region), and 3) late (L region). There are 8 genes that are important to genome replication: E1, E2, E4, E5,

E6 and E7, and L1 and L2. Transcription of the E region occurs in the early phase of infection, and is part of the viral DNA replication. Genes of the E region can be incorporated into the genome of the host cell and have an oncogenic activity. Spontaneous malignant alteration of papillomatosis into a well-differentiated lung carcinoma or laryngeal squamous cell carcinoma (SCC) is possible but rare, and has a poor prognosis. The clinical course of the disease is not a predictor of when and where the carcinoma will occur. Although they are classified as "low-risk", HPV types 11 and 6 are most frequently associated with carcinomas arising from spontaneous papilloma alteration (12).

In more than 50%, HPV 11 was isolated as the only type. In other patients, both types 6 and 11 were present, while solely HPV type 6 was isolated in only a few patients. Malignant alteration is rare and more common in the adult-onset type, while the incidence for the juvenile-onset type is less than 1% with malignant alteration in later life. The association of the type of HPV and malignant alteration has not been confirmed; during malignant alteration there may even be a change in the types of HPV from 6/11 in papillomas to 16 or 31/33 in carcinoma. In rare cases, due to malignant alteration, DNA of human papillomavirus cannot be detected. The degree of dysplasia is not a predictor of time and location of malignant alteration. In malignant papillomas there is increased expression of p53 in the basal and intermediate layers, but it is of different degree and inconsistent with the expression of p53 in papilloma and variable during the malignant alteration of papilloma into carcinoma. The degree of p53 expression is not a reliable marker of malignant alteration and does not correlate with the progression of papilloma into carcinoma. Genes E6 and E7 disrupt the cell cycle and prevent apoptosis. Integration into the genome of the infected cells adjacent to the suppressor genes, fragile areas or proto-oncogenes on chromosomes results in increased expression of regulatory genes and stimulation of the viral genome transcription (13).

Tumor suppressor gene p53 and retinoblastoma tumor suppressor protein (pRb) may be inactivated. There may be stimulation of proliferation, loss of cell growth control, damage to p53-dependent DNA repair mechanisms (14), activation of the transcription factor E2F1 (15), and degradation of TIP60 (16) which participates in the activation of apoptosis and pro-apoptotic factor bcl-2 (17), thus enabling the infected cells to survive and replicate. Degradation of p130 causes cell division by switching from phase G0 to G1 (18).

Ki67 is a marker of mitotic cell activity and detects all stages of the mitotic cycle, except G0 phase. Stern et al. suggest that there is a significant correlation between the degree of Ki67 expression and anatomic site affected, spreading into the tracheobronchial tree, recurrence and malignant alteration (19).

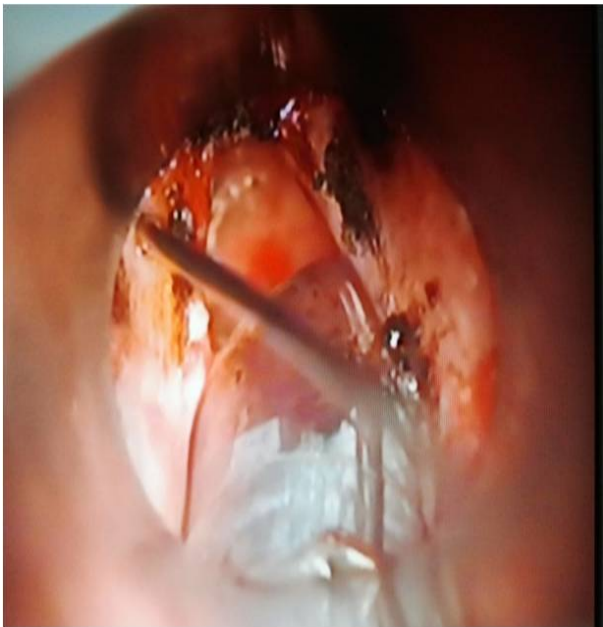

Figure 1. Histological appearance HE x 200

Immunopathogenesis and immunogenic aspects of recurrent laryngeal papillomatosis

Human papilloma virus is part of the commensal flora of human epithelial cells and can be activated in the case of immune incompetence. Most individuals have HPV-specific memory T cells (20). Approximately 5% of the general population who do not show clinical signs of laryngeal papillomatosis have detectable HPV DNA in the larynx, which is clinically manifested only in a small number of patients (21). Viral RNA is hardly ever expressed during the latent stage, while the DNA is detected in the mucous membrane of patients with papillomatosis who have been in remission for a long time. In patients with recurrent laryngeal papillomatosis, HPV DNA has been isolated in anatomical sites of the respiratory tract with unchanged macroscopic appearance (22).

The causes of overt laryngeal papillomatosis, its reactivation after many years of remission, as well as severe clinical picture in a small number of patients still remain unclear. It is believed that individual's innate and adaptive immune response plays a significant role in the manifestation of laryngeal papillomatosis. Molecular and genetic studies suggest that there is an impaired function of T lymphocytes, macrophages and dendritic cells, as well as a disbalance between inhibitory and regulatory cytokines and chemokines in the microenvironment of papillomatous lesions indicating disruption of the local cellular immune response. In the presence of HPV E6, E2, and E7 proteins, these abnormalities suppress proinflammatory Th1 immune responses after antigen presentation by antigen presenting cells (APC) and in the presence of HLA class II antigens. Th1 response is diminished due to Th2 response induction and production of IL4 and IL10 which have immunosuppressive properties

and inhibit the production of Th1 cytokines, mostly IFN γ , IL 4, and IL10, and activate macrophages, which then produce Th2-like chemokines (CCL17 and CCL 18) as well as IL10. IL4 directly suppresses Th1 response by inhibiting the expression of IL12 and IL18, which are strong Th1 stimulants. Th1 suppression prevents immunocompetent cells to clear the infected keratinocytes (23).

In patients with RRP, the number of CD28 + lymphocytes in the peripheral blood and in papillomas is reduced and correlates with the severity of the clinical picture. In papillomatous lesions, there is increased expression of IL4 and IL10 as the dominant cytokines while the expression of IFN γ is decreased and almost completely absent in severe clinical cases. TH1/TH2 disbalance, as well as the number of CD28 + lymphocytes in peripheral blood, inhibits maturation and correlates with the severity of the clinical picture (24).

Significant correlation between the decrease in Th2 chemokine levels and clinical remission has been observed (25), along with the correlation between plasma IL2 level and disease severity (26). Reduced Th1 expression in peripheral blood (IFN γ , IL12, IL18 and IL2) correlates with the severity of the clinical picture. Despite the low immune response to human papilloma virus, in laryngeal papillomas, there is increased expression of β -defensin mRNA in the upper epithelium. In patients with severe clinical picture there has been increased expression of genes encoding chemokines that participate in the induction of angiogenesis, as well as those encoding VEGF (Vascular endothelial growth factor A) which induces cellular proliferation, stimulates angiogenesis, and inhibits apoptosis (27).

There are records of decreased CD107a protein expression (LAMP1 - lysosomal-associated membrane protein) in blood, which serves as a functional marker for the identification of natural killer cell activity. In patients with RRP, IL-10 inhibits dendritic cells in contact with the E6 protein which prevents antigen presentation (28).

Due to the reduced expression of TAP1 which serves as an intracellular messenger, surface expression of HLA class I is reduced, and the level varies in different patients with RRP (29). It has been determined that TAP1 expression correlates with the frequency of recurrence (30).

The interaction between the HLA class I antigens and the inhibitory KIR receptors on the surface of NK cells inhibits the function of NK cells. KIR gene expression is lowered and it correlates with the severity of the clinical picture (31).

Certain MHC Class I genotypes are present in severe or moderate to severe forms. In severe RRP, the expression of TAP1 is decreased in the presence of HLA DRB1*0102 (32). It has also been reported that certain genotypes are related to the severity of clinical presentation. B*08 is the only MHC class I allele associated with a more severe form of the disease. The expression of genes encoding proinflammatory/TH1 chemokines is re-

duced, whereas the expression of genes encoding Th2 chemokines is increased. The expression of genes encoding specific tumor suppressor genes decreased, while the expression of genes encoding growth factors is increased (33,34).

Clinical presentation and course

Human papillomavirus infection is the most common sexually transmitted infection. The most common mode of transmitting the infection to children is vertical transmission from mother to child during delivery. Risk factors for developing clinical RRP in children include first born child and young primigravid mothers (35). Asymptomatic as well as clinical human papilloma virus infection is relatively common in pregnant and sexually active women, while clinical manifestation of recurrent respiratory papillomatosis is not so common among offspring. There are other factors that affect disease manifestation, such as child's immune system, length of virus exposure, sufficient number of pathogens and local trauma to the larynx (prolonged intubation, gastroesophageal reflux disease). Infection in utero, through transplacental transmission of HPV, occurs in about 12% of children with laryngeal papillomatosis (36). There has also been a case of aggressive RRP in a child born by cesarean section (37).

The symptoms are usually not present in the first six months of life and begin to appear as the local papillomas continue to grow (38). The first clinical symptoms include hoarseness, weak or silent cry. Less frequently, the first clinical symptoms are breathing difficulties or stridor, which is initially inspiratory and then becomes biphasic. Clinical picture can be complicated by recurrent upper respiratory tract infections, pneumonia, chronic cough, dysphagia, dyspnea, syncope, failure to thrive, as well as acute respiratory distress. Papillomas in the lower airways and lung parenchyma are rare and represent a serious complication with recurrent pneumonia, emphysema, lung atelectasis and respiratory failure, and are often misdiagnosed as asthma. Predilection sites include vocal folds, glottis and laryngeal surface of the epiglottis. Extralaryngeal spread has been identified in about 30% of children with laryngeal papillomatosis, mostly in the oral cavity, trachea and bronchi. There is a relationship between a child's age and the anatomic localization of papillomavirus. In younger children papillomas are present at more than one anatomic site in the larynx and spread to the lower anatomical structures, whereas in older children, papillomas are more often localized in the larynx and structures above (39).

Clinical course of the disease is variable and unpredictable. In some cases, it is present but stable, with the 1-2 surgical procedures per year and spontaneous remission. In others, it takes a more aggressive clinical course, with intensive papilloma growth and frequent surgical procedures. In the majority of patients, clinical features of the disease are somewhere between these two extre-

mes. Tracheotomy and endotracheal intubation may affect the clinical course (40,41). Remission can occur at any stage, and the period of remission is extremely variable. It can be expected when lesions are limited to the larynx. In patients with childhood-onset forms, papillomas usually remain present and continue to grow in the teenage years (42). Prognosis is worse in cases of younger age at diagnosis. Genital warts in the mother as well as comorbid infections in children at younger age are not predictive factors of the clinical course (43). Literature offers conflicting results regarding the relationship between HPV type 11 and more severe clinical course. Some studies confirm that there is a correlation, while others do not prove that HPV genotypes are associated with the severity of the clinical course (44). The staging system for assessing severity and distribution of RRP that is most commonly used is the one proposed by Colter and Derkay. It consists of two parts - clinical and anatomical. The clinical score assesses airway obstruction, while the anatomical score is related to the distribution of lesions in the larynx and surrounding anatomic structures (45).

Diagnosis

Juvenile-onset recurrent respiratory papillomatosis is usually diagnosed between the age of 2 and 4 years. Papillomatosis is the second most common cause of hoarseness in children, after vocal nodules. Laryngeal papillomatosis in children is usually diagnosed late. Weak cry, difficulty in breathing and stridor in children are not specific to laryngeal papillomatosis, and the disease resembles many other more common diseases such as laryngotracheobronchitis, acute bronchitis, asthma, bronchopneumonia, foreign body aspiration or laryngomalacia. The symptom that should raise suspicion to laryngeal papillomatosis is a persistent change in voice quality, which is transitory in most other common childhood diseases or the voice is preserved. Diagnostic method of choice is flexible fiberoptic laryngoscopy or rigid laryngomicroscopy. Rigid bronchoscopy should be performed in case that papillomatous lesions distal to the larynx are suspected. The method of choice in severe inspiratory stridor with intercostal or supraclavicular retraction is direct laryngoscopy with mass ablation. Pathology report allows for definitive diagnosis of RRP. Pathology examination is required after each papilloma ablation to monitor the disease progression after adjuvant treatment, and potential malignant alteration (46).

Surgical treatment of recurrent laryngeal papillomatosis

The aim of surgical treatment is to remove papillomas and preserve normal structures, adjacent and distal to the lesions, slow disease progression and prolong the interval between surgeries. Not all visible papillomas should be removed, but only the ones necessary to create a

patent airway, preserve or improve voice quality and preserve surrounding healthy tissue. Frequent, aggressive and radical attempts to remove all visible papillomas cause subglottic and glottic stenosis as well as scarring and adhesion formation, especially in the anterior commissure. When removing papillomas, attention should be paid so as not to damage submucosa, vocal cords, arytenoid cartilage and lateral cricoid ligament. Special care is needed when removing lesions in the anterior commissure. Surgical treatment is indicated in case of worsening hoarseness or voice loss, fatigue, sleep apnea or stridor. Surgical procedures are frequent in juvenile-onset RRP, so parents are usually able to recognize the symptoms exacerbation and know when it is time for the next surgical procedure (47).

Laser ablation

Carbon dioxide lasers (CO₂ lasers) and suspension microlaryngoscopy have been successfully used in the treatment of laryngeal papillomatosis for 30 years. The advantages of CO₂ lasers include precise ablation of papillomas and minimal intraoperative bleeding. The heat generated by the laser beam during the procedure can cause damage to deeper tissues and scarring as well as impair vocal cord function. The smoke released during the procedure contains active viral DNA. The most serious complication is burning through the endotracheal tube and combustion of anesthetic gases under the influence of oxygen, which is why the following precaution measures are taken: the use of special endotracheal tube that are resistant to the heat of the laser beam, local cooling, smoke aspiration, low concentration of oxygen (30%) in anesthetic gases as well as jet ventilation anesthesia with the disruption of oxygen flow. With the use of flexible fiber carbon dioxide lasers, there is less damage to the surrounding tissue, coagulation and hemostasis are better, less smoke is released and the wound heals faster. Flexible fiber CO₂ laser also allows for laser removal of lesions in the trachea through a rigid bronchoscope. New generation of CO₂ lasers, AcuBlade and AcuSpot, enable precise incision at different angles and have a focused beam of 250- μ m in diameter. SuperPulse and Ultrapulse lasers do minimal damage to the surrounding tissues because they enable simultaneous local cooling (48).

The 532 nm pulsed KTP (potassium titanyl phosphate) laser and the 585 nm pulsed dye laser (PDL) are photoangiolytic lasers of the new generation where oxyhemoglobin absorbs light energy. These lasers cause selective photocoagulation of papilloma microvasculature while preserving the covering epithelium and doing minimal thermal damage to the surrounding tissue. There have been no records of adhesion formation in the anterior commissure after photoangiolytic laser treatment (49). Apart from the advantage they have over the use of CO₂ laser treatment of papillomas on the anterior commissure, it is also possible to

perform the procedure under local anesthesia like outpatient procedure, which makes them more and more popular methods of removing benign lesions in the larynx.

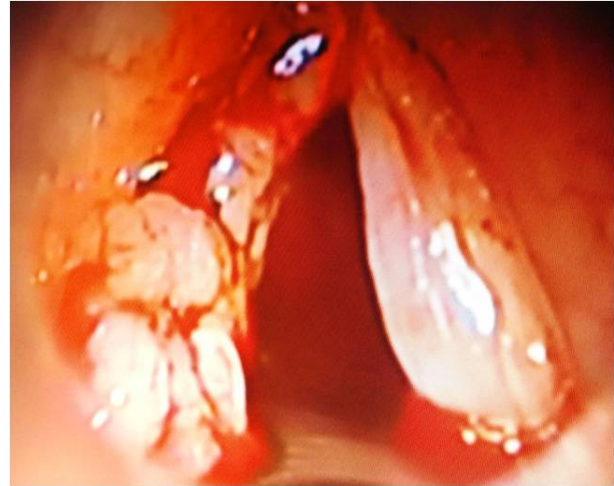

Figure 2. Endoscopic findings before ablation

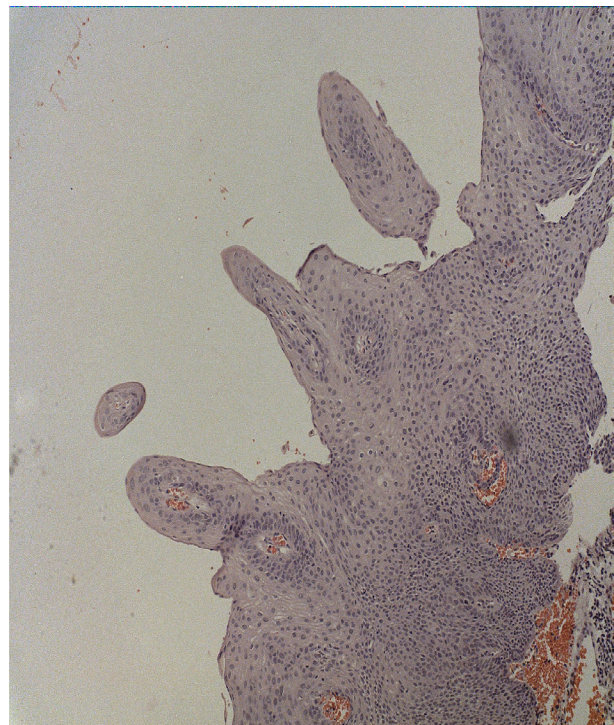


Figure 3. Intralesional application of cidofovir after ablation of papillomas with CO₂ laser

Microdebrider surgery

According to the American Society of Pediatric Otolaryngology, microdebriders have been the most commonly used surgical methods of removing papillomavirus in the United States since 2000. Microdebriders are instruments with rotating blades on top that simultaneously aspirate the excised tissue. The tip itself is round and has no blade. The benefits of this kind of treatment include precise tissue resection with simulta-

neous suction, minimal damage to healthy tissue and the absence of thermal damage to healthy tissue underneath. Lesions are sucked into the top of the mikrodebrider to the blade, which represents a great advantage when removing the lesions on the free margins of the vocal folds and less accessible places such as trachea. Hemostasis is achieved by local administration of epinephrine or oxymetazoline (50).

Radiofrequency cold ablation (coblation)

This is a new method of surgical treatment of laryngeal papillomatosis which has been used since 2010. Bipolar radiofrequency energy excites the electrolytes in a conductive medium (saline), which creates a focused field of energized particles (ions and electrolytes), allowing for the dissolution of organic matter at a relatively low temperature (40 - 600C) with limited penetration deeper into the tissue (up to 100µm, the thickness of a sheet of paper). The instrument for radiofrequency ablation can simultaneously irrigate the operative site with saline and aspirate removed papillomas. The advantages of this kind of treatment include precision, less thermal damage to healthy tissue and hemostasis (51,52).

Adjuvant therapy in the treatment of recurrent laryngeal papillomatosis

Surgical papilloma ablation is often ineffective, aggressive, causing damage to the normal tissue and can lead to airway stenosis. Despite the removal of all macroscopically evident papillomas, microscopic lesions remain. After laser ablation, apparently normal mucosa contains human papilloma virus DNA and can be the cause of relapses. That is why adjuvant therapy is introduced in more than 20% of adult patients and most children with RRP (53). Indications for the introduction of adjuvant pharmacotherapy are not clearly stated and there are treatment protocols. Adjuvant therapy is different for each patient and should be considered when more than 4 surgical procedures are needed per year to maintain a patent airway, in case of frequent recurrence or distal spread of papillomas outside the larynx. The aim of adjuvant therapy is to maintain a patent airway, stabilize papilloma growth, improve voice quality and avoid tracheotomy (54).

Interferon-α is the first drug in the treatment of recurrent respiratory papillomatosis. It inhibits viral protein synthesis and viral DNA replication. It activates NK cell cytotoxicity and enhances the lysis of infected cells. It regulates the expression of IL-12 receptors and stimulates the formation of Th1 lymphocytes. Previous studies have shown variable efficacy of interferon-α in the treatment of recurrent respiratory papillomatosis. A multicentric randomized study of the efficacy of surgical treatment with and without interferon-α showed disease regression in the first

6 months in patients who had received interferon-α. After two years of follow-up, there was no significant benefit of interferon-α treatment compared to surgical treatment alone (55). There was no significant reduction in proliferation of epithelial cells in subjects with clinical improvement who had received interferon-α. Acute and chronic side effects of interferon-α are common. Because of the common side effects, continuous administration of at least 6 months, unpredictable therapeutic effect, frequent relapses after therapy cessation and the appearance of new antiviral medicines, the use of interferon-α in the treatment of recurrent respiratory papillomatosis has been declining (56).

Ribavirin and acyclovir inhibit viral DNA replication. Previous research has shown some positive therapeutic response in a small number of patients, but without significant effect in the treatment of laryngeal papillomatosis (57).

Cidofovir is an antiviral medication, a nucleotide analogue that inhibits DNA polymerase and prevents viral replication and transcription. Cidofovir induces apoptosis in HPV-infected cells (58). The active metabolite has a long intracellular half-life of several weeks. Intralesional administration directly into the papilloma bed may lead to long-term remission. Complete or partial remission is achieved in more than 80% of the patients (59). Prospective studies investigating the effect of intralesional administration of cidofovir (2.5-7.5 mg/ml) have demonstrated complete or partial remission of papillomavirus in most of the patients (60-62). Some studies have demonstrated that intralesional cidofovir administration increases the interval between two surgical procedures, while the results of others showed no significant increase (63,64). Randomized clinical studies have demonstrated a significant decrease in the spread of papillomavirus, but the difference between the groups was not statistically significant (65). Continuous treatment with inhaled cidofovir is a relatively new way of administration with encouraging results in individual cases, especially in disseminated recurrent respiratory papillomatosis (66,67). Retrospective studies of systemic effects of topical administration of cidofovir showed no toxicity of cidofovir after topical administration (68,69). Plasma concentration of cidofovir is not significantly increased with high doses of cidofovir (7.5-10 mg/ml) applied locally (70). Latest studies have shown that local administration of cidofovir does not cause dysplasia in HPV infected epithelial cells (71). Indications for treatment with topical cidofovir are not clearly defined. Cidofovir is commonly included in cases when there is a need for surgical procedures every 2-3 months, if the interval between interventions decreases. Recommended dose is 2.5-7.5 mg/ml (less than 4 ml per administration for adults and less than 2 ml for children. In children, cidofovir is administered every 2-6 weeks until complete remission is achieved. In adults, the

therapeutic scheme depends on the progression of the disease (72).

Indole-3-carbinol is a dietary supplement which is found in high concentrations in cabbage, cauliflower and broccoli and has proven anti-inflammatory, antiangiogenic, proapoptotic and cytostatic effects. It reduces the formation of papilloma by modulating estrogen metabolism. A research on the efficacy and safety of this metabolite in combination with angiolytic laser treatment of RRP in children is being conducted. Celecoxib is a selective COX -2 inhibitor. Experimental studies have demonstrated its strong antiangiogenic effect, but the exact mechanism of action is not clear. Experimental studies on rabbits confirmed that celecoxib has a positive effect on reducing the formation of papilloma. An ongoing double-blind randomized controlled trial is investigating the efficacy of one-year administration of Celebex to adults and children older than two years of age with a 30 months follow-up.

Retinoids are vitamin A metabolites of cell proliferation and differentiation modulators. Continuous administration over 6 months showed no significant improvement in the disease and there were some psychiatric side effects (73).

Photodynamic therapy involves selective uptake of photosensitive substance (Photofrin, mesotetra-hydroxyphenyl-chlorin) by neoplastic and rapidly replicating cells and its activation by red laser light precisely at the desired location, which leads to cell apoptosis. Studies of severe laryngeal papillomatosis have shown significant decrease in papilloma growth, but without long-term remission. Furthermore, the therapy was poorly tolerated in about one quarter of the patients (74).

MMR vaccine. The first studies of the effects of local intralesional injection of mumps vaccine in combination with laser surgery in the treatment of RRP showed a reduction in relapse rate and prolonged remission duration without significant side effects (75). However, the first randomized controlled study of juvenile-onset RRP showed no significant difference in the efficacy of MMR vaccine on long-term remission of recurrent laryngeal papillomatosis after a one-year-follow-up (76).

Anti-reflux therapy. Chronic irritation of the aerodigestive tract epithelium by hydrochloric acid or enzymes can cause mucosal lesions and proliferation of papilloma cells. High doses of H₂-antihistamine cimetidine (30-40 mg/kg) have immunomodulatory effects. It has been shown that continuous administration of cimetidine in high doses over a couple of months induced remission in children with laryngeal papillomatosis, but papilloma continued to form upon treatment discontinuation (77).

Bevacizumab is a recombinant monoclonal antibody which inhibits the vascular endothelial growth factor, and has anti-angiogenic effect. In combination with KTP laser treatment, it has a synergistic effect in reducing angiogenesis. Studies on children with laryngeal papillomatosis have shown that local application of beva-

cizumab (1.25-2.5 mg/ml) reduces the number of surgical procedures per year and improves voice quality and the quality of life (78,79). A prospective study of adult patients which used the contralateral vocal fold as control showed significant papilloma regression in the treated vocal fold as well as general improvement in voice quality (80). A cohort study that used higher doses of locally administered bevacizumab did not show any adverse local and systemic effects of bevacizumab (81).

Immunotherapy is antigen-specific therapy with recombinant DNA vaccines. Previous studies of therapeutic efficacy of DNA vaccines have been performed in animal models of tumors associated with HPV-16 E7 protein. Recombinant DNA vaccines encodes early HPV genes E6 and E7, which initiates CD4 + Th1 antigen-specific response, secretion of IL-2 and induces the proliferation of antigen-specific CD8+E7 cytotoxic lymphocytes and destruction of infected cells (82). HspE7 vaccine is a fusion product composed of heat shock protein 65 and HPV-16 E7 protein. A clinical study on children investigating the effects of subcutaneous vaccinations with HspE7 in three doses with a 60 week follow-up showed significant reduction in the number of surgical procedures as well as papilloma regression (83).

Conclusion

Timely diagnosis and determining the type of HPV infection can greatly influence the disease course and treatment.

There are no histological prognostic factors of local recurrence and malignant alteration of papillomas. The extent of Ki67 expression represents a reliable predictor of the clinical course of the disease.

No single type of therapy has been consistently effective in eradicating respiratory papillomatosis. Primary treatment options include CO₂ laser and microdebrider removal papillomas as standard procedures as well as photoangiolytic laser treatment and coblation as modern and safer methods. The most effective adjuvant therapy is cidofovir.

New therapeutic approaches are directed at epidermal growth factor receptor inhibitors, proapoptotic factors and β -defensins to stimulate innate and adaptive immune response with granulocyte colony-stimulating factors, as well as recombinant DNA vaccine (84).

Quadrivalent vaccines could reduce the incidence of recurrent respiratory papillomatosis in sexually active women, as well as men, and help eradicate the disease (85). Upon vaccination, antibodies cross the uteroplacental barrier, and newborn babies are immune to human papillomavirus (86).

Further randomized, multicenter studies are required to investigate the efficacy of other types of adjuvant therapy in a larger number of patients.

References

1. Derkay CS, Wiatrak B. Recurrent Respiratory Papillomatosis: A Review. *Laryngoscope* 2008; 118: 1236-47. [[CrossRef](#)] [[PubMed](#)]
2. Katsenos S, Becker HD. Recurrent Respiratory Papillomatosis: A Rare Chronic Disease, Difficult to Treat, with Potential to Lung Cancer Transformation: Apropos of Two Cases and a Brief Literature Review. *Case Rep Oncol* 2011;4:162-71. [[CrossRef](#)] [[PubMed](#)]
3. Reeves WC, Ruparella SS, Swanson KI, Derkay CS, Marcus A, Unger ER. National Registry for Juvenile-Onset Recurrent Respiratory Papillomatosis. *Arch Otolaryngol Head Neck Surg* 2003; 129:976-82. [[CrossRef](#)] [[PubMed](#)]
4. Leung R, Hawkes M, Campisi P. Severity of juvenile onset recurrent respiratory papillomatosis is not associated with socioeconomic status in a setting of universal health care. *Int J Pediatr Otorhinolaryngol* 2007; 71(6):965-72. [[CrossRef](#)] [[PubMed](#)]
5. Zacharisen MC, Conley SF. Recurrent Respiratory Papillomatosis in Children: Masquerader of Common Respiratory Diseases. *Pediatrics* 2006; 118:1925. [[CrossRef](#)] [[PubMed](#)]
6. Barnes L, Eveson JW, Reichart P, Sidransky D. *Pathology and Genetics of Head and Neck Tumors*. Lyon: IARC Press; 2005.
7. Larson DA, Derkay CS. Epidemiology of recurrent respiratory papillomatosis. *APMIS* 2010; 118(6-7):450-4. [[CrossRef](#)] [[PubMed](#)]
8. Freed GL, Derkay CS. Prevention of recurrent respiratory papillomatosis: Role of HPV vaccination. *International Journal of Pediatric Otorhinolaryngology* 2006; 70: 1799-803. [[CrossRef](#)] [[PubMed](#)]
9. Gissmann L, Wolnik L, Ikenberg H, Koldovsky U, Schnürch HG, zur Hausen H. Human papillomavirus types 6 and 11 DNA sequences in genital and laryngeal papillomas and in some cervical cancers. *Proc Natl Acad Sci USA* 1983; 80(2):560-3. [[CrossRef](#)] [[PubMed](#)]
10. Venkatesan NN, Pine HS, Underbrink MP. Recurrent Respiratory Papillomatosis. *Otolaryngol Clin North Am* 2012; 45(3): 671-99. [[CrossRef](#)] [[PubMed](#)]
11. Vambutas A, Di Lorenzo TP, Steinberg BM. Laryngeal Papilloma Cells Have High Levels of Epidermal Growth Factor Receptor and Respond to Epidermal Growth Factor by a Decrease in Epithelial Differentiation. *Cancer Res* 1993; 53:910-4. [[CrossRef](#)] [[PubMed](#)]
12. Jeong WJ, Park SW, Shin M, Lee YJ, Jeon YK, Jung YH, et al. Presence of hpv type 6 in dysplasia and carcinoma arising from recurrent respiratory papillomatosis. *Head Neck* 2009; 31: 1095-101. [[PubMed](#)]
13. Go C, Schwartz MR, Donovan DT. Molecular transformation of recurrent respiratory papillomatosis: viral typing and p53 overexpression. *Ann Otol Rhinol Laryngol* 2003; 112:298-302. [[CrossRef](#)] [[PubMed](#)]
14. Rady PL, Schnadig VJ, Weiss RL, Hughes TK, Tyring SK. Malignant Transformation of Recurrent Respiratory Papillomatosis Associated With Integrated Human Papillomavirus Type 11 DNA and Mutation of p53. *Laryngoscope* 1998; 108:735-40. [[CrossRef](#)] [[PubMed](#)]
15. Gupta S, Takhar PP, Degenkolbe R, Koh CH, Zimmermann H, Yang CM, et al. The human papillomavirus type 11 and 16 E6 proteins modulate the cell-cycle regulator and transcription cofactor TRIP-Br1. *Virology* 2003; 317(1):155-64. [[CrossRef](#)] [[PubMed](#)]
16. Jha S, Vande PS, Banerjee NS, Dutta AB, Chow LT, Dutta A. Destabilization of TIP60 by human papillomavirus E6 results in attenuation of TIP60-dependent transcriptional regulation and apoptotic pathway. *Mol Cell* 2010; 38(5):700-11. [[CrossRef](#)] [[PubMed](#)]
17. Underbrink MP, Howie HL, Bedard KM, Koop JI, Galloway DA. E6 proteins from multiple human betapapillomavirus types degrade Bak and protect keratinocytes from apoptosis after UVB irradiation. *J Virol* 2008; 82(21):10408-17. [[CrossRef](#)] [[PubMed](#)]
18. Zhang B, Chen W, Roman A. The E7 proteins of low- and high-risk human papillomaviruses share the ability to target the pRB family member p130 for degradation. *Proc Natl Acad Sci U S A*. 2006; 103(2):437-42. [[CrossRef](#)] [[PubMed](#)]
19. Stern Y, Heffelfinger SC, Walner DL, Cotton RT. Expression of Ki-67, tumor suppressor proteins, growth factor, and growth factor receptor in juvenile respiratory papillomatosis: Ki-67 and p53 as predictors of aggressive disease. *Otolaryngol Head Neck Surg* 2000;122:378-86. [[CrossRef](#)] [[PubMed](#)]
20. Welters MJ, de Jong A, van den Eeden SJ, van der Hulst JM, Kwappenberg KM, Hassane S, et al. Frequent display of human papillomavirus type 16 E6-specific memory t-Helper cells in the healthy population as witness of previous viral encounter. *Cancer Res* 2003; 63:636-41. [[PubMed](#)]
21. Abramson AL, Steinberg BM, Winkler B. Laryngeal papillomatosis: clinical, histopathologic and molecular studies. *Laryngoscope* 1987; 97:678-85. [[CrossRef](#)] [[PubMed](#)]
22. Smith EM, Pignatari SS, Gray SD, Haugen TH, Turek LP. Human papillomavirus infection in papillomas and nondiseased respiratory sites of patients with recurrent respiratory papillomatosis using the polymerase chain reaction. *Arch Otolaryngol Head Neck Surg* 1993; 119(5):554-7. [[CrossRef](#)] [[PubMed](#)]
23. Bonagura VR, Hatam LJ, Rosenthal DW, DeVoti JA, Lam F, Steinberg BM, et al. Recurrent respiratory papillomatosis: A complex defect in immune responsiveness to human papillomavirus-6 and -11. *APMIS* 2010; 118(6-7):455-70. [[CrossRef](#)] [[PubMed](#)]
24. Bonagura VR, Hatam L, DeVoti J, Zeng F, Steinberg BM. Recurrent respiratory papillomatosis: altered CD81 T-Cell subsets and TH1/TH2 cytokine imbalance. *Clinical Immunology* 1990; 93:302-11. [[CrossRef](#)] [[PubMed](#)]
25. Rosenthal DW, DeVoti JA, Steinberg BM, Abramson AL, Bonagura VR. TH2-like chemokine patterns correlate with disease severity in patients with recurrent respiratory papillomatosis. *Mol Med* 2012; 18:1338-45. [[CrossRef](#)] [[PubMed](#)]
26. Snowden RT, Thompson J, Horwitz E, Stocks RM. The predictive value of serum interleukins in recurrent respiratory papillomatosis: A preliminary study. *Laryngoscope* 2001; 111:404-8. [[CrossRef](#)] [[PubMed](#)]
27. Chong KT, Xiang L, Wang X, Jun EL, Xi L, Schweinfurth JM. High level expression of human epithelial β -defensins (hBD-1, 2 and 3) in papillomavirus induced lesions. *Virology Journal* 2006; 3:75. [[CrossRef](#)] [[PubMed](#)]
28. Hatam L, Schuval S, Bonagura VR. Flow cytometric analysis of natural killer cell function as a clinical assay. *Cytometry* 1994; 16:59-68. [[CrossRef](#)] [[PubMed](#)]
29. Bonagura VR, Siegal FP, Abramson AL, Santiago-

- Schwarz F, O'Reilly ME, Shah K, et al. Enriched HLA-DQ3 phenotype and decreased class I major histocompatibility complex antigen expression in recurrent respiratory papillomatosis. *Clin Diagn Lab Immunol* 1994; 1:357-60. [[PubMed](#)]
30. Vambutas A, Bonagura VR, Steinberg BM. Altered expression of TAP-1 and major histocompatibility complex class I in laryngeal papillomatosis: correlation of TAP-1 with disease. *Clinical and diagnostic laboratory immunology* 2000; 7(1):79-85. [[PubMed](#)]
 31. Bonagura VR, Du Z, Ashouri E, Luo L, Hatam LJ, DeVoti JA, et al. Activating killer cell immunoglobulin-like receptors 3DS1 and 2DS1 protect against developing the severe form of recurrent respiratory papillomatosis. *Hum Immunol* 2010; 71(2):212-9. [[CrossRef](#)] [[PubMed](#)]
 32. Vambutas A, Bonagura VR, Reed EF, Abramson AL, Mullooly V, DeVoti J, et al. Polymorphism of transporter associated with antigen presentation 1 as a potential determinant for severity of disease in recurrent respiratory papillomatosis caused by human papillomavirus types 6 and 11. *J Infect Dis* 2004; 189:871. [[CrossRef](#)] [[PubMed](#)]
 33. Bonagura VR, Vambutas A, DeVoti JA, Rosenthal DW, Steinberg BM, Abramson AL, et al. HLA alleles, IFN- γ responses to HPV-11E6, and disease severity in patients with recurrent respiratory papillomatosis. *Human Immunology* 2004; 65:773-82. [[CrossRef](#)] [[PubMed](#)]
 34. Gelder CM, Williams OM, Hart KW, Wall S, Williams G, Ingrams D, et al. HLA class II polymorphisms and susceptibility to recurrent respiratory papillomatosis. *Journal of Virology* 2003; 77(3):1927-39. [[CrossRef](#)] [[PubMed](#)]
 35. Shah KV, Stern WF, Shah FK, Bishai D, Kashima HK. Risk factors for juvenile onset recurrent respiratory papillomatosis. *Pediatr Infect Dis J* 1998; 17:372-26. [[CrossRef](#)] [[PubMed](#)]
 36. Rombaldi RL, Serafini EP, Mandelli J, Zimmermann E, Losquiavo KP. Transplacental transmission of human papillomavirus. *Virology* 2008; 5:106. [[CrossRef](#)] [[PubMed](#)]
 37. Loyo M, Pai SI, Netto GJ, Tunkel DE. Aggressive recurrent respiratory papillomatosis in a neonate. *International Journal of Pediatric Otorhinolaryngology* 2008; 72(6): 917-20. [[CrossRef](#)] [[PubMed](#)]
 38. Harris AT, Atkinson H, Vaughan C, Knight LC. Presentation of laryngeal papilloma in childhood: the Leeds experience. *International Journal of Clinical Practice* 2012; 66(2):183-4. [[CrossRef](#)] [[PubMed](#)]
 39. Stamatakis S, Nikolopoulos TP, Korres S, Felekis D, Tzangaroulakis A, Ferekidis E. Juvenile recurrent respiratory papillomatosis: still a mystery disease with difficult management. *Head Neck* 2007; 29:155-62. [[CrossRef](#)] [[PubMed](#)]
 40. Mgbor NC, Dahilo EA, Mgbor S. Laryngeal papillomatosis: an 11 year review of 54 cases in Enugu. *Nig J Otorhinolaryngol* 2005; 2:64-9.
 41. Cole RR, Myer CM III, Cotton RT. Tracheotomy in children with recurrent respiratory papillomatosis. *Head Neck* 1989; 11:226-30. [[CrossRef](#)] [[PubMed](#)]
 42. Orji FT, Okorafor IA, Akpeh JO. Experience with recurrent respiratory papillomatosis in a developing country: Impact of tracheostomy. *World J Surg* 2013; 37:339-43. [[CrossRef](#)] [[PubMed](#)]
 43. Wiatrak BJ, Wiatrak DW, Broker TR, Lewis L. Recurrent respiratory papillomatosis: A longitudinal study comparing severity associated with human papilloma viral types 6 and 11 and other risk factors in a large pediatric population. *Laryngoscope* 2004; 114(104):1-23. [[CrossRef](#)] [[PubMed](#)]
 44. Izadi F, Hamkar R, Ghanbari H, Abdolmotallebi F, Jahandideh H. The role of Human papilloma virus (HPV) genotyping in recurrent respiratory papillomatosis in Rasoul Akram Hospital. *Med J Islam Repub Iran* 2012; 26(2):90-3. [[PubMed](#)]
 45. Derkay CS, Malis DJ, Zalzal G, Wiatrak BJ, Kashima HK, Coltrera MD. A Staging system for assessing severity of disease and response to therapy in recurrent respiratory papillomatosis. *Laryngoscope* 1998; 108:935-7. [[CrossRef](#)] [[PubMed](#)]
 46. Fasunla AJ, Lasisi OA. Diagnostic challenges of laryngeal papillomatosis and its implications among children in developing country. *International Journal of Pediatric Otorhinolaryngology* 2009; 73:593-5. [[CrossRef](#)] [[PubMed](#)]
 47. Stephen RH, Peter JK. Operative management of juvenile-onset recurrent respiratory papillomatosis. *Operative Techniques in Otolaryngology* 2012; 23:117-23. [[CrossRef](#)]
 48. Yan Y, Olszewski AE, Hoffman MR, Zhuang P, Ford CN, Dailey SH, et al. Use of Lasers in Laryngeal Surgery. *Journal of Voice* 2010;24(1):102-9. [[CrossRef](#)] [[PubMed](#)]
 49. Kuet ML, Pitman MJ. Photoangiolytic Laser Treatment of Recurrent Respiratory Papillomatosis: A Scaled Assessment. *Journal of Voice* 2013; 27(1): 124-8. [[CrossRef](#)] [[PubMed](#)]
 50. Schraff S, Derkay CS, Burke B, Lawson L. American Society of Pediatric Otolaryngology members' experience with recurrent respiratory papillomatosis and the use of adjuvant therapy. *Arch Otolaryngol Head Neck Surg* 2004, 130: 1039-42. [[CrossRef](#)] [[PubMed](#)]
 51. Carney AS, Evans AS, Mirza S, Psaltis A. Radio frequency coblation for treatment of advanced laryngo tracheal recurrent respiratory papillomatosis. *J Laryngol Otol* 2010; 124: 510-4. [[CrossRef](#)] [[PubMed](#)]
 52. Rachmanidou A, Modayil PC. Coblation resection of paediatric laryngeal papilloma. *J Laryngol Otol* 2011; 125: 873-6. [[CrossRef](#)] [[PubMed](#)]
 53. Hamza AH, Nasr MM, Deghady AA. The use of mitomycin- C for respiratory papillomas: clinical, histologic and biochemical correlation. *Saudi Med J* 2005; 26(11): 1737-45. [[PubMed](#)]
 54. Derkay C. Task Force on Recurrent Respiratory Papillomas. A preliminary report. *Arch Otolaryngol Head Neck Surg* 1995; 121: 1386-91. [[CrossRef](#)] [[PubMed](#)]
 55. Healy GB, Gelber RD, Trowbridge AL, Grundfast KM, Ruben RJ, Price KN. Treatment of recurrent respiratory papillomatosis with human leukocyte interferon. Results of a multicenter randomized clinical trial. *N Engl J Med* 1998; 319: 104-7. [[PubMed](#)]
 56. Szeps M, Dahlgren L, Aaltonen LM, Ohd J, Kanter-Lewenshon L, Dahlstrand H, et al. Human papillomavirus, viral load and proliferation rate in recurrent respiratory papillomatosis in response to an interferon treatment. *J Gen Virol* 2005; 86(6): 1695-702. [[CrossRef](#)] [[PubMed](#)]
 57. Morrison GA, Kotecha B, Evans JN. Ribavirin treatment for juvenile respiratory papillomatosis. *J Laryngol Otol* 1993; 107(5): 423-6. [[CrossRef](#)] [[PubMed](#)]
 58. Armbruster C. Novel treatments for recurrent respiratory papillomatosis. *Expert Opin Investig Drugs* 2002; 11: 1139-48. [[CrossRef](#)] [[PubMed](#)]
 59. Chadha NK, James AL. Antiviral agents for the treatment of recurrent respiratory papillomatosis: a systematic review of the English-language literature. *Otolaryngol Head Neck Surg* 2007; 136(6):863-9. [[CrossRef](#)] [[PubMed](#)]

60. Pontes P, Weckx LL, Pignatari SS, Fujita RR, Avelino MA, Sato J. Local application of cidofovir as adjuvant therapy in recurrent laryngeal papillomatosis in children. *Rev Assoc Med Bras* 2009; 55(5): 581-6. Portuguese. [[CrossRef](#)] [[PubMed](#)]
61. Pransky SM, Albright JT, Magit AE. Long-term follow-up of pediatric recurrent respiratory papillomatosis managed with intralesional cidofovir. *Laryngoscope* 2003; 113: 1583-7. [[CrossRef](#)] [[PubMed](#)]
62. Wierzbicka M, Jackowska J, Bartochowska A, Jozefiak A, Szyfter W, Kedzia W. Effectiveness of cidofovir intralesional treatment in recurrent respiratory papillomatosis. *Eur Arch Otorhinolaryngol* 2011; 268(9): 1305-11. [[CrossRef](#)] [[PubMed](#)]
63. Robin EA, Gi TP, Dietz A, Djukic V, Eckel HE, Friedrich G, et al. Treatment of recurrent respiratory papillomatosis and adverse reactions following off-label use of cidofovir (Vistide). *Eur Arch Otorhinolaryngol* 2012; 269: 361-2. [[CrossRef](#)] [[PubMed](#)]
64. McMurray JS, Connor N, Ford CN. Cidofovir efficacy in recurrent respiratory papillomatosis: a randomized, double-blind, placebo-controlled study. *Ann Otol Rhinol Laryngol* 2008; 117: 477-83. [[CrossRef](#)] [[PubMed](#)]
65. Chadha NK, James A. Adjuvant antiviral therapy for recurrent respiratory papillomatosis (Reviews). *Cochrane Database Syst Rev* 2012; 12: CD005053. [[CrossRef](#)] [[PubMed](#)]
66. Ksiazek J, Prager JD, Sun GH, Wood RE, Arjmand EM. Inhaled cidofovir as an adjuvant therapy for recurrent respiratory papillomatosis. *Otolaryngol Head Neck Surg* 2011; 144(4): 639-41. [[CrossRef](#)] [[PubMed](#)]
67. Giles BL, Seifert B. CR12/339-Nebulized cidofovir for recurrent respiratory papillomatosis: a case report. *Paediatr Respir Rev* 2006; 7(1): S330. [[PubMed](#)]
68. Broekema FI, Dikkers FG. Side-effects of cidofovir in the treatment of recurrent respiratory papillomatosis. *Eur Arch Otorhinolaryngol* 2008; 265(8): 871-9. [[CrossRef](#)] [[PubMed](#)]
69. Gi TP, Ilmarinen T, van den Heuvel ER, Aaltonen LM, Andersen J, Brunings JW, et al. Safety of intralesional cidofovir in patients with recurrent respiratory papillomatosis: an international retrospective study on 635 RRP patients. *Eur Arch Otorhinolaryngol* 2013; 270(5): 1679-87. [[CrossRef](#)] [[PubMed](#)]
70. Naiman AN, Ceruse P, Coulombeau B, Froehlich P. Intralesional cidofovir and surgical excision for laryngeal papillomatosis. *Laryngoscope* 2003; 113(12): 2174-81. [[CrossRef](#)] [[PubMed](#)]
71. Moore JE, Garcia A, Sanyal S, Saunders S, Portnoy JE, Hu A, et al. Degrees of dysplasia based on viral typing in patients with cidofovir use and recurrent respiratory papillomatosis. *J Voice* 2013; 27(6): 765-87. [[CrossRef](#)] [[PubMed](#)]
72. Clamp PJ, Saunders MW. Systematic review of intralesional Cidofovir dosing regimens in the treatment of recurrent respiratory papillomatosis. *International Journal of Pediatric Otorhinolaryngology* 2013; 77: 323-8. [[CrossRef](#)] [[PubMed](#)]
73. ClinicalTrials.gov [Internet]. A service of the U.S. National Institutes of Health. Available at: www.ClinicalTrials.gov
74. Shikowitz MJ, Abramson AL, Steinberg BM, DeVoti J, Bonagura VR, Mullooly V, et al. Clinical trial of photodynamic therapy with mesotetra (hydroxyphenyl) chlorin for respiratory papillomatosis. *Arch Otolaryngol Head Neck Surg* 2005; 131(2): 99-105. [[CrossRef](#)] [[PubMed](#)]
75. Pashley NR. Can mumps vaccine induce remission in recurrent respiratory papilloma? *Arch Otolaryngol Head Neck Surg* 2002; 128(7): 783-6. [[CrossRef](#)] [[PubMed](#)]
76. Lei J, Yu W, Yuexin L, Qi C, Xiumin S, Tianyu Z. Topical measles-mumps-rubella vaccine in the treatment of recurrent respiratory papillomatosis: Results of a preliminary randomized, controlled trial. *Ear Nose Throat J* 2012; 91(4): 174-5. [[PubMed](#)]
77. Harcourt JP, Worley G, Leighton SEJ. Cimetidine treatment for recurrent respiratory papillomatosis. *Int J Pediatr Otorhinolaryngol* 1999; 51: 109-13. [[CrossRef](#)] [[PubMed](#)]
78. Maturro S, Hartnick CJ. Use of 532-nm Pulsed Potassium Titanyl Phosphate Laser and Adjuvant Intralesional Bevacizumab for Aggressive Respiratory Papillomatosis in Children. *Arch Otolaryngol Head Neck Surg* 2010; 136(6): 561-5. [[CrossRef](#)] [[PubMed](#)]
79. Rogers DJ, Ojha S, Maurer R, Hartnick CJ. Use of adjuvant intralesional bevacizumab for aggressive respiratory papillomatosis in children. *Otolaryngol Head Neck Surg* 2013; 139(5): 496-501. [[CrossRef](#)] [[PubMed](#)]
80. Zeitels SM, Barbu AM, Landau-Zemer T, Lopez-Guerra G, Burns JA, Friedman AD, et al. Local Injection of Bevacizumab (Avastin) and Angiolytic KTP Laser Treatment of Recurrent Respiratory Papillomatosis of the Vocal Folds: A Prospective Study. *Ann Otol Rhinol Laryngol* 2011; 120(10): 627-34. [[PubMed](#)]
81. Best SR, Friedman AD, Landau-Zemer T, Barbu AM, Burns JA, Freeman MW, et al. Safety and Dosing of Bevacizumab (Avastin) for the Treatment of Recurrent Respiratory Papillomatosis. *Annals of Otolology, Rhinology & Laryngology* 2012; 121(9): 587-93. [[CrossRef](#)] [[PubMed](#)]
82. Wu A, Zeng Q, Kang TH, Peng S, Roosinovich E, Pai SI, et al. Innovative DNA Vaccine for Human Papillomavirus Associated Head and Neck Cancer. *Gene Ther* 2011; 18(3): 304-12. [[CrossRef](#)] [[PubMed](#)]
83. Derkay CS, Smith RJH, McClay J, van Burik JAH, Wiatrak BJ, Arnold J, et al. HspE7 Treatment of Pediatric Recurrent Respiratory Papillomatosis: Final Results of an Open-Label Trial. *Ann Otol Rhinol Laryngol* 2005; 114(9): 730-7. [[CrossRef](#)] [[PubMed](#)]
84. Suter-Montano T, Montañó E, Martínez C, Plascencia T, Sepulveda MT, Rodríguez M. Adult recurrent respiratory papillomatosis: a new therapeutic approach with pegylated interferon alpha 2a (Peg-IFN α -2a) and GM-CSF. *Otolaryngol Head Neck Surg* 2013; 148(2): 253-60. [[CrossRef](#)] [[PubMed](#)]
85. World Health Organization. Human papillomavirus vaccine position paper. *Biologicals* 2009; 37: 338-344. Available at: <http://www.who.int/immunization/en> [[CrossRef](#)]
86. Matys K, Mallary S, Bautista O, Vuocolo S, Manalastas R, Pitisuttithum P, et al. Mother-Infant Transfer of Anti-Human Papillomavirus (HPV) Antibodies Following Vaccination with the Quadrivalent HPV (Type 6/11/16/18) Virus-Like Particle Vaccine. *Clinical and Vaccine Immunology* 2012; 19(6): 881-5. [[CrossRef](#)] [[PubMed](#)]

ETIOPATOGENETSKI ASPEKTI REKURENTNE LARINGEALNE PAPILOMATOZE I SAVREMENI TERAPIJSKI PRISTUPI

Marija Krstić, Jovana Pavlović, Petar Stanković, Tanja Milenković

Rekurentna laringealna papilomatoza je retka, hronična bolest virusne etiologije uzrokovana humanim papiloma virusom, najčešće tipom 6 i 11. Najčešća lokalizacija papiloma u disajnim putevima je larinks sa prvim simptomom u vidu promuklosti. Karakteriše se progresivnim rastom papiloma koji recidiviraju i mogu dovesti do opstrukcije disajnog puta. Klinički tok je nepredvidiv i individualan, od spontane remisije do agresivnog rasta papiloma sa čestim hiruruškim intervencijama. Ulogu u pojavi manifestne laringealne papilomatoze ima urođeni kao i adaptivni imunski odgovor pojedinca. Karakteriše je disbalans Th1 i Th2 ćelijskog odgovora, smanjenjem broja CD8+ limfocita, sa izraženom produkcijom imunosupresivnih citokina i supresijom lokalnog Th1 odgovora. Ekspresija antigena HLA klase I je smanjena u različitim stepenu kod obolelih od papilomatoze, dok su određeni genotipovi MHC gena klase II predisponirajući faktori manifestne papilomatoze i to težih oblika bolesti. Nijedan terapijski pristup do sada nije u potpunosti efikasan u eradikaciji ove bolesti. Osnovna terapija je hiruruška ablacija papiloma, koja je često neefikasna, agresivna i oštećuje normalne anatomske strukture. Adjuvantna terapija je rezervisana za agresivan oblik bolesti sa čestim recidivima, pri čemu se intraleziona aplikacija cidofovira pokazala kao efikasna terapija. Novi terapijski pristupi usmereni su na inhibitore receptora za epidermalni faktor rasta, proapoptične faktore i egzogene β -defenzine u stimulaciji urođenog i adaptivnog lokalnog imunskog odgovora, kao i na imunoterapiju rekombinantnom DNK vakcinom. Vakcinacija kvadivalentnom vakcinom mogla bi da smanji incidenciju i dovede do eradikacije ove bolesti u budućnosti. *Acta Medica Medianae* 2014;53(4):64-74.

Ključne reči: rekurentna laringealna papilomatoza, humani papiloma virus, hirurško lečenje, adjuvantna terapija, cidofovir