

ANTERIOR AND POSTERIOR FUSION OF CERVICAL SPINE IN OSTEOMYELITIC PROCESS OF SEVERAL VERTEBRAL BODIES: A CASE REPORT

Radisav Mitić¹, Nebojša Stojanović^{1,2}, Aleksandar Kostić^{1,2},
Ivan Cvetković¹, Zvonko Dželebdžić¹

A 52-year old male patient was initially examined because of short-term bronchopneumonia by the primary healthcare physician who prescribed antibiotic therapy that calmed the cough and lowered the temperature. In the following period, the patient started to complain of periodic febrile and subfebrile episodes. One month after the first symptoms of bronchopneumonia, the patient experienced pain in the neck and numbness in his right hand. After approximately ten days, the patient began to experience weakness in both legs and in the right hand. During the examination at the Clinic for Infectious Diseases, severe spastic paraparesis developed. MRI and MSCT scans showed compression of the medulla at the C5 and C6 level, with signs of destruction of the C5 and C6 corpuses.

The progression of the neurological deficit necessitated complete removal of corpuses C5 and C6 and partial removal of corpus C7 which were then replaced by inserting an artificial implant made of acrylate. Anterior stabilization was performed, followed by the posterior cervicothoracic stabilization.

After the intervention, there was an improvement in the neurological deficit. Neurological restitution was achieved one month after surgery. Regular X-ray and MSCT check-ups were performed after 3 and 6 months, as well as after one year. The finding showed good decompression and stabilization. The patient was stable and with no neurological deficits.

Acute osteomyelitic processes of the spine, accompanied by the development of neurological deficits, require urgent surgical procedures and spine reconstruction by using allotransplants and 3D fixation, in combination with intensive antibiotic therapy administered during a long period of time. *Acta Medica Medianae 2016;55(2):50-56.*

Key words: osteomyelitis, cervical vertebrae, corpectomy, 3D stabilization

Clinic for Neurosurgery, Clinical Center Niš, Serbia¹
University of Niš, Faculty of Medicine, Niš, Serbia²

Contact: Radisav Mitić
Clinic for Neurosurgery, Clinical Center Niš
Blvd Dr Zoran Đinđić. 48, 18000 Niš, Serbia
Mail: radisavmitic@gmail.com

Introduction

Non-specific inflammatory processes of the vertebral corpuses incurred by hematogenous or lymphatic dissemination of infectious agents do not represent a common pathological entity. Their frequency ranges from 3–5% of all the cases of osteomyelitis, with an incidence of 2.4/100.000 (1). Non-specific inflammatory changes of the vertebrae are commonly found in the lumbar and lumbosacral spine, and usually are the conse-

quence of pre-existing inflammatory changes in the retroperitoneal space. In some cases, osteomyelitis may develop after cervical injuries, but even then hematogenous or lymphatic dissemination are the underlying factor (2, 3).

Unlike inflammatory changes in the lumbar spine, non-specific inflammatory changes in the vertebral corpuses of the cervical spine are very rare and as such associated with severe neurological deficits and mortality ranging between 0–11% (4). Moreover, they require very complex approach to treatment.

Material

Because of an extremely rare presence of non-specific inflammatory changes in the vertebral corpuses of the cervical spine, we will present a case of osteolytic inflammatory processes in segments C5, C6 and C7. The course of the disease, localization with a specific clinical presentation, and the complexity and adequacy of an appropriate the-

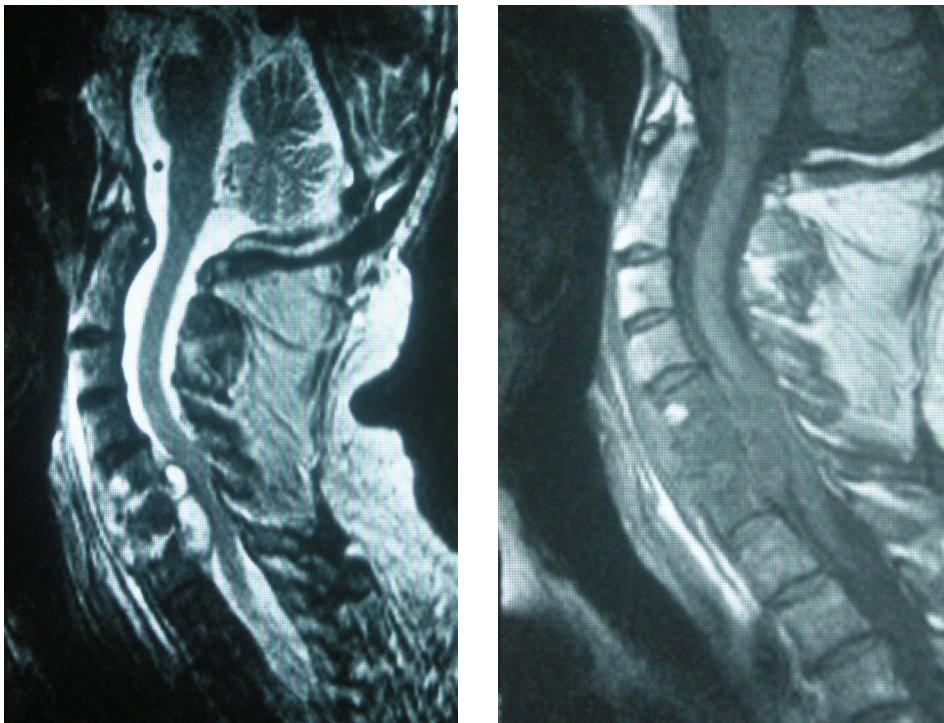


Figure 1: MRI finding: Destruction of C5 and C6, with the compression of the spinal canal

therapeutic procedure make this case interesting, with a possibility of providing proper recommendations towards making necessary diagnostic and therapeutic approaches for the detection and treatment of other patients with similar issues (5, 6).

The symptoms in a 52-year old male first occurred as a short-term bronchopneumonia. The patient was initially examined by the primary healthcare physician, who prescribed antibiotic therapy that calmed the cough and lowered the temperature. In the following period, however, the patient started to complain of periodic febrile and subfebrile episodes, which were successfully treated with antipyretics and antirheumatics. One month after the first symptoms of bronchopneumonia, the patient experienced pain in the neck, and after ten days also in his right hand. At this point, the pain was partially managed by introducing antirheumatic and corticosteroid therapy. The patient was referred to a neurologist who requested a cervical spine X-ray and EMG. The radiograph revealed an illumination in the region of the C5 corpus. Because of recurrent febrile episodes during the same period, with the temperature rising over 38.5 degrees, the patient was examined by an infectious disease specialist at the Clinic of Infectious Diseases. Chest X-ray, bloodculture and urinculture were taken as part of the diagnostic procedure. The findings did not indicate the cause of febrile episodes. During the examination at the Clinic of Infectious Diseases, severe weakness in the legs and development of severe paraparesis with the pre-existing weakness in the patient's right hand were reported. The ne-

urosurgeon indicated MRI of the cervical spine, which pointed to the presence of an expanding change in the spinal canal, epidurally at the level of the C5, C6 and C7 corpuses, and their destruction (Figure 1). The patient was transferred to the Clinic of Neurosurgery because of the development of severe quadriparesis.

Methodology and treatment plan

The treatment plan consisted of several stages:

- Additional diagnostic observations were necessary in order to make the final decision on further treatment (7). MSCT of the cervical spine, performed in order to define the expanding change, pointed to the existence of osteolytic changes in the C5, C6 and C7 corpuses, of osteomyelitic by type (Figure 2). Evoked potentials showed conduction interferences. The complete biohumoral status indicated the presence of chronic inflammatory process, with high levels of CRP (224 mg/l) and procalcitonin (18 µg/ml), regardless of the lower WBC count (18.0×10^9 /lit)

- Highly potent empiric antibiotic therapy was included (Meropenem and Vancomycin) (8).

- Emergency surgery was done as a result of the development of severe neurological deficit.

Surgical treatment of the acute osteomyelitic focus in the cervical spine is associated with several very important surgical problems:

- Addressing the issue of adequate decompression of the spinal cord and removing the corpuses affected by osteomyelitis and suppuration from the spinal canal.

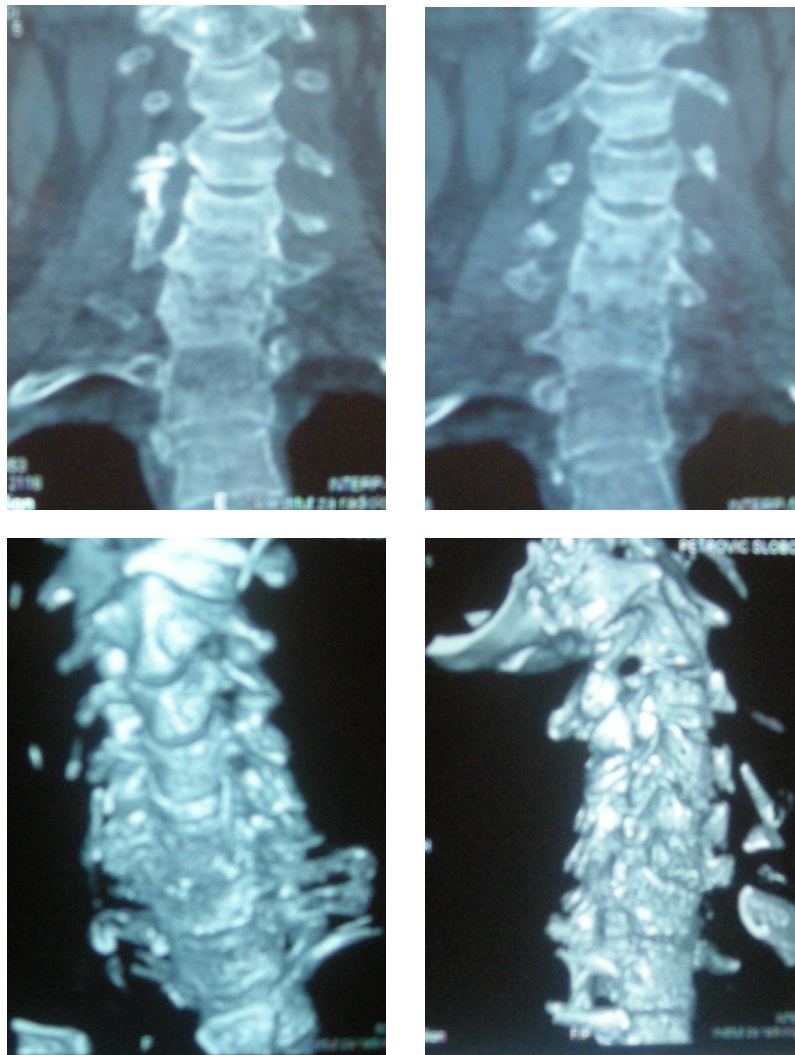


Figura 2: MSCT scan of the osteomyelitic lesion of the C5 and C6 corpuses

- The need for replacing the removed, inflamed bone tissue with appropriate material that would not be subject to colonization and progression of the process (9, 10).

- The need for performing high quality and complete stabilization and reconstruction of the cervical spine (11, 12).

It was decided to completely remove all the affected corpuses and surrounding tissue via anterior surgical approach, to clean the spinal canal and remove compression on the spinal cord (8). Complete removal of corpuses C5 and C6 and partial removal of corpus C7 were done. The corpuses were then replaced by inserting an artificial-implant made of acrylate and moulded so as to fit the required size and curvature of the space obtained after the removal of the corpuses, and fixation was done using the front titanium plate (13) (Figure 3). Next, the posterior stabilization including transarticular stabilization of C4, C5 and C6, and transpeduncular stabilization of C7 and Th1 were done in order to achieve adequate stability and reconstruction of the physiological lordosis of the spine (Figure 4).

The removed material was sent for antimicrobial susceptibility testing. The finding pointed to streptococcal infection. The intensive therapy with Meropenem and Vancomycin was continued (14) and laboratory findings were regularly monitored (SE, blood count, CRP). Immediately after the surgery and during the postoperative follow-up, the patient was involved in the rehabilitation procedures. After three weeks, the signs of inflammation began to subside.

Results

After the signs of inflammation became less intense, the patient was transferred to the Clinic of Physical Medicine and Rehabilitation. During the rehabilitation, one month after the surgical treatment, he regained movement in his legs and the motor functions were restored. Complete recovery was achieved two months after the surgery.

Control MSCT scan performed three months after the surgical treatment showed good stability and functionality of the cervical spine (Figure 5). Control X-ray of the cervical spine and MSCT per-

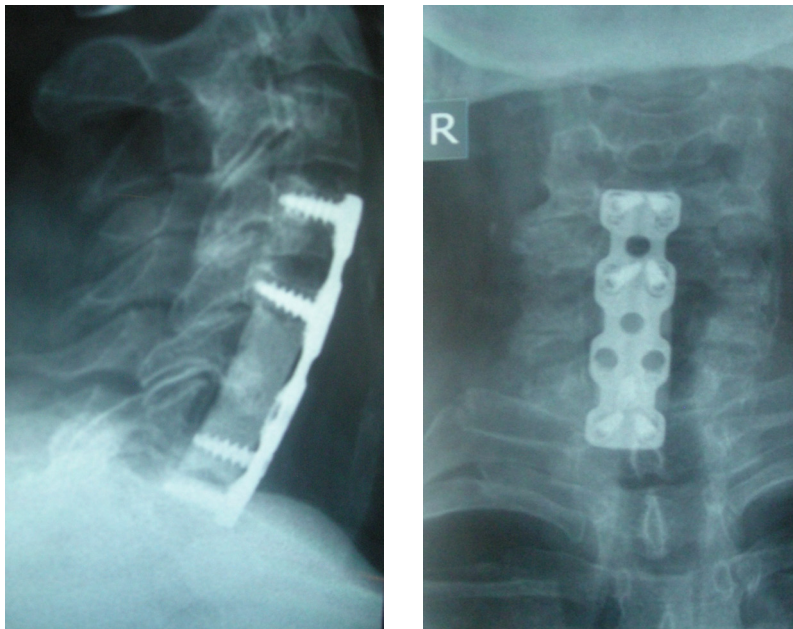


Figura 3 : X-ray scan after the anterior corpectomy of C5 and C6 and partial corpectomy of C7; replacement of the corpuses with acrylate material and fixation by means of anterior titanium plate

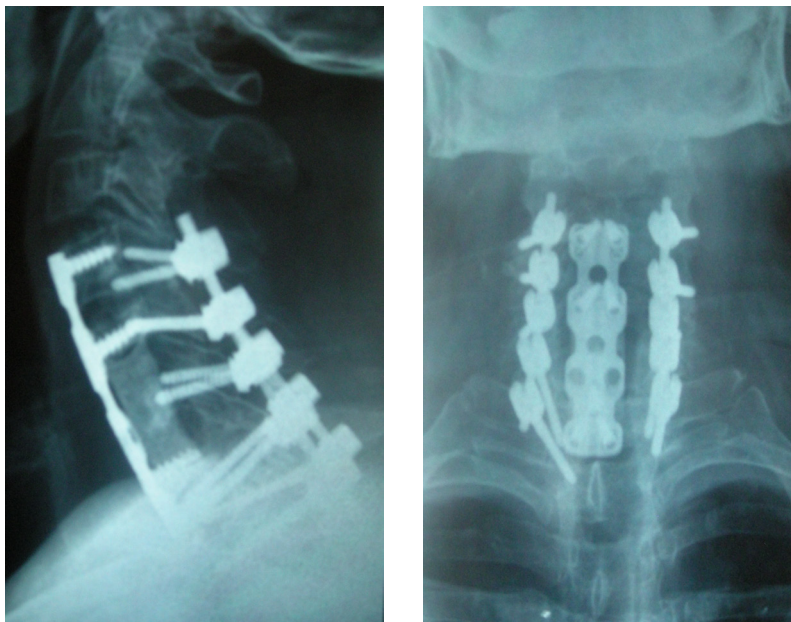


Figura 4: X-ray scan after the complete 3D reconstruction, with posterior transarticular fixation of C4, C5 and C6 and transpedicular fixation of C7 and Th1

formed after 6 months showed successful decompression and stabilization.

Discussion and Conclusion

Inflammatory processes of the spine are often clinically latent, until neurological disorders occur as a result of inflammatory or ischemic compression (15, 16).

Clinical manifestations can often begin with painful conditions, as a result of disturbances in the osteoligamentous structures, before compression on the nerve elements occurs. In addition,

the existence of signs of inflammatory changes in the biohumoral status (17) with the presence of non-specific subfebrile episodes may suggest the need for a diagnostic consideration of the corresponding regions of the spine, for the purpose of differential diagnostic elimination of dangerous and complex osteomyelitic processes. Early diagnosis of inflammatory changes in the spine may enable the processes to be remedied only by means of intensive medicamentous therapy (18), without the need for surgical treatment, which is very complex.

In the case of process development and of

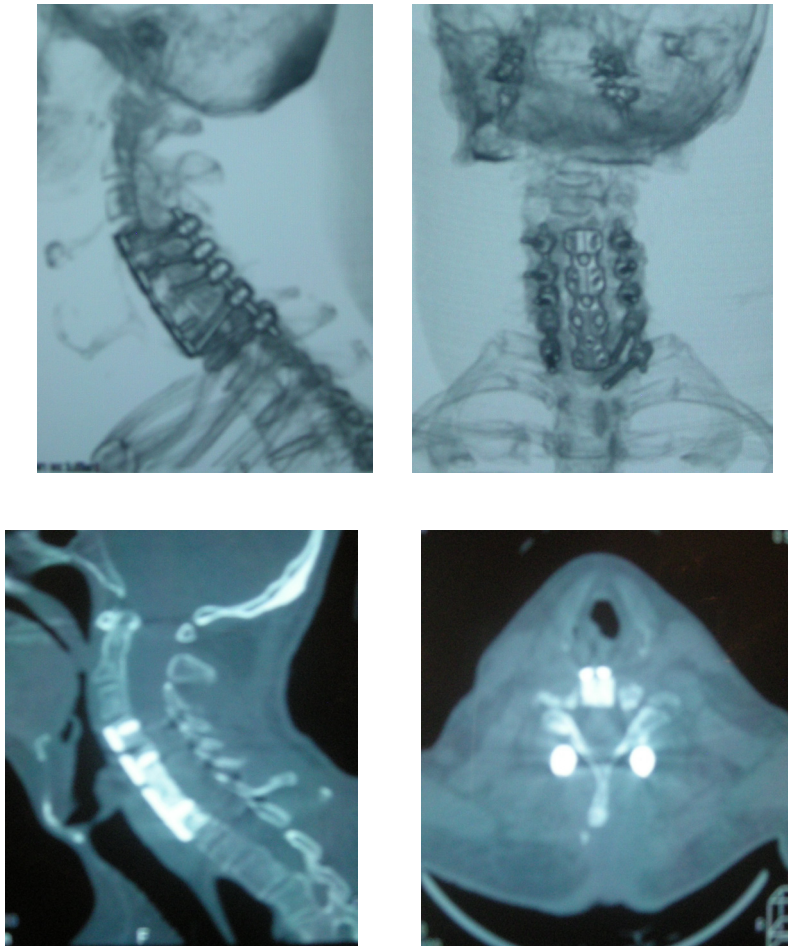


Figure 5: Control MSCT scan 6 months after surgery – good sagittal balance, no signs of osteomyelitic process

severe neurological deficits, which are the consequence of compression on the nerve elements, it is necessary to introduce aggressive antibiotic treatment and prepare the patient for emergency surgery (19) where, in spite of a well-planned surgical intervention, there is always a risk of serious postoperative complications (20, 21). There are

different modalities of surgical approach (22, - 24); however, the surgical intervention must always be radical, with complete eradication of the osteomyelitic process and the use of complete surgical stabilization of the spine, as the basic prerequisite for further recovery and positive results of the rehabilitation procedures (25 - 28).

References

1. Fantoni M, Trecarichi EM, Rossi B, Mazzotta V, Di Giacomo G, Nasto LA, Di Meo E, Pola E.: Epidemiological and clinical features of pyogenic spondylodiscitis. *Eur Rev Med Pharmacol Sci.* 2012 Apr;16Suppl 2:2-7. [\[PubMed\]](#)
2. Goulart CR, Mattei TA, Fiore ME, Thoman WJ, Mendel E.: Retropharyngeal abscess with secondary osteomyelitis and epidural abscess: proposed pathophysiological mechanism of an underrecognized
3. Al-Hourani K, Frost C, Mesfin A: Upper Cervical Epidural Abscess in a Patient With Parkinson Disease: A Case Report and Review. *Geriatr Orthop Surg Rehabil.* 2015 Dec;6(4):328-33. [\[CrossRef\]](#) [\[PubMed\]](#)
4. Boody BS, Jenkins TJ, Maslak J, Hsu WK, Patel AA.: Vertebral Osteomyelitis and Spinal Epidural complication of unstable cranio cervical injuries: case report. *J Neurosurg Spine.* 2016 Jan;24(1):197-205. [\[CrossRef\]](#)

- Abscess: An Evidence-based Review. *J Spinal Disord Tech.* 2015 Jul;28(6):E316-27. [[CrossRef](#)]([PubMed](#))
5. Darouiche RO, Hamill RJ, Greenberg SB, Weathers SW, Musher DM.: Bacterial spinal epidural abscess. Review of 43 cases and literature survey. *Medicine (Baltimore).* 1992 Nov;71(6):369-85. [[CrossRef](#)]
 6. Pigrau C, Rodríguez-Pardo D, Fernández-Hidalgo N, Moretó L, Pellise F, LarrosaMN, Puig M, Almirante B.: Health care associated hematogenous pyogenic vertebral osteomyelitis: a severe and potentially preventable infectious disease. *Medicine (Baltimore).* 2015 Jan;94(3):E365. [[CrossRef](#)]
 7. Cornett CA, Vincent SA, Crow J, Hewlett A.: Bacterial Spine Infections in Adults: Evaluation and Management. *J Am Acad Orthop Surg.* 2016 Jan; 24(1):11-8. [[CrossRef](#)]([PubMed](#))
 8. Hadjipavlou AG, Mader JT, Necessary JT, Muffoletto AJ.: Hematogenous pyogenic spinal infections and their surgical management. *Spine (Phila Pa 1976).* 2000 Jul 1;25(13):1668-79. [[CrossRef](#)]([PubMed](#))
 9. Ruf M, Stoltze D, Merk HR, Ames M, Harms J.: Treatment of vertebral osteomyelitis by radical debridement and stabilization using titanium mesh cages. *Spine (Phila Pa 1976).* 2007 Apr 20;32(9): E275-80. [[CrossRef](#)]
 10. Kankare J, Lindfors NC: Reconstruction of Vertebral Bone Defects using an Expandable Replacement Device and Bioactive Glass S53P4 in the Treatment of Vertebral Osteomyelitis: Three Patients and Three Pathogens. *Scand J Surg.* 2016 Feb 29. pii: 1457496915626834. [Epub ahead of print] [[CrossRef](#)]
 11. Skovrlj B, Guzman JZ, Caridi J, Cho SK.: Posterior-Only Circumferential Decompression and Reconstruction in the Surgical Management of Lumbar Vertebral Osteomyelitis. *Global Spine J.* 2016 Feb;6(1):E35-40. [[CrossRef](#)]
 12. KukloTR, PotterBK, BellRS, MoquinRR, Rosner MK.: Single-stage treatment of pyogenic spinal infection with titanium mesh cages. *J Spinal Disord Tech.* 2006 Jul;19(5):376-82 [[CrossRef](#)]([PubMed](#))
 13. Zhang ZX, Li T, Hao DJ: Single Stage Treatment of Osteomyelitis of the Cervical Spine Using Anterior Instrumentation and Titanium Mesh Cages. *Spine (Phila Pa 1976).* 2016 Feb 23. [Epub ahead of print] [[CrossRef](#)]
 14. Grados F, Lescure FX, Senneville E, Flipo RM, Schmit JL, Fardellone P.: Suggestions for managing pyogenic (non-tuberculous) discitis in adults. *Joint Bone Spine.* 2007 Mar;74(2):133-9. [[CrossRef](#)]([PubMed](#))
 15. Turgut M.: Complete recovery of acute paraplegia due to pyogenic thoracic spondylodiscitis with an epidural abscess. *Acta Neurochir (Wien).* 2008 Apr; 150(4):381-6. [[CrossRef](#)]([PubMed](#))
 16. Nishimura H, Uemura Y, Fukuda S, Kamada Y, Moriwaki T.: Two cases of pyogenic cervical discitis presenting tetraparesis. *No Shinkei Geka.* 2000 Jul;28(7):631-7. ([PubMed](#))
 17. Jeong DK, Lee HW, Kwon YM.: Clinical Value of Procalcitonin in Patients with Spinal Infection. *J Korean Neurosurg Soc.* 2015 Sep;58(3):271-5. [[CrossRef](#)]([PubMed](#))
 18. Park KH, Cho OH, Lee JH, Park JS, Ryu KN, Park SY, Lee YM, Chong YP, Kim SH, Lee SO, Choi SH, Bae IG, Kim YS, Woo JH, Lee MS. Optimal Duration of Antibiotic Therapy in Patients with Hematogenous Vertebral Osteomyelitis at Low Risk and High Risk of Recurrence. *Clin Infect Dis.* 2016 Feb 24. pii: ciw098. [Epub ahead of print] [[CrossRef](#)]([PubMed](#))
 19. Mohamed AS, Yoo J, Hart R, Ragel BT, Hiratzka J, Hamilton DK, Barnes PD, Ching AC: Posterior fixation without debridement for vertebral body osteomyelitis and discitis. *Neurosurg Focus.* 2014 Aug;37(2). [[CrossRef](#)]([PubMed](#))
 20. Miller JA, Achey RL, Derakhshan A, Lubelski D, Benzel EC, Mroz TE.: Neurologic Complications, Reoperation, and Clinical Outcomes After Surgery for Vertebral Osteomyelitis. *Spine (Phila Pa 1976).* 2016 Feb;41(4). [[CrossRef](#)]
 21. Spyropoulou V, Valaikaite R, Dhouib A, Dayer R, Ceroni D: Progression of Infection after Surgical CT Navigation-Assisted Aspiration Biopsy of a Vertebral Abscess. *Case Reports in Orthopedics Volume 2016,* Article ID 8675761, 5 pages <http://dx.doi.org/10.1155/2016/8675761> [[CrossRef](#)]
 22. Aranibar RJ, Del Monaco DC, Gonzales P.: Anterior Microscopic Transtubular (MITR) Surgical Approach for Cervical Pyogenic C1-2 Abscess: A Case Report. *Int J Spine Surg.* 2015 Oct 27;9:56. doi: 10.14444/2056. eCollection 2015. [[CrossRef](#)]
 23. Hasan MY, Kumar KK, Lwin S, Lau LL, Kumar N.: Cervical intradural abscess masquerading as an epidural collection. *Global Spine J.* 2013 Dec;3(4): 249-52. [[CrossRef](#)]([PubMed](#))
 24. Madhavan K, Vanni S, Williams SK: Direct lateral retroperitoneal approach for the surgical treatment of lumbar discitis and osteomyelitis. *Neurosurg Focus.* 2014 Aug;37(2). [[CrossRef](#)]
 25. Cheung WY, Luk KD.: Pyogenic spondylitis. *Int Orthop.* 2012 Feb;36(2):397-404. [[CrossRef](#)]([PubMed](#))
 26. Lee KY.: Comparison of pyogenic spondylitis and tuberculous spondylitis. *Asian Spine J.* 2014 Apr;8(2):216-23. [[CrossRef](#)]([PubMed](#))
 27. Korovessis P, Repantis T, Iliopoulos P, Hadjipavlou A.: Beneficial influence of titanium mesh cage on infection healing and spinal reconstruction in hematogenous septic spondylitis: a retrospective analysis of surgical outcome of twenty-five consecutive cases and review of literature. *Spine (Phila Pa 1976).* 2008 Oct 1;33(21):E759-67. [[CrossRef](#)]
 28. Theologis AA, Lansdown D, McClellan RT, Chou D, Pekmezci M: Multi-level Corpectomy with Anterior Column Reconstruction and Plating for Subaxial Cervical Osteomyelitis. *Spine (Phila Pa 1976).* 2016 Mar 10 [Epub ahead of print] [[CrossRef](#)]

**PREDNJA I ZADNJA STABILIZACIJA VRATNOG
DELA KIČME KOD OSTEOMIJELITIČNOG PROCESA
VIŠE PRŠLJENSKIH TELA - PRIKAZ SLUČAJA**

*Radisav Mitić¹, Nebojša Stojanović^{1,2}, Aleksandar Kostić^{1,2},
Ivan Cvetković¹, Zvonko Dželebdžić¹*

Klinika za neurohirurgiju, Klinički centar Niš, Srbija¹
Univerzitet u Nišu, Medicinski fakultet, Niš, Srbija²

Kontakt: Radisav Mitić
Klinika za neurohirurgiju, Klinički centar Niš, Srbija
Dr Zoran Đinđić. 48, 18000 Niš, Srbija
Mail: radisavmitic@gmail.com

Muškarac star 52 godine lečen je antibiotskom terapijom zbog kratkotrajne bronhopneumonije kod doktora opšte prakse, što je smirilo kašalj i oborilo temperaturu. U narednom periodu, bolesnik je počeo da se žali na febrilne i subfebrilne epizode. Mesec dana od početka bronhopneumonije javljaju se bolovi u vratu i utrnulost u desnoj ruci. Desetak dana kasnije, dolazi do razvoja slabosti u obe noge i u šaci desne ruke. Tokom ispitivanja na Klinici za infektivne bolesti razvija se teška spastična parapareza. Nuklearna magnetna rezonanca (NMR) i Multislajsna kompjuterizovana tomografija (MSCT) ukazale su na kompresiju medule u kičmenom kanalu u nivou C5 i C6, sa znacima destrukcije korpusa C5 i C6.

Zbog progresije neurološkog deficita bila je nužna hitna korpektomija C5 i C6 pršljenjskih tela, kao i parcijalna korpektomija C7 pršljenjskog tela, koja su zatim zamenjena implantom načinjenim od akrilata. Urađena je prednja stabilizacija, a zatim i zadnja cervikotorakalna stabilizacija.

Nakon intervencije, dolazi do poboljšavanja neurološkog deficita. Neurološka restitucija je postignuta nakon mesec dana od operacije. Urađene su redovne kontrole RTG-om i MSCT-om nakon tri i 6 meseci i nakon godinu dana. Dobijen je nalaz sa dobrom dekompresijom i stabilizacijom. Bolesnik je bio stabilan i bez neuroloških deficita.

Akutni osteomielitični procesi kičmenog stuba sa razvojem neuroloških deficita zahtevaju hitne hirurške procedure, uz rekonstrukciju kičme, primenom alotransplantata i 3D fiksacije, sa intenzivnom antibiotskom terapijom u dužem vremenskom trajanju. *Acta Medica Mediana* 2016;55(2):50-56.

Ključne reči: osteomyelitis, vratni pršljenovi, korpektomija, 3D stabilizacija

This work is licensed under a Creative Commons Attribution 4.0 International (CC BY 4.0) Licence