

DESCENDENT ATROPHY OF OPTIC NERVE AND SECONDARY BILATERAL GLAUCOMA AS COMPLICATIONS OF CAROTID-CAVERNOUS FISTULA AND ANEURISM: CASE REPORT

Marija Radenković², Gordana Stanković-Babić^{1,2}, Rade Babić^{1,3},
Jasmina Đorđević-Jocić^{1,2}, Marija Trenkić-Božinović², Maja Živković²

Endocranial aneurysm of the internal carotid artery (ICA) is a fusiform or saccular enlargement of the lumen of the blood vessel for at least 50 % of the anatomy diameter. Health problem occurs due to compression, rupture, thrombosis, or embolus. Carotid-cavernous fistula (CCF) is an abnormal communication between the carotid arterial system and cavernous sinus (arteriovenous fistula). According to communication, Barrow (1985) classifies four types of CCF: A, B, C, and D. Classification: direct-indirect, traumatic-spontaneous, high-low pressure. Clinical presentation: conjunctival congestion, orbital „brui“, pulsating exophthalmos, ophthalmoplegia externa, secondary glaucoma. The descendent atrophy of the optic nerve is due to a lesion of the third neuron of the visual pathway. Secondary glaucoma is exogenous due to elevated venous pressure (episcleral, v.vortikosae and ophthalmicae). Treatment: embolization of the fistula and medicamentous. Herein we present a case of a 59-year-old patient, operated due to the left carotid cavernous fistula and right aneurysm, blindness of the left eye one year after surgery due to descending optic nerve atrophy and concentric constriction of the visual field in the right eye as a result of untimely diagnosed secondary glaucoma after surgery. Presentation considers diagnostic and therapeutic approach to the patient in order to preserve vision in the functionally remaining eye. *Acta Medica Medianae* 2016;55(3):57-65.

Key words: carotid-cavernous fistula, secondary glaucoma, aneurysm of the internal carotid artery, optic nerve atrophy

University of Niš, Faculty of Medicine, Serbia¹
Clinic for Eye Diseases, Clinical Center Niš, Serbia²
Center of Radiology, Clinical Center Niš, Serbia³

Contact: Marija Radenković
Bulevar Nemanjića 67/41, Niš
E-mail: marad@verat.net

Introduction

Aneurysm is permanent, fusiform or saccular pathological enlargement of the arterial vessel lumen, at least 50% of the anatomy diameter. Aneurysms of the internal carotid artery (ICA, ACI) are very rare (0.27 - 5% of the total number of operations on the carotid arteries) (1). Internal carotid artery is a terminal branch of the common carotid artery (a.carotis communis). It is formed between C3 and C5 cervical vertebra via bifurcation of the common carotid artery to the internal (ICA) and external (ECA) carotid artery (2). Terminologia Anatomica (1998) subdivided

ACI into four segments: cervical, petrous, cavernous, and cerebral (3).

There are several classifications, and according to the basic anatomic localization, aneurysms of ACI are divided into extracranial and endocranial. A more detailed classification system with clinical implications by neuroradiologists, neurosurgeons and neurologists, recommended from Bouthillier et al. (1996), based on angiographic findings, identifies seven anatomical segments presented in the corresponding alphanumeric nomenclature (4)(Figure 1)

- C1: Cervical segment
- C2: Petrous (horizontal) segment
- C3: Lacerum segment
- C4: Cavernous segment
- C5: Clinoid segment
- C6: Ophthalmic (supraclinoid) segment
- C7: Terminal segment

Aneurysms of the carotid artery due to etiology could be true (a.vera) and false (pseudoaneurysm, a.spuria). True aneurysms are the most common consequences of atherosclerosis, arteritis, fibromuscular dysplasia, or infective etiology (mycotic). False aneurysms could be: post-traumatic, dissecting, and iatrogenic. They represent a serious medical problem due to compression of adja-

cent structures, rupture, thrombosis, or distal embolization. Mortality in unoperated population is about 70 %, and mycotic aneurysms rupture more often (1).

Carotidocavernous fistula (CCF, red eyed shunt Sy) is an abnormal communication between the carotid arterial system and cavernous sinus (Arterio Venous fistula) (5). They can be classified as: direct or indirect, spontaneous or traumatic, with high versus low pressure (due to velocity of blood flow) (6).

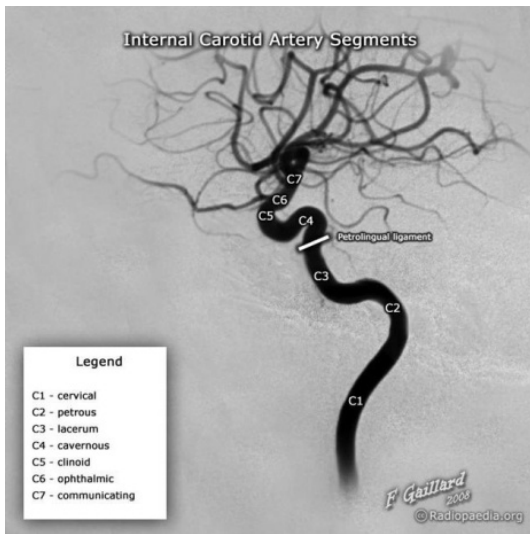


Figure 1. Segments of ACI according to Bouthillier

According to the communication, Barrow (1985) classifies CCF into four types: A, B, C, and D (2,6).

- Type A: Direct communication between the intracavernous segment of ICA and cavernous sinus (CS) (Figure 2)
- Type B: dural shunt between intracavernous branches of the ICA and sinus (CS) (Figure 3)
- Type C: dural shunts between meningeal branches of the ECA and CS (Figure 4)
- Type D: combined type of dural ICA and ECA shunt and CS (B + C type) (Figure 5)

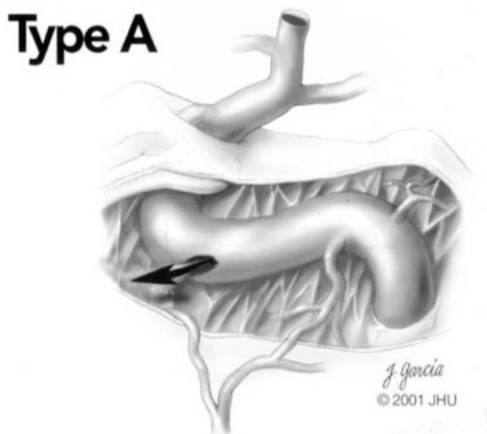


Figure 2. CCF (Barow, 1985) Type A: Direct communication of ICA with CCs

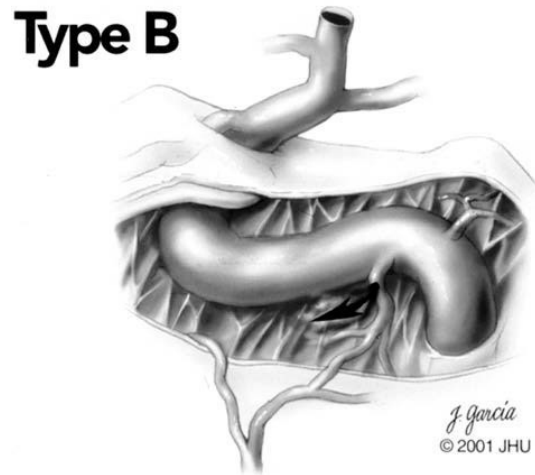


Figure 3. CCF (Barow, 1985) Type B: Communication between dural branches of ICA and CCs

Clinical presentation: reduction of visual acuity, conjunctival chemosis, exposure keratopathy, eyelid edema, headache, orbital noise (bruit), pulsating exophthalmos, proptosis, ophthalmoplegia externa, CRVO, BRVO, vitreous and/or retinal hemorrhage, tortuositas vasorum, proliferative retinopathy, edema of the optic disc, Atrophia n.optici, secondary glaucoma (7).

Diagnosis is made after the following testing:

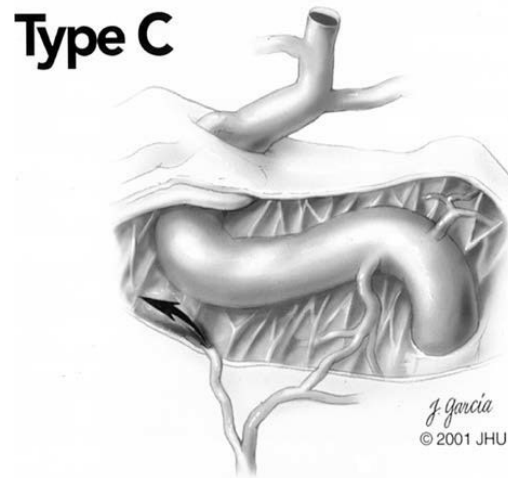


Figure 4. CCF (Barow, 1985) Type C: Communication between dural branches of ECA and CCs

- Clinical ophthalmological examination (Hertel exophthalmometry)
- Orbital echography (B scan): increased muscles and vv.opthalmicae sup / inf
- CT and/or MRI
- Cerebral arteriography with selective catheterization of ICA and ECA bilaterally
- Intra-arterial digital subtraction angiography (DSA)
- (Pneumo) Tonometry: increased pulse amplitude at the side of the lesion (6-8).

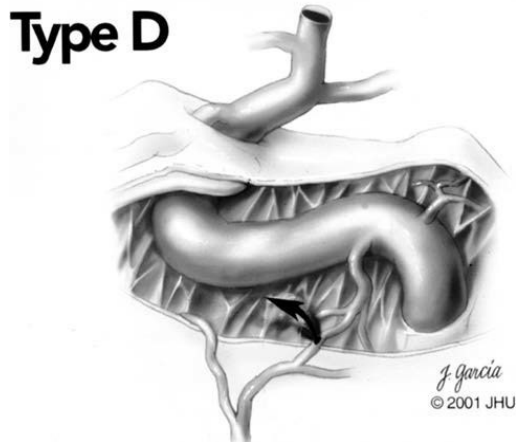


Figure 5. CCF (Barow, 1985) Type D: Combined type - communication between dural branches of ICA and ECA with CCs.

Differential diagnosis: thyroid ophthalmopathy, tumors of the orbit, orbital hemorrhage, myasthenia gravis, cavernous sinus Sy (sinus tumor, thrombosis, inflammatory lesions) (9).

Therapy:

-Medicamentous (artificial tears, antiglaucoma medications)

-Ophthalmosurgical (Tarsorrhaphy)

-Neurosurgical, including:

I) transcranial exploration of cavernous sinus with a ligature of the ICA proximal and distal to the fistula (rarely) and,

II) endovascular treatment via transarterial (direct) or transvenous access (indirect) by applying a thin platinum coil fiber embolization-coiling, balloon embolization or stent for aneurysm with wide neck. The diameter of the neck to perform coiling introduced in 1991, (by the author Guido Guglielmi) is 4 mm and the lumen less than 25 mm (10).

Clamping of an aneurysm in its neck is also possible (6, 9, 11).

The most common ophthalmic complications are: choroidal ablation, OVCR, descending atrophy of the optic nerve, and secondary glaucoma. The descending optic nerve atrophy occurs as a consequence of the lesion of the third neuron in visual pathway (12). Secondary glaucoma can be caused by different pathomechanisms, the most common being open-angle.

-Secondary open-angle glaucoma is exogenous, due to elevated venous pressure (episcleral, v.vortikosae and ophthalmicae sup/ inf).

-Closed angle glaucoma in rare cases, due to increased orbital venous pressure, and the following congestion of the iris and choroid, pushing the iridolental diaphragm forward (pushing mechanism), blocking the anterior chamber angle by iris root.

-Neovascular glaucoma is the rarest, described 1963 as a result of ocular ischemia and retinal angiopathy (5, 7, 13).

Case report

The patient, aged 59 years, underwent surgery at the Clinic of Neurosurgery (August 2006) for left-sided arterio-venous fistula (carotico-ophthalmicae), followed by sudden and intense headache, right hemiplegia, crisis of consciousness. In May 2007, previously diagnosed infraclinoid fusiform aneurysm of the internal carotid artery (ICA) in the right cavernous sinus was operated. Two to three years postoperatively, the patient was treated with antiepileptic drugs (Tbl.Phenobarbiton), and within antiedematous therapy Tbl. Acetazolamide 2x1 were administered. After the operation, the patient manifested transient bilateral external ophthalmoplegia that lasted several months, with spontaneous recovery of ophthalmoplegia and complete loss of vision in the left eye, after which in November 2007 for the first time computerized visual field examination was done. She visited to the referred ophthalmologist who due to elevated values of intraocular pressure (IOP) prescribed Sol Timolol 0.5 %. Patient was irregularly controlled further. The next visual field testing was done in 2008, but the therapy was interrupted by herself. First visit to the ophthalmologist at Clinic of Ophthalmology Niš, was in June 2011, due to repeated headaches and visual acuity control. At clinical examination residual discreet ptosis of the right eye was evident.

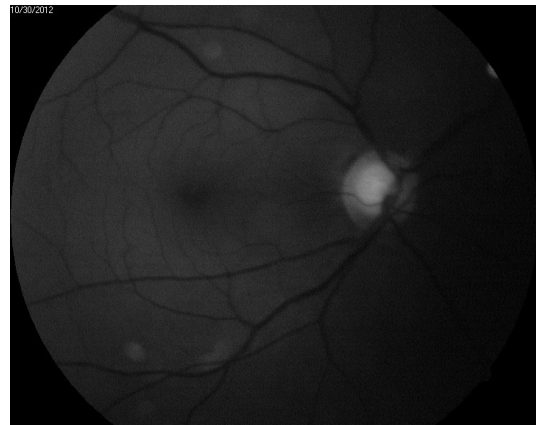

Figure 6. Ophthalmoscopy finding in the right eye (FOD)

Ophthalmologic examination found normal visual acuity of the right eye (VOD = 0.9-1.0), while in the left eye there was an apparent decline in visual acuity, reduced to light perception with accurate projection (VOS = L+P+). Intraocular tension measured by the Goldman applantation tonometer in both eyes was TOU = 22 mmHg. At slit-lamp (biomicroscopy), left pupil was mydriatic with sluggish reaction to light-relative afferent pupillary defect (SLOS: RAPD). Ophthalmoscopy revealed excavation of the optic nerve head, cup/disc ratio of the right eye C/ D = 0.6-0.7/II, and on the left C/D = 0.9-1.0/III. (Figure 6, 7)

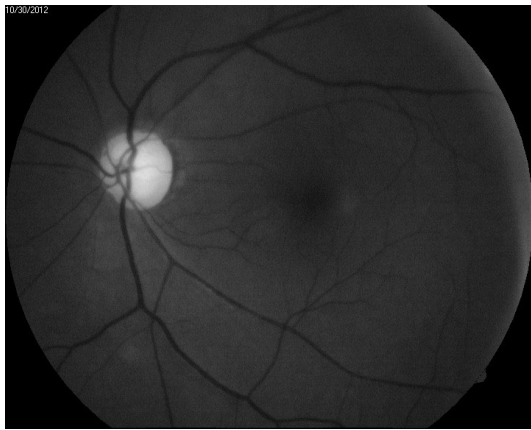

Figure 7. Ophthalmoscopy finding in the left eye (FOS)

Hospitalization for further detailed examinations was proposed and carried out, and the following diagnostic protocol was applied:

-Diurnal tonometry curve in the right eye: TOD = 16-22 mmHg; in the left eye, TOS=18-24 mmHg.

-Gonioscopy OU: Anterior chamber angle opened, grade III-IV (Shaffer), pigmentation grade I.

Insight into previous findings (visual field testing- Standard Automated Perimetry-SAP, OCT, electrophysiologic testing and MRI) showed:

-SAP Octopus (G1) (November 2007) OD: Concentric narrowing of the visual field to 15 degrees (MD=14.8 dB); OS: Sensitivity of the retina was not registered (MD=27.0 dB) (Figure 8, 9)

-OCT Stratus OCT RNFL average analysis 4.0.2: OD (2007) C/D = 0.59; RNFLavg = 70.06; Savg = 64; OS RNFL Avg = 39.31 (Figure 11)

-SAP Octopus (G1) (2008) OD: Rohene nasal step, inferiorly, Bjerrum in the forming (MD = 4,5dB) (Figure 10)

-VEP and ERG (January 2007)- ERG bilaterally normal; VEP OD: Normal N75-N145-P100 complex; OS P100 (128 ms), reduced amplitude.

-Magnetic resonance imaging (MRI) of endo-




Figure 9. Computed Perimetry OS Octopus (G1)

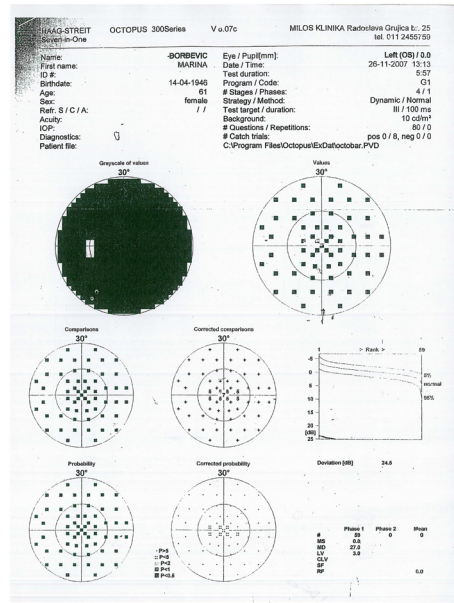


Figure 10. SAP OD Octopus (G1)

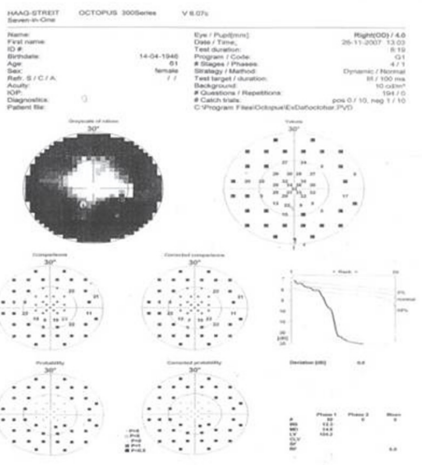


Figure 8. Computed Perimetry OD Octopus (G1)




Figure 11. OCT examination: OD and OS (2007)

cranium in T2 sequence, in transverse and coronary projection, and magnetic resonance angio-

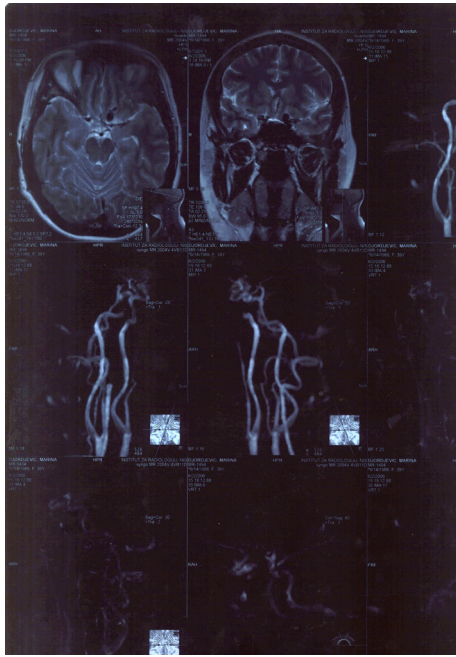


Figure 12. Magnetic resonance imaging (MRI) of endocranium

graphy of carotid and cerebral blood vessels. The left arteriovenous (AV) fistula (caroticoophthalmica) was visualized, clinically manifested by headache, right hemiplegia and crisis of consciousness

-MRI of endocranium and cranial CT (a year later): Magnetic resonance imaging (MRI) of endocranium in T2 sequence, the transverse and coronary

nary projection and magnetic resonance angiography of carotid and cerebral blood vessels were performed in a patient one year later. A fusiform infraclinoid aneurysm of ICA (internal carotid artery) in the cavernous sinus is presented on the right. Computed tomography (CT) of the cranium. Condition after craniotomy temporally on both sides. Brain tissue infra- and supratentorially without densitometry alterations. Discontinuity in the temporal bones because of surgical intervention. (Figure 12, 13a, 13b)

Testing during hospitalization:

1-SAP Humphrey FA(30-2) Threshold Test (2011): OD Confluent Bjerrum scotoma broke the nasal periphery (MD=23.37 dB; CPSD=10.92 dB). (Figure 14)

2-VEP/ERG (2011): FERG/PERG OU=without alterations; OD: VEP P100 = (100.5 ms); OS: Poorly designed responses of low amplitude.

3-Doppler sonography of neck blood vessels: normal finding.

The diagnosis of secondary glaucoma was established, and combined topical therapy was administered: Sol Timolol 0.5 % and Sol. Dolzolamide 2%, as oral therapy Tbl Vit B 2x1, Tbl Vinpocetin 10 mg 2x1.

Follow-up and testing were continued in glaucoma department:

-SAP Humphrey FA (30-2) threshold test (2012)OD: Residual central visual field island of 10-15 degrees (MD=26.22dB CPSD 9.93dB)(Figure 15).

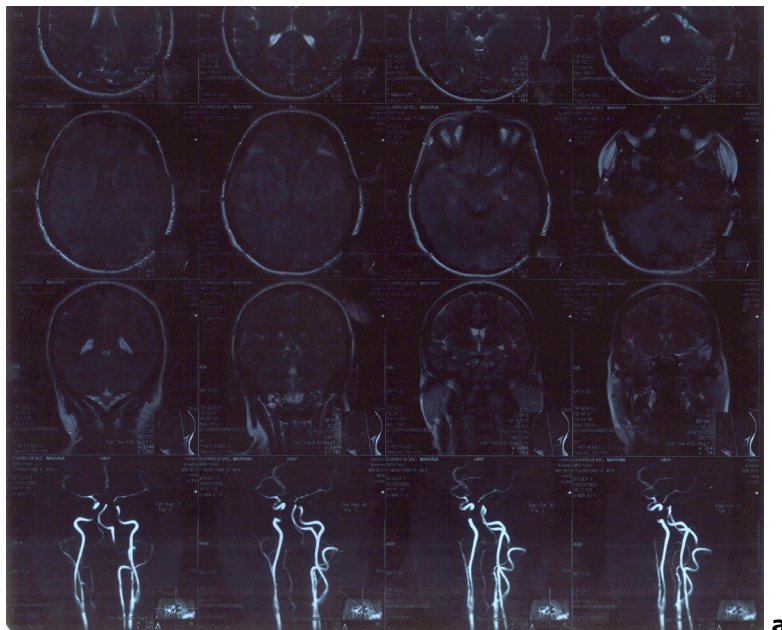


Figure 13. a Magnet Resonance Imaging (MRI) of endocranium in T2 sequence, the transverse and coronary projection and magnetic resonance angiography of carotid and cerebral blood vessels, a fusiform infraclinoid aneurysm of ICA (internal carotid artery) in cavernous sinus is presented on the right.

Figure 13. a, b Endocranial MRI and CT of the cranium (one year later)

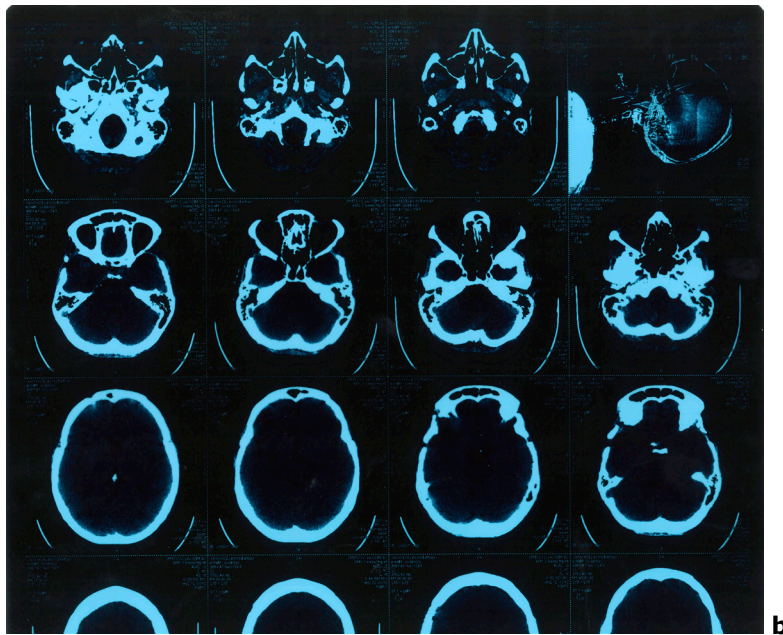


Figure 13. b Computed tomography (CT) of the cranium. Condition after craniotomy temporally on both sides. Brain tissue infra and supratentorially without densitometry alterations. Discontinuity in the temporal bones because of surgical intervention.

-OCT (Stratus OCT RNFL average analysis 6.0.4.) (2013) OD C/D = 0.719; RNFLavg = 62.74; Savg = 54. (Figure 16)

As findings showed the progression of the disease, the therapy in drops was corrected: Sol Timolol, Sol Dorzolamid and Sol Brimonidine 0.2 %. Due to allergic reactions to locally applied antiglaucoma drugs, the patient underwent allergy testing, which did not confirm any allergic reaction, and the patient went to a competent neurologist, who diagnosed trigeminal neuralgia.

Ophthalmologist prescribed therapy Sol. Dexamethasone-Neomycin for two weeks which improved the local findings. Within neuralgia, intermittent worsening of ptosis was apparent.

Due to the measured values of intraocular pressure TOU=20 mmHg, antiglaucoma therapy was corrected: Sol Timolol, Dorzolamide, Bri-monidine and Lata-noprost 0.005 %, which has reduced the IOP to TOD=13 mmHg/TOS=12 mmHg.

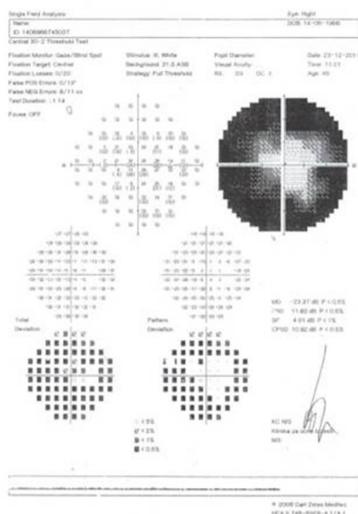


Figure 14. SAP OD(2011): Humphrey FA(30-2) threshold test

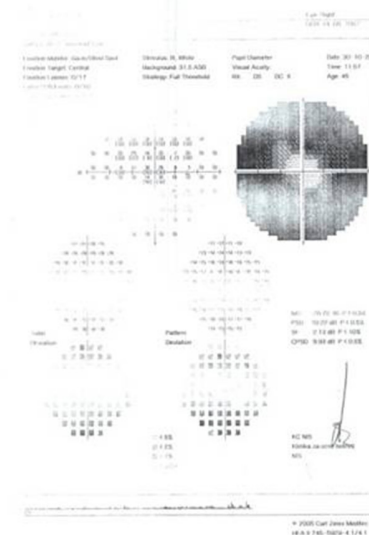


Figure 15. SAP OD (2012) Humphrey FA(30-2) threshold test.

Discussion

The prevalence of asymptomatic cerebral aneurysms varies from 0.2 % to 8.9 % in the general population, and 30 % of these patients have multiple aneurysms. Carotid-cavernous fistula (CCF) is represented with 12 % among all arteriovenous fistulas. Approximately, 70-90 % of

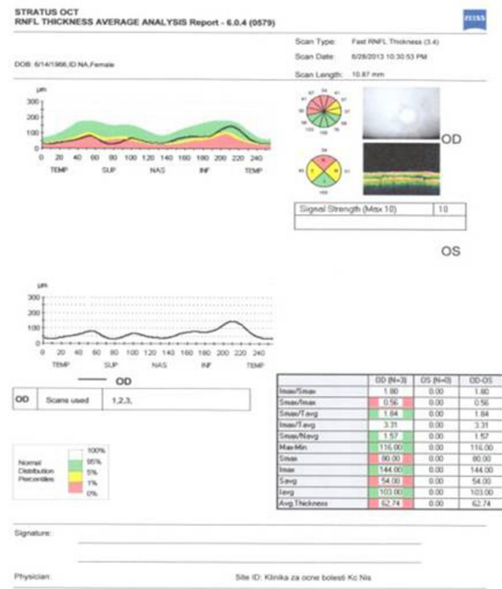


Figure 16. OCT OD (2013)

all CCF are direct fistulas, spontaneous, or traumatic remaining up to two years after injury (7, 14, 15). The patient with acute symptoms of CCF was taken care of as an emergency at the Clinic of Neurosurgery. Transient postoperative ophthalmoplegia was originated as a consequence of brain lesions in the lateral wall of the cavernous sinus (n. oculomotorius, trochlearis, V1 and V2 branches of n. trigeminus) and in sinus lumen (n. Abducens) (16). Loss of vision in the left eye was a consequence of cerebral pathological processes and neuronal lesions of visual pathway (12).

Administered postoperative edematous therapy (TbI Acetazolamide) had the effect of intraocular pressure lowering as the drug belongs to the group of carbonic anhydrase inhibitors. This enzyme is present in high concentration in the epithelium of the ciliary body, and therefore participates in the creation of aqueous humor. Its inhibition reduces the production of aqueous humor, and therefore the pressure in the eye. It can be concluded that the clinical manifestation of glaucoma was masked as an increase in IOP was noticed after discontinuation of the drug, and the

patient was referred to an ophthalmologist for the headaches (17, 18). The neuroprotective effect of the drug also showed transient reduction of the visual field loss in the interval 2007 to 2008. OCT finding and RNFL values indicates thinning on both sides, and although the electrophysiological study was pathological, functional tests were repeated. Computerized perimetry finding was a residual central island of vision, with indexes MD = 26.22 dB and CPSD = 9.93 dB.

Due to the loss of RGC, patients with glaucoma have abnormal PERG and PVEP, even with normal visual acuity. Extension of the P100 wave latency in patients with glaucoma indicates the importance of the function evaluation of the optic nerve in glaucoma, whether with or without a decreased visual acuity (17, 19). The clinical examination confirmed a suspicion of glaucoma, and local therapy was started as well as a systemic administration of neuroprotective drug (vinpocetine). Vinpocetine selectively inhibits Na⁺-channels and reduces extracellular Ca⁺⁺ concentration, which reduces excitotoxicity, as well as damage induced by ischemia/reperfusion (20). Correction of topical therapy was necessary in the presented case in order to control IOP and preserve visual function in the remaining eye. Despite the difficulty of movement in the darkness, ptosis operation was not indicated due to neurogenic etiology.

Conclusion

The paper presents a patient with severe, life-threatening vascular disease, which further caused the damage of n. opticus: compressive optic neuropathy on the left, with the descending consequent atrophy and glaucoma optic neuropathy of the right eye of exogenous origin. The resulting irreversible damage to the optic nerve affects the quality of patient life. This condition requires regular monitoring, while secondary glaucoma and glaucomatous optic neuropathy deserve special attention, timely diagnosis and treatment.

Note

We wish to thank Vladimir Radenković for technical assistance and processing contributions.

References

1. Radak Đ. Aneurizme karotidnih arterija; 2012. Available from: <http://www.vaskularnahirurgija.rs>
2. Jones J, et al. Internal carotid artery. 2005-2015. Available from: <http://radiopaedia.org/>
3. Dorland WA Newman. Internal carotid artery; Dorland's Illustrated Medical Dictionary 31st ed. Philadelphia (PA): Saunders; 2007. [[PubMed](#)]
4. Bouthillier A, van Loveren HR, Keller JT. Segments of the internal carotid artery: a new classification. *Neurosurgery* 1996; 38(3):425-32. [[PubMed](#)]
5. Chaudhry IA, Elkhamry SM, Al-Rashed W, Bosley TM. Carotid Cavernous Fistula: Ophthalmological Implications. *Middle East Afr J Ophthalmol* 2009; 16(2):57-63. [[PubMed](#)] [[CrossRef](#)]
6. Thinda S, Melson MR, Kuchtey RW. Worsening angle closure glaucoma and choroidal detachments subsequent to closure of a carotid cavernous fistula. *BMC ophthalmology* 2012;12:28. [[CrossRef](#)] [[PubMed](#)]
7. Scott I. Carotid Cavernous Fistula Differential Diagnosis [Internet]. Available from: <http://emedicine.medscape.com/article/1217766-differential>
8. Koenigsberg R. Carotid-Cavernous Fistula Imaging [Internet]. 2013. Available from: <http://emedicine.medscape.com/article/338870-overview>.
9. Chin Yee D. Carotid Cavernous Fistula [Internet]. 2015. Available from: [http://eyewiki.aaopt.org/Carotid_Cavernous_Fistula_\(Grand_Rounds\)](http://eyewiki.aaopt.org/Carotid_Cavernous_Fistula_(Grand_Rounds))
10. Ahmed AZ, Nassef A, Assad R. Endovascular treatment of carotid cavernous fistulae (CCF). Direct venous puncture using road mapping in dural CCF. *The Egyptian Journal of Radiology and Nuclear Medicine* 2013; 44(2):245-51. [[CrossRef](#)]
11. Strother CM. Electrothrombosis of Saccular Aneurysms via Endovascular Approach. Part 1 and Part 2. *Am J Neuroradiol* 2001; 22:1011-2.
12. Stefanović B, Pišteljić D, Krstić S, Stefanović I. Klinička neurooftalmologija. Drugo izdanje. Beograd: Zavod za udžbenike i nastavna sredstva; 1997.
13. Weiss DI, Shaffer RN, Nehrenberg TR. Neovascular Glaucoma Complicating Carotid-Cavernous Fistula. *Arch Ophthalmol* 1963; 69(3):304-7. [[PubMed](#)] [[CrossRef](#)]
14. Bickle I, D'Souza D. Saccular cerebral aneurysm [Internet]. Available from: <https://radiopaedia.org/articles/saccular-cerebral-aneurysm>
15. Nosko M. Caroticocavernous Fistula [Internet]. *Medscape: drugs, diseases & procedures* 2013. Available from: <http://emedicine.medscape.com/article/250591-overview>
16. Bilyk JR, Jakobiec FA. Embryology and Anatomy of the Orbit and Lacrimal System. Duane's Foundations of Clinical Ophthalmology. In: Tasman W, Jaeger EA, eds. *Ocular Anatomy, Embryology, and Teratology*. Chapter 32. Volume 1. Philadelphia (USA): Lippincott Williams & Wilkins; 2007.
17. Cvetković D, Kontić Đ, Hentova Senčanić P. Glaukom. Prvo izdanje. Beograd: Zavod za udžbenike i nastavna sredstva; 1996.
18. Hitchings R. Terminology and Guidelines for Glaucoma. 4th ed. Savona, Italy: EGS; 2014.
19. Djurić S. Evocirani potencijali. I Edicija. Niš: Prosveta; 2002.
20. Sitges M, Galván E, Nekrassov V. Vinpocetine blockade of sodium channels inhibits the rise in sodium and calcium induced by 4-aminopyridine in synaptosomes. *Neurochemistry International* 2005; 46(7):533-40. [[PubMed](#)] [[CrossRef](#)]

Prikaz bolesnika

UDC: 617.7-007.681:616.133-007.253

doi:10.5633/amm.2016.0308

DESCENDENTNA ATROFIJA N.OPTICI I BILATERALNI SEKUNDARNI GLAUKOM KAO KOMPLIKACIJE KAROTIDOKAVERNOZNE FISTULE I ANEURIZME: PRIKAZ SLUČAJA

Marija Radenković², Gordana Stanković-Babić^{1,2}, Rade Babić^{1,3},
Jasmina Đorđević-Jocić^{1,2}, Marija Trenkić-Božinović², Maja Živković²

Univerzitet u Nišu, Medicinski fakultet, Niš, Srbija¹
Klinika za očne bolesti, Klinički centar, Niš, Srbija²
Centar za radiologiju, Klinički centar, Niš, Srbija³

Kontakt: Marija Radenković
Bulevar Nemanjića 67/41, Niš
E mail: marad@verat.net

Endokranijalna aneurizma arterije carotis interne (ACI) je fuziformno ili sakularno proširenje lumena krvnog suda za najmanje 50% od anatomske. Predstavlja ozbiljan zdravstveni problem zbog kompresije, rupture, tromboze ili embolusa. Karotidokavernozna fistula (CCF) je patološka komunikacija arterijskog karotidnog sistema i sinus cavernosus (arterio-venska fistula). Prema komunikaciji, Barrow (1985) klasifikuje četiri tipa CCF: A, B, C i D. Klasifikacija: direktna-indirektna, spontana-traumatska, sa visokim-niskim pritiskom. Klinička prezentacija: kongestija vežnjače, orbitalni šum, pulzirajući egzoftalmus, ophthalmoplegia externa, sekundarni glaukom. Descendentna atrofija optikusa nastaje zbog lezije trećeg neurona vidnog puta. Sekundarni glaukom je egzogeni usled povišenog venskog pritiska (episkleralnog, v.vortikosae i ophthalmicae). Terapija: embolizacija fistule i medikamentozna. Radom je prikazana bolesnica stara 59 godina sa operisanom karotido-kavernoznom fistulom levo i aneurizmom desno, slepilom godinu dana nakon operacije na levom oku usled descendentne atrofije n.optici i koncentričnom konstrikcijom vidnog polja na preostalom desnom oku kao posledicom nepravovremeno dijagnostikovanog sekundarnog glaukoma nakon operacije. Prikaz razmatra dijagnostički i terapijski pristup, u cilju očuvanja vida na funkcionalno preostalom oku. *Acta Medica Medianae 2016;55(3):57-65.*

Ključne reči: karotidokavernozna fistula, sekundarni glaukom, aneurizma ACI, atrofija n.optici

This work is licensed under a Creative Commons Attribution 4.0 International (CC BY 4.0) Licence