

ANTERIOR SURGICAL APPROACH IN RESOLVING CERVICAL MYELOPATHY RESULTING FROM A MULTISEGMENTAL DEGENERATIVE PROCESS

Luka Berilažić¹, Nebojša Stojanović^{1,2}, Radisav Mitić¹, Aleksandar Kostić^{1,2},
Ivan Cvetković¹, Zvonko Dželebdžić¹

Progressive degenerative diseases of the cervical spine are an increasingly common cause of the development of cervical myelopathy.

The analysis was performed on 67 surgically treated patients with multisegmental degenerative processes of the cervical spine. Thirty-three patients underwent surgical treatment on two levels, 25 on 3 levels and 9 on 4 levels. Muscle strength and control cervical spine X-ray were monitored pre- and postoperatively; control MRI was performed after 6 months of surgery.

All the patients recovered to a higher or lower extent, and the progression of neurological deficits stopped in all of them. In 7 patients, certain swallowing problems were observed. Two patients underwent revision due to the intrusion of titanium grafts into the corpora and front destabilization. Three patients underwent repeat surgery after one year, whereby segmental approach was expanded from two to three and from three to four levels. In 13 patients, problems with the extent of neck rotation were registered, but this did not affect their normal life activities. The finding resulting from the muscle strength monitoring of the most affected group of muscles indicates a significant improvement with respect to all levels of preoperative motor weakness.

The presence of chronic pain syndrome and the development of neurological deficits in correlation with the MRI finding represent an absolute indication for surgical treatment. The anterior surgical approach not only eliminates the causes of compression of the neurovascular elements, but also provides correction of the intervertebral disc space height, correction of kyphosis and the loss of lordosis.

Acta Medica Medianae 2018;57(3):XX-XX.

Key words: Cervical myelopathy, cervical disc herniation, anterior approach to the cervical spine

¹Clinic for Neurosurgery, Clinical Center Niš, Niš, Serbia

²University of Niš, Faculty of Medicine, Niš, Serbia

Contact: Nebojša Stojanović
Neurosurgery Clinic, Clinical Center Niš,
Zorana Djindjića 48, 18 000 Niš, Serbia
E-mail: nesamed59@gmail.com

Introduction

Degenerative processes in the cervical spine are the result of biochemical, biomechanical and morphological changes in the cervical intervertebral

discs (1-4). These processes result in the narrowing of the intervertebral space with the development of a compressive effect on neurovascular elements in intravertebral foramina, and a clinical picture of peripheral neurological deficit (5, 6). Compression of the degenerately altered intervertebral disc on neurovascular elements in the spinal canal leads to the development of a central neurological deficit (7).

Combination of these clinical symptoms forms a cervical myelopathy syndrome. Cervical myelopathy is the most common consequence of the multisegmental degenerative process in the cervical spine. The clinical picture is characterised by a gradual, long-term development of symptoms (8, 9).

The most common approach to treating these patients is conservative, so patients first report neurosurgical examination in the second, and most often in the third and fourth stage of the clinical picture. Good postoperative clinical course is directly related to the preoperative duration of ailments and the stage at which patients undergo surgery.

Material and methods

The analysis was performed on 67 patients with multisegmental degenerative changes in the cervical spine, who had a clear clinical picture of cervical myelopathy. Patients were operated on at the Neurosurgical clinic in Niš, in the period from 2010 to 2016. Thirty-three patients were operated on at two levels, 25 patients on three levels and 9 patients on four levels.

The clinical picture was divided into four stages:

- The first stage - numbness in the neck, intermittent pain along the neck and arms, recurrence of ailments

- Second stage - long-lasting pain in the neck and along the arms, headaches, dizziness, buzzing in the ears, instability while walking, nonspecific vegetative complaints in the form of tightness in the chest, heart palpitations, changes in vision

- Third stage - pain along the arms with the occurrence of hypotrophy of the respective muscle group, permanent discomfort regardless of activity, position or time of day, feeling of weakness in legs and walking difficulty

- Fourth stage - the development of severe motor disorders of monoparesis, hemiparesis, tripareisis or quadripareisis type

Surgery was performed on 23 patients with clinical stage II, 23 patients with clinical stage III, and 21 patients with clinical stage IV.

All patients were treated by applying multisegmental surgical approach. Complete release of intravertebral disc space was performed with the release of lateral recesses, resection of the posterior longitudinal ligament and removal of marginal osteophytes from the spinal canal. At each level, distraction of intervertebral disc space, insertion of titanium cage (cagea) and correction of intervertebral space height with consequent correction of kyphosis in that segment of the spinal cord was performed. Afterwards, the front multisegmental stabilization with a titanium plate was obligatory.

The follow-up of patients was performed by monitoring the clinical and neurological status. The numerical index of the motor strength of the most affected group of muscles was monitored preoperatively and postoperatively.

The British Medical Research scale was used to grade muscle strength:

- 1 - A noticeable or palpatory contraction, without the ability to perform movement

- 2 - Possible movement under the condition of eliminating the earth's weight

- 3 - Possibility of movement versus earth's weight

- 4 - The ability to move with less resistance (light partial paralysis)

- 5 - Normal muscle strength

Immediately after surgery, a clinical and radiological evaluation was performed. After 6 months, EMG and X-ray findings were obtained.

MSCT or MRI findings were obtained after 6 to 8 months of surgery.

Results and Discussion

Of the 67 patients, 41 (61%) were women, and 26 (39%) were men. The average age of patients ranged 52.6 ± 11.2 in women, and 56.4 ± 9.2 in men, which stands in correlation with the studies where patients were treated with anterior multisegmental approach (10, 11).

All the patients recovered to a higher or lower extent, and in all of them the progression of neurological deficit stopped. In the patients' preoperative status, a statistically significantly higher representation of the motor index of 1 to 3 was observed, compared to the postoperative status of patients with a significantly higher representation of the motor index of 3 to 5 ($p < 0.05$). In 7 (10.4%) patients, there were certain swallowing problems in the postoperative period of 3 to 5 months, which is consistent with the results of other studies, ranging from 1 to 79% (12, 13).

Two patients underwent revision after two months of surgery due to the intrusion of titanium cages into the corpuses and destabilization of the front fixation plate (2.9%). Three patients underwent a repeat surgery due to the development of symptomatology to a level above surgical treatment (4.5%), (8, 14), which is correlated with other studies (in two patients, the surgical approach was expanded from two to three levels and from three to four levels).

It was observed that despite applying the multisegmental approach, in only 13 (19.4%) patients there were some problems in terms of reduced head rotation, but this did not affect their normal life activities. Reduced mobility of the neck is part of the multisegmental approach in resolving cervical myelopathy. The finding is in correlation with other studies (15, 16).

All the patients had minimal blood loss. The duration of surgery was from 2.5 - 4 hours. There was no postoperative deterioration of the neurological deficit in any of the cases. The patients were verticalized immediately after 24 hours. The results are in correlation with the world studies (17, 18)

The finding obtained at 6 months of surgery by monitoring the motor strength of the most affected muscle group indicates a significant improvement with respect to all the levels of preoperative motor weakness (Table 1, 2). Postoperative monitoring of X-ray and MRI findings shows a fully corrected neck kyphosis and decompression of the spinal canal and nerve elements in all of the patients (Figure 1, 2, 3).

Conclusion

The anterior surgical approach to multisegmental degenerative processes in the cervical spine allows for complete removal of the pathological substrate directly responsible for the development of clinical picture and neurological defi-

Table 1. Operative treatment levels in patients with cervical myelopathy (localization and degree of neurological damage of the affected muscle group)

NEUROLOGICAL DAMAGE		0 - 1	1 - 2	2 - 3	3 - 4	4 - 5
C3 / C4, C4 / C5	8	/	1	2	3	2
C4 / C5, C5 / C6	14	33 (49,3 %)	1	3	7	2
C5 / C6, C6 / C7	11		3	4	2	1
C3/C4, C4/C5 C5/C6	8		1	4	2	/
C4/C5, C5/C6 C6/C7	17	25 (37,3 %)	2	8	3	/
C3/C4, C4/C5, C5/C6, C6/C7	9	9 (13,4 %)	3	2	1	/
	67 (100 %)	8 (12 %)	13 (19,5%)	23 (34%)	18 (27%)	5 (7,5%)

Table 2. Degree of damage of the most affected muscle group six months after operation

NEUROLOGICAL DAMAGE		0 - 1	1 - 2	2 - 3	3 - 4	4 - 5
C3 / C4, C4 / C5	8	/	/	2	2	4
C4 / C5, C5 / C6	14	33 (49,3 %)	/	1	8	5
C5 / C6, C6 / C7	11		1	4	4	2
C3/C4, C4/C5 C5/C6	8		/	2	4	1
C4/C5, C5/C6 C6/C7	17	25 (37,3 %)	1	4	6	4
C3/C4, C4/C5, C5/C6, C6/C7	9	5 (13,4 %)	1	3	3	/
	67 (100 %)	3 (4,5 %)	5 (7,5 %)	16 (24 %)	27 (40 %)	16 (24 %)

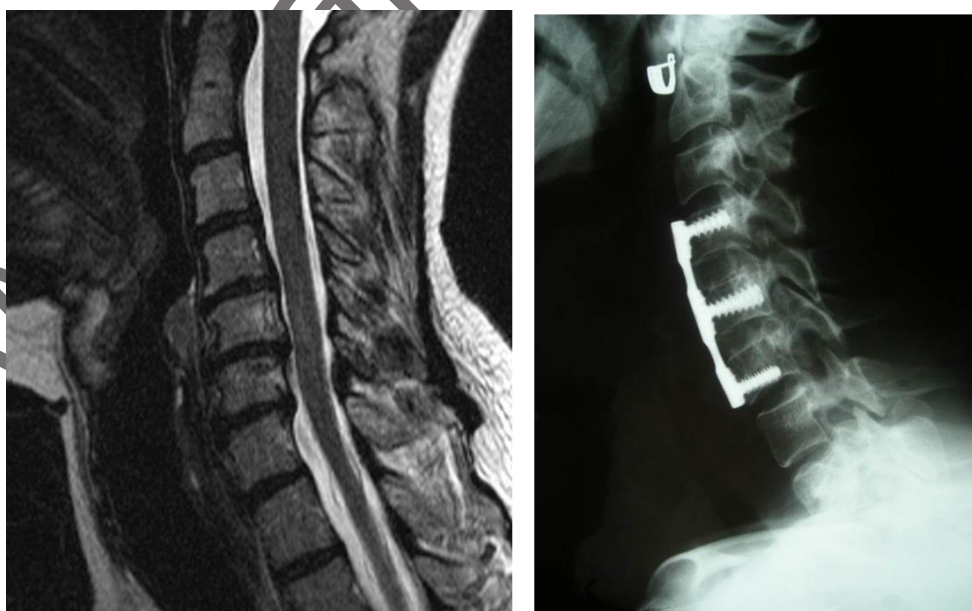

Figure 1. Treatment of two levels / corrected kyphosis

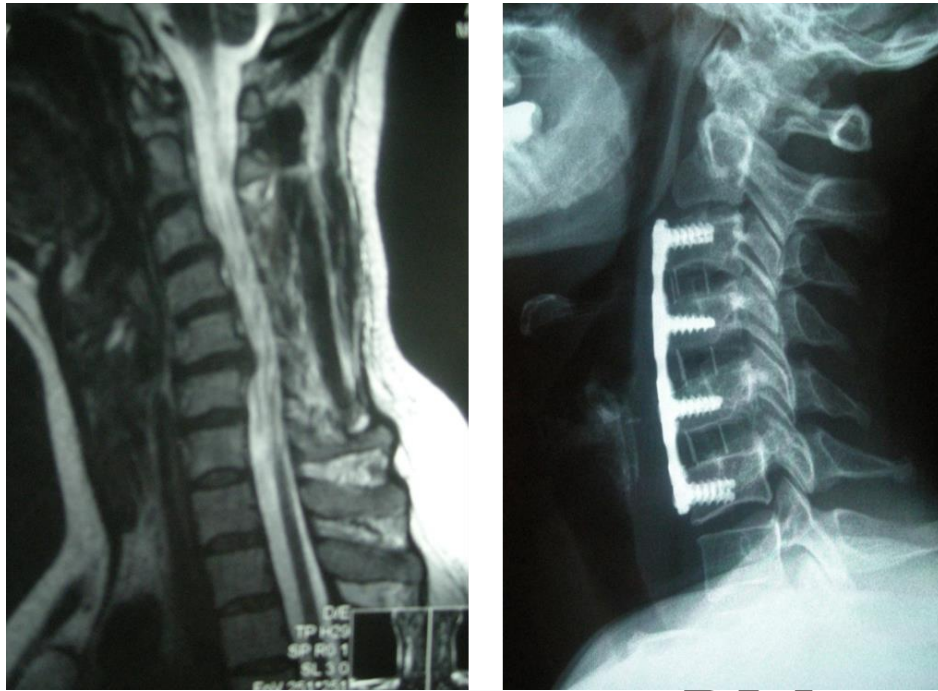


Figure 2. Treated three levels / corrected kyphosis

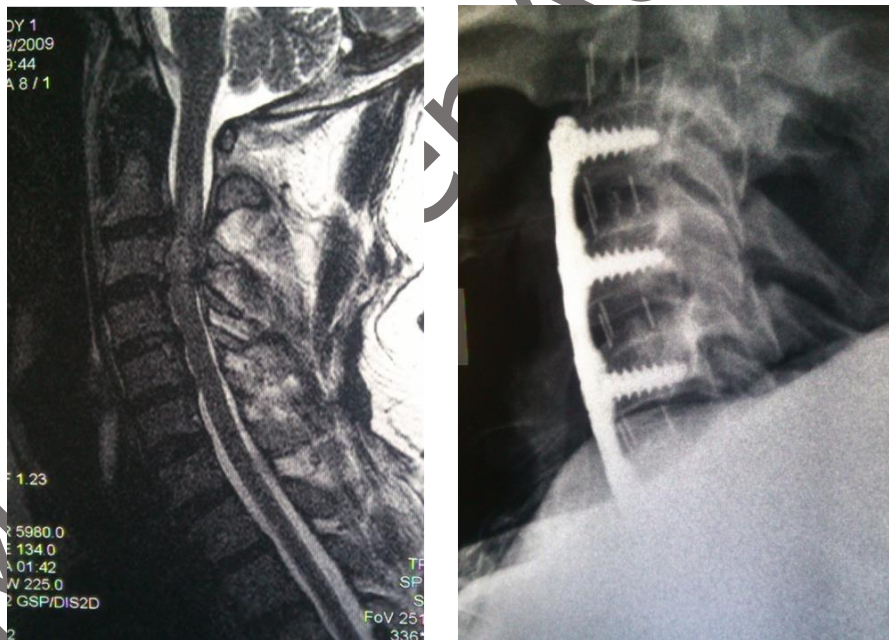


Figure 3. Treated four levels

cits. In addition, after removal of degenerately altered disc herniation, osteophytes and stenosis of the lateral recesses, the physiological height of the intervertebral disc space is restored at all affected levels, with complete correction of the present kyphosis in this segment of the cervical spine. The importance of such surgical approach is indicated by other studies as well (11, 19, 20).

After correction of the intervertebral disc space height, we always applied the anterior plate

fixation of all affected levels, which in none of the cases resulted in the development of postoperative kyphosis, as opposed to the surgical technique where only intercorporeal fusion was performed without the anterior fixation (21).

The indication for surgical treatment can be clearly set out in the following cases:

- The presence of stenosis of the spinal canal with stenosis of the lateral recesses, with clinical signs of intermittent cervicobrachialgia, and

resistance to medication therapy, is an indication for surgical treatment, as a prevention of the development of a complete clinical picture of cervical myelopathy.

- Pain in the neck with cervicobrachialgia and with clear MRI signs of multisegmental anterior compressions and signs of cervical myelopathy, are a clear indication for surgical treatment.

- Neurological deficit of monoparesis, tripareisis or quadriparesis type, with clear MRI findings of degenerative multisegmental stenoses in the cervical spine represent an absolute indication for surgical treatment

The anterior multisegmental approach to degenerative processes has an advantage over posterior surgical approach, because complete

decompression of the neurovascular elements is achieved with the correction of the position of the cervical spine and restoration of mechanical stability (10, 19, 22, 23).

By using posterior decompression and laminectomy, mechanical stability in the cervical spine can be exacerbated, which is why the posterior stabilization should often be done. In addition, it does not lead to the expected recovery of neurological deficits (17, 24, 25).

Postoperative results largely depend on the stage of disease prior to performing surgery. The greater the degree of clinical and neurological damage is, the slower and more difficult the recovery will be.

References

1. Al Fadhli R, Ohtori S, Inoue G, Miyagi M, Takahashi K. Pathomechanisms of discogenic low back pain in humans and animal models. *Spine J* 2015; 15(6): 1347-55. [[CrossRef](#)][[PubMed](#)]
2. Yee A, Lam MP, Tam V, Chan WC, Chu IK, Cheah KS, et al. Fibrotic-like changes in degenerate human intervertebral discs revealed by quantitative proteomic analysis. *Osteoarthritis Cartilage* 2016; 24(3): 503-13. [[CrossRef](#)][[PubMed](#)]
3. Miyagi M, Ishikawa T, Kamoda H, Suzuki M, Murakami K, Shibayama M, et al. ISSLS prize winner: disc dynamic compression in rats produces long-lasting increases in inflammatory mediators in discs and induces long-lasting nerve injury and regeneration of the afferent fibers innervating discs: a pathomechanism for chronic discogenic low back pain. *Spine (Phila Pa 1976)* 2012;37(21): 1810-8. [[CrossRef](#)][[PubMed](#)]
4. Kepler CK, Markova DZ, Dibra F, Yadla S, Vaccaro AR, Risbud MV, et al. Expression and relationship of proinflammatory chemokine RANTES/CCL5 and cytokine IL-1 β in painful human intervertebral discs. *Spine (Phila Pa 1976)* 2013; 38(11): 873-80. [[CrossRef](#)][[PubMed](#)]
5. García-Cosamalón J, del Valle ME, Calavia MG, García-Suárez O, López-Muñiz A, Otero J, et al. Intervertebral disc, sensory nerves and neurotrophins: who is who in discogenic pain? *J Anat* 2010; 217(1): 1-15. [[CrossRef](#)][[PubMed](#)]
6. Kim B, Yoon DH, Shin HC, Kim KN, Yi S, Shin DA, et al. Surgical outcome and prognostic factors of anterior decompression and fusion for cervical compressive myelopathy due to ossification of the posterior longitudinal ligament. *Spine J* 2015; 15(5): 875-84. [[CrossRef](#)][[PubMed](#)]
7. Rao R. Neck pain, cervical radiculopathy, and cervical myelopathy: pathophysiology, natural history/clinical evaluation. *Instr Course Lect* 2003; 52: 479-88. [[CrossRef](#)][[PubMed](#)]
8. Zhu B, Xu Y, Liu X, Liu Z, Dang G. Anterior approach versus posterior approach for the treatment of multilevel cervical spondylotic myelopathy: a systemic review and meta-analysis. *Eur Spine J* 2013; 22-7. [[CrossRef](#)]
9. Risbud M V, Shapiro IM. Role of Cytokines in Intervertebral Disc Degeneration: Pain and Disc-content. *Nat Rev Rheumatol* 2014; 10(1): 44-56. [[CrossRef](#)][[PubMed](#)]
10. Wu D, Liu CZ, Yang H, Li H, Chen N. Surgical interventions for cervical spondylosis due to ossification of posterior longitudinal ligament: A meta-analysis. *Medicine (Baltimore)* 2017; 96(33): e7590. [[CrossRef](#)][[PubMed](#)]
11. Wang HM, Liu HY, Wang B, Zhang J, Miao KN, Chen Z. Treatment of cervical spondylotic myelopathy by decompression of spinal canal and internal fixation with the combination of anterior and posterior approaches. *Zhonghua Yi Xue Za Zhi* 2007; 87(1): 28-31. [[PubMed](#)]
12. Anderson KK, Arnold PM. Oropharyngeal Dysphagia after Anterior Cervical Spine Surgery: A Review. *Global Spine J* 2013; 3(4): 273-86. [[CrossRef](#)][[PubMed](#)]
13. Shriver MF, Lewis DJ, Kshetry VR, Benzel EC, Mroz TE. Dysphagia Rates after Anterior Cervical Discectomy and Fusion: A Systematic Review and Meta-Analysis. *Global Spine J* 2017; 7(1): 95-103. [[CrossRef](#)][[PubMed](#)]
14. Sun Y, Li L, Zhao J, Gu R. Comparison between anterior approaches and posterior approaches for the treatment of multilevel cervical spondylotic

- myelopathy: A meta-analysis. *Clin Neurol Neurosurg* 2015; 134: 28-36. [[CrossRef](#)][[PubMed](#)]
15. Yeung JT, Johnson JI, Karim SA. Cervical disc herniation presenting with neck pain and contralateral symptoms: a case report. *J Med Case Rep* 2012; 6: 166. [[CrossRef](#)][[PubMed](#)]
 16. Martín R, Carda JR, Montaña F, Pinto JI, Sanz F, Paternina B, et al. Cervical myelopathy: retrospective analysis of surgical results in 53 cases treated by anterior cervical discectomy and interbody fusion. *Neurocirugía (Astur)* 2005; 16(3): 235-55. [[CrossRef](#)][[PubMed](#)]
 17. Huang D, Du X, Liang H, Hu W, Hu H, Cheng X. Anterior corpectomy versus posterior laminoplasty for the treatment of multilevel cervical myelopathy: A meta-analysis. *Int J Surg* 2016; 35: 21-27. [[CrossRef](#)][[PubMed](#)]
 18. Jiang L, Tan M, Dong L, Yang F, Yi P, Tang X, et al. Comparison of Anterior Decompression and Fusion With Posterior Laminoplasty for Multilevel Cervical Compressive Myelopathy: A Systematic Review and Meta-Analysis. *J Spinal Disord Tech* 2015; 28(8):282-90. [[CrossRef](#)][[PubMed](#)]
 19. Aryan HE, Sanchez-Mejia RO, Ben-Haim S, Ames CP. Successful treatment of cervical myelopathy with minimal morbidity by circumferential decompression and fusion. *Eur Spine J* 2007; 16(9): 1401-9. [[CrossRef](#)][[PubMed](#)]
 20. Meng Z, Yu J, Luo C, Liu X, Jiang W, et al. Anterior Cervical Spondylosis Surgical Interventions are Associated with Improved Lordosis and Neurological Outcomes at Latest Follow up: A Meta-analysis. *Sci Rep* 2017; 7-8. [[CrossRef](#)]
 21. Masaki Y, Yamazaki M, Okawa A, Aramomi M, Hashimoto M, Koda M, et al. An analysis of factors causing poor surgical outcome in patients with cervical myelopathy due to ossification of the posterior longitudinal ligament: anterior decompression with spinal fusion versus laminoplasty. *J Spinal Disord Tech* 2007; 20(1): 7-13. [[CrossRef](#)][[PubMed](#)]
 22. Landers MR, Addis KA, Longhurst JK, Vom Steeg BL, Puentedura EJ, Daubs MD. Anterior cervical decompression and fusion on neck range of motion, pain, and function: a prospective analysis. *Spine J* 2013; 13(11): 1650-8. [[CrossRef](#)][[PubMed](#)]
 23. Uchida K, Nakajima H, Sato R, Yayama T, Mwaka ES, Kobayashi S, et al. Cervical spondylotic myelopathy associated with kyphosis or sagittal sigmoid alignment: outcome after anterior or posterior decompression. *J Neurosurg Spine* 2009; 11(5): 521-8. [[CrossRef](#)][[PubMed](#)]
 24. Mehdorn HM, Fritsch MJ, Stiller RU. Treatment options and results in cervical myelopathy. *Acta Neurochir Suppl* 2005; 93: 177-82. [[CrossRef](#)][[PubMed](#)]
 25. Epstein NE. Spine surgery in geriatric patients: Sometimes unnecessary, too much, or too little. *Surg Neurol Int* 2011; 2: 188. [[CrossRef](#)][[PubMed](#)]
 - 26.

AMM Paper Accepted

PREDNJI OPERATIVNI PRISTUP U REŠAVANJU CERVICALNE MIELOPATIJE KAO POSLEDICE MULTISEGMENTOG DEGENERATIVNOG PROCESA

Luka Berilažić¹, Nebojša Stojanović^{1,2}, Radisav Mitić¹, Aleksandar Kostić^{1,2},
Ivan Cvetković¹, Zvonko Dželebdžić¹

¹Neurohirurška klinika, Klinički centar, Niš, Srbija
²Univerzitet u Nišu, Medicinski Fakultet, Niš, Srbija

Kontakt: Nebojša Stojanović
Neurohirurška klinika Niš, Klinički Centra Niš
Bul-Zorana Đinđića 48, 18000 Niš, Srbija
E-mail: nesamed59@gmail.com

Progresivna degenerativna oboljenja vratnog dela kičme su sve češći uzrok razvoja cervikalne mielopatije. Klinička slika je postepena sa dugovremenim razvojem.

Analizi je podvrgnuto 67 operisanih bolesnika sa polisegmentnim degenerativnim procesima u vratnom delu kičme, koji su imali kliničke i neurološke znake za cervikalnu mielopatiju. Na dva nivoa bila su operisana 33 bolesnika, 25 na tri nivoa i 9 na četiri nivoa. Bolesnici su operativno lečeni u periodu od 2010. do 2016. Svi bolesnici su tretirani prednjim multisegmentnim operativnim pristupom. Pre i post operativno praćena je mišićna snaga, kontrolni RTG vrata, a kontrolni IMR nakon 6 meseci.

Svi bolesnici su imali već ili manji oporavak uz zaustavljanje progresije neuroloških ispada. Kod 7 bolesnika zapaženi su neki vidovi problema sa gutanjem. Kod dva bolesnika je urađena revizija zbog upadanja titanijumskog grefona u korpuse i prednje destabilizacije. Ponovnoj operaciji podvrgnuta su tri bolesnika nakon godinu dana, sa proširenjem segmentog pristupa sa dva na tri i sa tri na četiri nivoa. Kod 13 bolesnika su registrovani problemi sa obimom rotacije vrata, ali to nije uticalo na njihove normalne životne aktivnosti. Nalaz praćenja motorne snage najugroženije grupe mišića, nakon 6 meseci, ukazuje na postizanje značajnog poboljšanja u odnosu na sve nivoe preoperativne motorne slabosti.

Polisegmentni vratni degenerativni procesi najčešće dovode do razvoja kifoze i gubitka normalne lordoze u vratnom delu kičme. Prisustvo hroničnog bolnog sindroma i razvoja neuroloških ispada u korelaciji sa NMR nalazom predstavljaju apsolutnu indikaciju za operativno lečenje. Prednjim operativnim pristupom se uklanjaju uzroci kompresije na neurovaskularne elemente, ali se pored toga vrši i korekcija visine intervertebralnih prostora i korekcija kifoze i izgubljene lordoze, što je u osnovi mehaničke stabilnosti kičmenog stuba, a samim tim i neurološke stabilnosti.

Acta Medica Medianae 2018;57(3):XX-XX.

Ključne reči: cervikalna mijelopatija, vratna disk hernijacija, predni pristup vratnoj kičmi