

VISOKO ESTETSKI BEZMETALNI KERAMIČKI RADOVI**HIGHLY AESTHETIC ALL-CERAMICS RESTAURATIONS***Danimir Jevremović¹, Sandro Pradella²*¹IVOCLAR-VIVADENT, BEOGRAD, SRBIJA I CRNA GORA, ²IVOCLAR-VIVADENT, MANTOVA, ITALIJA¹IVOCLAR-VIVADENT, BELGRADE, SERBIA AND MONTENEGRO, ²IVOCLAR-VIVADENT, MANTOVA, ITALY**Kratak sadržaj**

Keramika je materijal izbora za imitiranje prirodnih zuba. Bezmetalni keramički materijali nude estetske prednosti. Poslednjih godina, razvijen je novi sistem, u cilju postizanja najizazovnijih ciljeva u restorativnoj stomatologiji – jednostavnost upotrebe i vrhunska estetika zajedno sa adekvatnom jačinom i mehaničkom otpornošću. Ovaj članak prezentuje jedan od najpoznatijih i najpopularnijih bezmetalnih keramičkih materijala, IPS EMPRESS 2 sistem.

Ključne reči: estetika, bezmetalna keramika

Uvod

Zahtevi koje pacijenti postavljaju za estetskim izgledom naših radova, danas su veoma veliki. Materijali koji se koriste pri izradi bezmetalnih keramičkih nadoknada su posebno pogodni za postizanje vrhunskih estetskih rezultata. Jedan od, sigurno, najpoznatijih, najkorišćenijih i najpopularnijih bezmetalnih keramičkih sistema je IPS EMPRESS, firme IVOCLAR-VIVADENT iz Lihtenštajna. Ovaj sistem je u upotrebi već preko 13 godina.^{1,2} Tokom 1998., lansiran je novi produkt, IPS EMPRESS 2 sistem, i indikaciona zona proširena je na izradu tročlanih bezmetalnih mostova.^{3,4} Keramički materijali, koje koristi ovaj sistem, spadaju u grupu temperaturno-presovanih košuljičnih (core) i sinterovanih fasetirajućih (veneering) porcelana. IPS Eris for

Abstract

Ceramics have been advocated as the material of choice for matching the natural dentition. All-ceramic materials offer an esthetic advantage. In recent years, a new system has been developed, in an attempt to achieve the most challenging requirements in restorative dentistry-ease of fabrication and aesthetic coupled with adequate strength and fracture toughness. This article presents one of the best known and most popular all-ceramic materials, IPS EMPRESS 2 system.

Key words: aesthetic, all-ceramic restorations

Introduction

The requirements patients place on the aesthetic appearance of lab-fabricated restorations are very high today. All-ceramic materials are particularly suitable for the fabrication of high quality aesthetic restorations. One of the best known and most popular all-ceramic materials is IPS EMPRESS. The IPS EMPRESS System has been successfully used for over thirteen years.^{1,2} In 1998, the IPS EMPRESS 2 was introduced and the range of indications extended to include bridges.^{3,4} The all-ceramic material used for the system is both heat-pressed (core), and sintered (veneering porcelain). IPS Eris for E2, the fluoroapatite veneering ceramic, has been especially coordinated with the IPS EMPRESS 2 System.

E2, fluoroapatitna fasetirajuća keramika, posebno je dizajnirana za upotrebu sa IPS EMPRESS 2 sistemom.

IPS Eris for E2 pokazuje sledeće prednosti i osobine⁵:

- unapređena translucencija
- visok nivo svetline
- homogenija površina
- stabilnija veza između osnove i fasetirajućeg porcelana zahvaljujući finom podešavanju staklo-matriksa i nižoj temperaturi sinterovanja.

Cilj

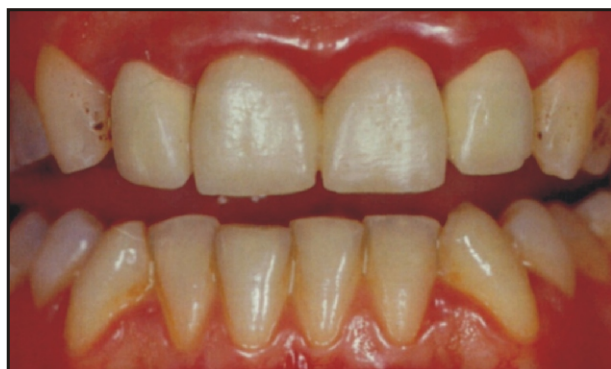Cilj ovog članka je da prikaže način rada i primenu IPS EMPRESS 2 sistema za postizanje vrhunskih estetskih i funkcionalnih rezultata.

Anamneza

U kliničkom primeru, koji predstavljamo u ovom članku, naša pacijentkinja, 27 godina stara, žali se na bol u predelu zuba 21 (Sl. 1). Radiografski snimak pokazuje apikalnu proliferaciju granulacionog tkiva. Dalja pretraga pokazuje da je postojeća nadoknada predimenzionirana, što je rezultiralo pojavom gingivitisa. Nakon dogovora sa pacijentkinjom, odlučili smo da zamenimo postojeću restauraciju.

Izrada bezmetalnih postova

Nakon uspešnog završetka endodontske terapije i potpunog smirenja svih znakova zapaljenja, pristupili smo preparaciji zuba za prihvatanje bezmetalnih keramičkih kruna (Sl. 2). Preparacija mora zadovoljiti principe otpo-



Slika 1. Izgled pacijenta na početku
Figure 1. Starting situation

IPS Eris for E2 presents the following advantages⁵:

- better translucency
- higher degree of brightness
- more homogeneous surface
- more stable bond between the framework and the veneering material due to better adjustment to the glass matrix and the lower firing temperature.

Objective

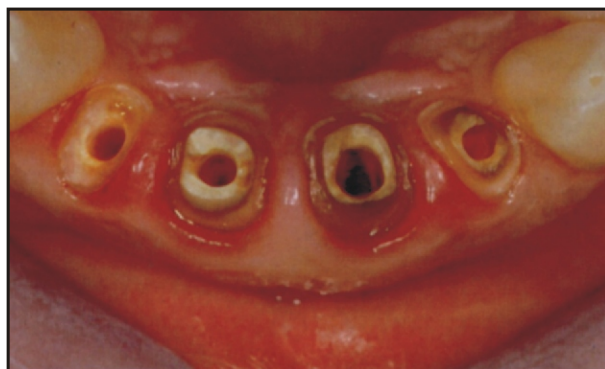The aim of this article is to show practical procedure and the use of IPS EMPRESS 2 system in achieving highly-demanding esthetic results.

Anamnesis

In the clinical case presented in this article, the 27-year-old female patient complained about pain in the region of tooth 21 (Fig. 1). The X-rays showed an apical proliferation of granulation tissue on this tooth. Further diagnostic procedures revealed that the existing restoration was designed too large, which had resulted in gingivitis. After having consulted with the patient, we decided to renew the existing construction in its entirety.

Fitting and cementing the root canal posts

After successful completion of the endodontic treatment, and once the gingiva has completely healed, the four tooth stumps are prepared to accommodate the prosthetic restoration (Fig. 2). The preparation should



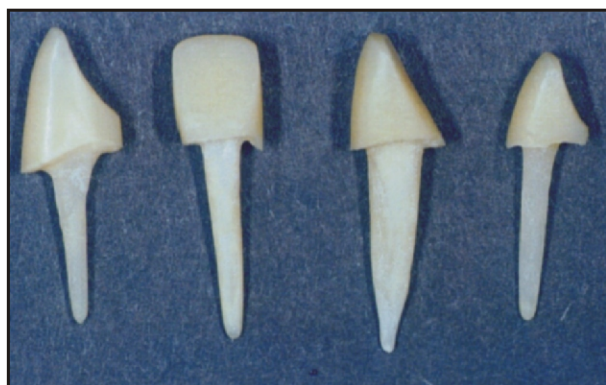Slika 2. Izgled preparisanih patrljaka
Figure 2. Occlusal view of the prepared tooth stumps

nosti, odnosno adekvatnu stabilnost tokom mastikacije, kao i odgovarajuću retenciju.⁶ Korenski kanali su preparisani upotrebom proširivača iz odgovarajućeg seta, nakon čega je uzet otisak kanala za indirektno modelovanje nadogradnje. Kanalni postovi su odabrani na osnovu veličine i promera odgovarajućeg kanalnog proširivača, postavljeni u otvore kanala na master-modelu, i skraćeni u koronarnom delu. Za krunični deo nadogradnje upotrebljena je laboratorijska metoda upotrebom novih kompozitnih materijala (VECTRIS i SR ADORO (Sl. 3). Premda se bezmetalni postovi mogu modelovati i direktnom metodom, u ordinaciji, laboratorijska metoda daje bolje i pouzdanije rezultate i treba je, po mogućstvu, koristiti pri izradi svih vrsta restauracija koje koriste bezmetalne, fiber-ojačane postove.

Gotovi bezmetalni postovi cementirani su adhezivnom tehnikom (Sl. 4). Krunična dužina posta proverava se upotrebom silikonskog ključa, napravljenog na osnovu probne modelacije izgleda i veličine kruna u vosku (Sl. 5). U ovom kontekstu, veoma je važno da krune imaju odgovarajuće, propisane dimenzije radi postizanja optimalnog estetskog efekta i stabilnosti.

Izrada IPS EMPRESS 2 košuljice

U cilju postizanja maksimalnog rubnog zaptivanja, patrjci su galvanizovani srebrom. Zahvaljujući probnom modelovanju u vosku, postignut je adekvatan međudnos košuljičnih i



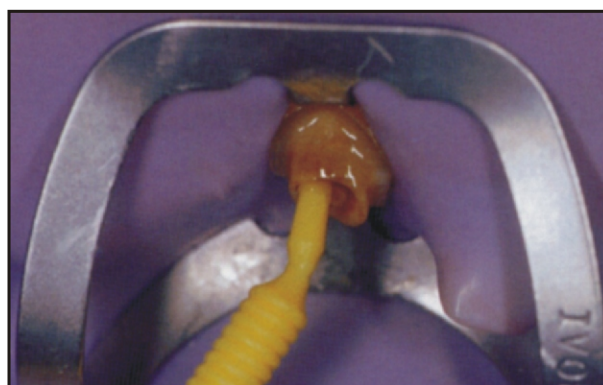
Slika 3. Završeni bezmetalni postovi, uz upotrebu kompozitnih materijala (Vectris i Sr Adoro)
Figure 3. Completed fiber-reinforced posts with post build-ups fabricated of composite (Vectris and Sr Adoro)

ensure adequate stability during mastication and reasonable crown retention.⁶ The root canal is prepared using the reamers from the set, afterwards impression was taken. The root canal posts are selected according to appropriate reamer size, fitted to the root canal openings in the master mode, and adjusted in length in the coronal area. The coronal part of the post build-up is supplemented using a composite material (VECTRIS and SR ADORO (Fig. 3). Though these posts can be made directly in the practice, indirect-lab method enables better and more confidential results, so, therefore, should be a choice when fabricating any kind of restoration, using fiber-reinforced posts.

The operator applies a small amount of composite on the root canal post, and then places it by the means of adhesive cementation (Fig. 4). The coronal length of the post is checked against the pre-rim of the wax-up (Fig. 5). In this context, it is particularly important for the overall aesthetic result that the crowns demonstrate equal thickness.

Fabrication of the IPS EMPRESS 2 copings

In order to ensure optimum accuracy of fit, the stumps are galvanized with silver. With the help of a wax-up, the actual spatial conditions are determined. The copings must be waxed-up



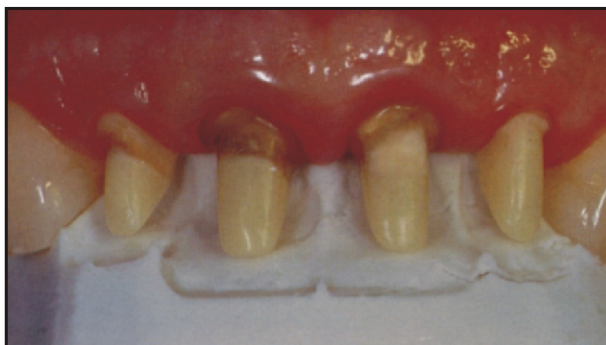Slika 4. Aplikacija vezujućeg sredstva za adhezivno cementiranje u kanal korena
Figure 4. Application of a bonding agent for the adhesive cementation of the root canal posts

fasetirajućih materijala. Keramičke košuljice se dobijaju upotrebom voštanih modela, moraju imati odgovarajuće dimenzije i naleganje im se može proveriti upotrebom stereomikroskopa (Sl. 6.). Zatim, voštani modeli košuljica (slično kao i u radu sa metal-keramikom) ulažu se i žare, a potom se kiveta ubacuje u peć za presovanje, EP 600 Comby (IVOCLAR-VIVADENT, Lihtenštajn), koja automatizovano izbacuje gotove keramičke košuljice. To su litijum-disilikatni keramički korovi, visoke transparentcije, otpornosti i hemijske stabilnosti.^{3,4} Upotreba ingot-košuljičnih materijala odgovarajućih boja je veoma bitna, jer ona ima značajnog uticaja na izgled završne nadoknade. S obzirom na veoma nepovoljnu boju dentinske osnove, za navedeni slučaj, odlučili smo se za upotrebu izbeljenih-Bleach ingota, koji se inače koriste pri izradi nadoknada na beljenim zubima. Košuljice su zatim postavljene na master-model (Sl. 7). Nakon provere na modelu, košuljice su probane in-situ (Sl. 8).

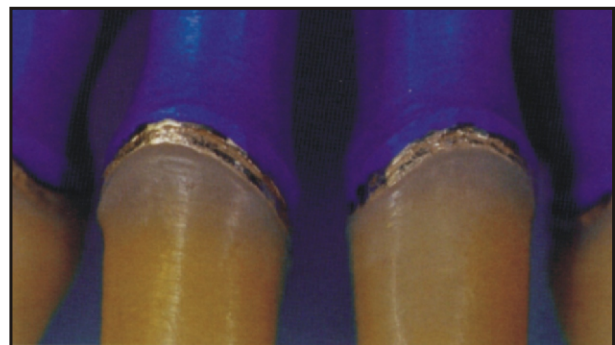with uniform wall thicknesses and the marginal seal can be checked with the help of a stereomicroscope (Fig. 6). Now, the wax copings are sprued and invested according to the instructions of the manufacturer and pressed in the EP600 Comby furnace. The correct shade selection of the ingots is very important, since the shading of the copings decisively influences the brightness value of the subsequent restoration. For the present clinical situation, bearing in mind dentin shade, we decided to use Bleach ingots. The pressed copings are then fitted to the master model (Fig. 7). After that, the copings are tried-in in situ (Fig. 8).

Veneering the copings using IPS Eris for E2

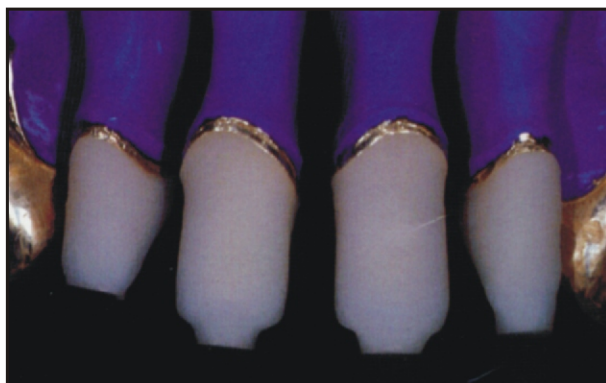The crown shapes are layered using the IPS Eris for E2 veneering ceramics.³ The shade



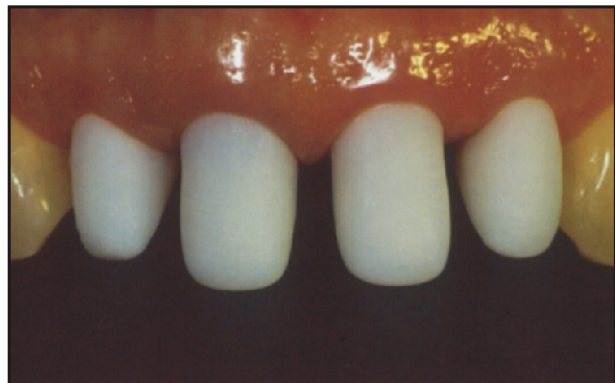Slika 5. Izgled kanalnih postova nakon cementiranja. Dimenzije se proveravaju prema postojećem silikonskom ključu
 Figure 5. The root canal posts after cementation. The dimensions of the build-up are checked with the help of the pre-rim.



Slika 6. Pogled izbliza na marginalu adaptaciju
 Figure 6. Close-up of the marginal seal



Slika 7. Presovane košuljice IPS Empress 2 na modelu
 Figure 7. Fitted IPS Empress 2 copings



Slika 8. Proba košuljice u ordinaciji
 Figure 8. Try-in of the copings

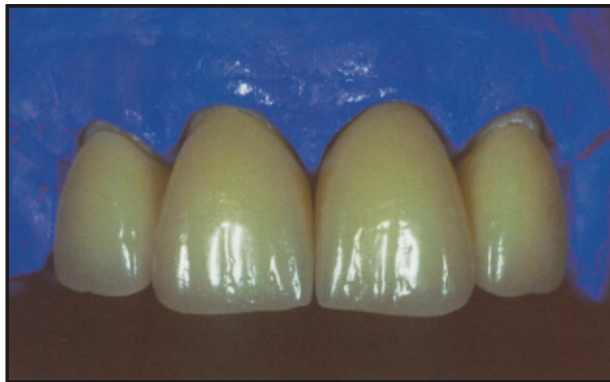Upotreba IPS Eris for E2 porcelana za postizanje vrhunskih estetskih efekata

Keramičke košuljice su potom fasetirane upotrebom IPS Eris for E2 fluoroapatitne keramike³. Zasićenje boje se može povećati još u wash-pečenju, upotrebom mešavine Dentin i individualnih-Impulse materijala. Konačno, oblik zuba je postignut upotrebom naizmeničnih slojeva Transparent, Dentin i Incizal materijala.

Nakon uobičajene korekcije u ustima, krune su glazirane, očišćene, nagrižene i, kao takve, spremne su za cementiranje (Sl. 9).

Cementiranje bezmetalnih keramičkih nadoknada

Cementiranje je veoma važan korak. Preporučuje se upotreba koferdama kada se koriste novi, adhezivni cementi poslednje generacije (Variolink II, IVOCLAR-VIVADENT, Schaan, Liechtenstein (Sl. 10).



Slika 9. Gotove krune na modelu
Figure 9. Completed crowns on the model

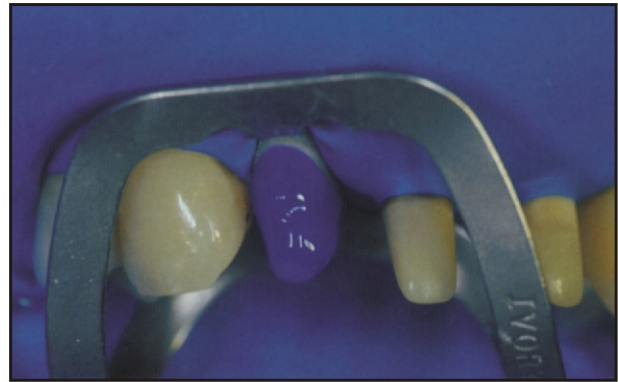
Nakon nekih šest meseci, proverili smo estetski rezultat, kao i stanje mekih tkiva. Pozitivan odgovor gingive na restauraciju neophodan je faktor ukupnog uspeha tretmana (Sl. 11). Estetski efekti mogu se objasniti, između ostalog, činjenicom da kombinacija IPS EMPRESS 2-IPS Eris for E2 imitira prirodnu kombinaciju opaciteta, i translucencije. Primer

saturation of the restoration can be increased as early as in the wash firing, from the inside out so to speak, by using a mixture of Dentin and Impulse materials. If necessary, the shade can be further intensified by means of Stains and Shades in the following dentin firing. Finally, the tooth shape is completed by alternately layering Transparent, Dentin, and Incisal materials.

After the usual functional checks, glaze firing is conducted. Finally, the crowns are polished, cleaned, etched, and handed over to the dental office (Fig. 9).

Adhesive cementation procedure

Cementation is a very important step. We recommend using a rubber dam when performing adhesive cementation (Variolink II, IVOCLAR-VIVADENT, Schaan, Liechtenstein (Fig. 10).

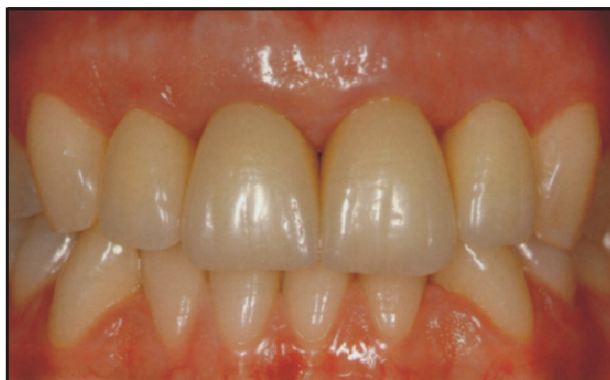

Slika 10. Nagrizanje patrljaka (preostale zubne supstance) za adhezivno cementiranje IPS Empress 2-IPS Eris for E2 krune

Figure 10. Etching of the stump (residual tooth structure) for the adhesive cementation of the IPS Empress 2-IPS Eris for E2 crowns

After approximately six months, we recheck the aesthetic appearance, as well as the periodontal results. The reaction of the marginal soft tissue is decisive for the overall success of the restoration (Fig. 11). The aesthetically appealing result can be attributed, among other things, to the fact that the IPS EMPRESS 2-IPS Eris for E2 System imitates the natural relationship of opacity and

pokazuje i kako se "crni međuprostori" efikasno mogu zatvoriti nakon smirenja inflamacije gingivalnih papila⁷ (Sl.12).

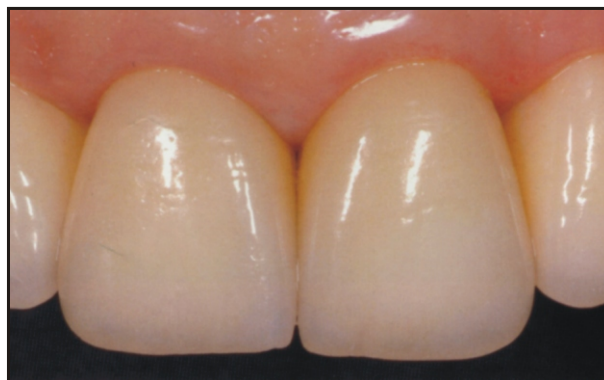

Slika 11. Izgled gotove restauracije
Figure 11. Completed crowns

Zaključak

Ovaj članak opisuje osnovne praktične principe izrade visoko estetskih dentalnih restauracija korišćenjem litijum-baziranih bezmetalnih sistema. Možemo zaključiti da su uvođenjem IPS EMPRESS 2 sistema, stomatolozi i zubni tehničari dobili jednostavan i pouzdan način, da osmeh učine širim i lepšim.

translucency in a convincing fashion. Even the dreaded "black holes" have largely closed since the inflamed gingiva has healed⁷ (Fig.12).



Slika 12. Pogled izbliza na krune nakon šest meseci
Figure 12. Detailed picture of the crowns taken during recall after six months

Conclusion

This article showed basic practical tips for fabricating highly-esthetic dental restorations using lithia-based metal-free systems. We can conclude, with the introduction of IPS EMPRESS 2 system, dentists and dental technicians found an easy and confident way to make a smile wider and nicer.

LITERATURA / REFERENCES

1. IVOCLAR-VIVADENT, Report No. 12, Decembar 1998, Schaan, Liechtenstein.
2. IPS Empress 2 System-the Original, Scientific Documentation, Ivoclar-Vivadent, Schaan, Liechtenstein
3. IPS Eris for E2 System, Scientific Documentation, Ivoclar-Vivadent, Schaan, Liechtenstein.
4. Dr Danimir Jevremović, Dr Petar Jevremović: Bezmetalna keramika, Mozaik medici. com - Medicinske komunikacije, Mart 2004.
5. IPS Empress 2 System, Instruction for Use, Ivoclar-Vivadent, Schaan, Liechtenstein.
6. Heintze, SD: Brücke aus vollkeramischem Material (IPS Empress 2) Indikation, klinische Aspekte und Prognosen. In: Report No. 12, 1998.
7. Holand, W. Werkstoffwissenschaftliche Aspekte der IPS Empress 2 Glaskeramik, in: Report. No.12, 1998.

Adresa za korespondenciju / Address for correspondence:

Dr Danimir Jevremović
Šajkaška 27/VII
11000 Beograd
Srbija i Crna Gora
e-mail: dr_danimir@yahoo.com