NAUČNI RAD
SCIENTIFIC ARTICLE

PLAZMA ĆELIJE I RUSSELLOVA TELAŠCA ZUBNOG GRANULOMA (ELEKTRONMIKROSKOPSKO ISPITIVANJE)

PLASMA CELLS AND RUSSELL BODIES OF DENTAL GRANULOMA (ELECTRON-MICROSCOPIC STUDY)

Goran Radičević[1], Jovanka Gašić[1], Aleksandar Petrović [2]

[1]UNIVERZITET U NIŠU MEDICINSKI FAKULTET, KLINIKA ZA STOMATOLOGIJU, ODELJENJE ZA BOLESTI ZUBA
[2]INSTITUT ZA HISTOLOGIJU I EMBRIOLOGIJU, NIŠ, SRBIJA, SRBIJA I CRNA GORA

[1]UNIVERSITY OF NIS, MEDICAL FACULTY
DENTAL CLINICS, DEPARTMENT OF DENTAL PATHOLOGY, [2] HISTOLOGY AND EMBRYOLOGY INSTITUTE, NIŠ, SERBIA, SERBIA AND MONTENEGRO

Kratak sadržaj

Na 20 uzoraka zubnih granuloma koji uglavnom potiču sa gornjih lateralnih sekutića, od pacijenata oba pola, starosti od 16 do 60 godina, urađena su ultrastrukturna istraživanja sa ciljem da se detaljnije prouči građa plazma ćelija (PC) i njihov odnos sa Russellovim telašcima (Rt). Naročita pačnja je usmerena na mesto stvaranja i lokalizaciju Rt, kao i na prelazne oblike koji postoje u njihovom "sazrevanju". Materijal je podvrgnut standardnoj tehnici obrade, a ultratanki preseci, debljine 40-60 nm, pripremljeni su na ultramikrotomu NOVA-LKB sa staklenim noževima. Kontrastiranje je izvršeno u kompjuterizovanom aparatu ULTRO-STEINER-LKB sa uranil acetatom i olovnim nitratom. Transmisiona EM urađena je na elektronskom mikroskopu BS-500. Na dobijenim preparatima i elektronmikrografijama, zapaženo je stalno prisustvo PC koje dominiraju zapaljenjem. Ove ćelije uglavnom pokazuju sličnu građu, ali je zapažen veliki broj varijacija u odnosu na organizaciju granuliranog endoplazmatskog retikuluma (gER), prisustvo ribozoma i nukleolusa, kao i na stanje jedarnog hromatina i eventualno prisustvo Rt. Utvrđeno je da se PC mogu videti u četiri morfološka tipa-oblika. Na osnovu tih oblika moguće je pratiti način stvaranja Rt. Prisustvo Rt utvrđeno je samo u jednom tipu PC i to unutar dilatovanih cisterni gER-a. Ove strukture se pokazuju kao sferična telašca različite veličine i umerene ali kompaktne i jednake elektronske gustine. Utvrđeno prisustvo četiri oblika PC ukazuje na veliki dinamizam tih ćelija, pri čemu prisutni oblici predstavljaju moguće razvojne faze Rt.

Ključne reči: *zubni granulom, plazma ćelije, Russellova telašca*

Abstract

Ultra-structural studies were made on 20 samples of dental granulomas, most frequently originating from upper lateral incisors of both male and female patients from 16 to 60 years old, aimed at a more detailed study of plasma cells (plasma cells – PCs) structure and their relation to Russell bodies (Rb). Particular attention was paid to the point of Rb generation and localization as well as to the transitional forms that exist in their "getting mature". The material was subject to the standard treatment technique and ultra-thin sections, 40 – 60 nm thick were prepared on ultra-microtome NOVA-LKB with glass cutters. Contrasting was done in a computerized apparatus ULTRO-STEINER-LKB by means of uranil-acetate and lead nitrate. Transmission EM (electronic microscopy) was performed on electronic microscope BS-500. On obtained preparations and electron-micrographs, there was noted constant presence of PCs that dominate the inflammation. These cells generally exhibit the same structure, but a great number of variations has been noted compared to the organization of the granulated endoplasmic reticulum (gER), presence of ribosome and nucleoli, as well as the state of nucleus chromatin and eventual presence of Rb. It was established that PCs may be seen in four morphological types – forms. Based on these forms it is possible to follow the manner of Rb generation. The presence of Rb was found in one PC type only, that is, inside dilated cisterns of granulated endoplasmatic reticulum (gER). These structures are shown as spherical bodies of various sizes and moderate but compact and equal electronic density. The established presence of four PC shapes indicates extraordinary dynamism of these cells, in that, the present shapes represent the possible Rb development phases.

Key words*: dental granuloma, plasma cells, Russell's bodies*

Uvod

Dosadašnja istraživanja idu u prilog tezi da kod zubnog granuloma humoralni i celularni

Introduction

Up-to-date researches contribute to the thesis that in dental granuloma, humoral and cellu-

imunitet učestvuju u zapaljenjskim reakcijama[1,2]. U ćelijskom sastavu zubnog granuloma vidno mesto zauzimaju plazma ćelije (PC). Ove ćelije su imunoglobulin pozitivne sa multiplom sekrecijom: IgG, IgA i IgM.[1,3,4] Biološki mehanizmi sinteze imunoglobulina u PC zubnog granuloma čoveka nisu u potpunosti razjašnjeni. Opšte je prihvaćeno da se ove ćelije smatraju producentima Russellovih telašaca (Rt), koja se uvek nalaze u PC (ili neposredno uz njih) kod različitih infekcija hroničnog tipa (nespecifični granulomi[5,6], rinosklerom[7], papilarni konjuktivitis[8]). Takođe, ove strukture su primećene kod poremećaja serumskih proteina (makroglobulinemija, paraproteinemije[9,10,11]) u normalnoj crevnoj sluzokoži[12], kao i u hroničnim ćelijskim infiltratima udruženim sa malignim tumorima, plazmocitomima i ostalim plazmaćelijskim neoplazmama.[13,14,15] Kod pacijenata sa primarnom i sekundarnom amiloidozom, Rt su otkrivena u kostnoj srži.[16] Prema podacima iz literature, Rt se u zubnom granulomu pojavljuju u 80-86%[5,6] ili čak 99% posmatranih uzoraka.[17]

Rt nisu patognomonična ni za jedno oboljenje, odnosno "ne postoji nijedna bolest ili patološko stanje u kome bi se Rt isključivo javljala".[18] S druge strane, ova telašca po Mortonu (1977) predstavljaju "kardinalan nalaz hroničnih periapikalnih lezija", ali njihovo pravo značenje nije utvrđeno.[19] Postoji mišljenje da su PC sa intracelularnim Rt patološko stanje (Mottove ćelije) i da se sreću u autoimunim bolestima.[20] Tazawa (1998), Rt smatra intracelularnim inkluzijama imunoglobulina koja nastaju aktivacijom i diferencijacijom aberantnih B1 ćelija procesom (aberantne) mutacije, pri čemu Mott-ove ćelije nisu efektori za autoimunu bolest.[21] Valetti i sar. (1991) u opsežnoj studiji o Rt, pretpostavljaju da su ona proteinske prirode (H i L lanci) i da predstavljaju opšti ćelijski odgovor na nagomilavanje obilnih nerazgradljivih proteina koji ne uspevaju da izađu iz gER-a.[22]

Korišćenjem imunocitohemijskog bojenja, primenom PAP tehnike, u našim prethodnim istraživanjima nije pokazano prisustvo imunoglobulinskih molekula u centru ili na periferiji Rt. Međutim, pozitivna reakcija i centra i periferije dobijena je u reakciji sa antitelima na Ig-kappa lake lance, dok se pozitivna periferna reakcija na neka druga monoklonska antitela mogla tumačiti i kao reakcija sastojaka membrane gER-a.[1]

lar immunity participate in inflammatory reactions. [1,2] In the cellular structure of a human dental granuloma plasma cells (PC) take a prominent place. These cells are immunoglobulin-positive, with multiple secretion: IgG, IgA, IgM.[1,3,4] Biological mechanisms of immunoglobulin synthesis in dental granuloma plasma cells have not been completely clarified. It is generally accepted that these cells are considered the producers of Russell bodies (Rb), which are always found in PCs (or very close to these) in various chronic infections (non-specific granulomas[5,6], rhino-scleroma[7], papillary conjunctivitis[8]). These structures have also been noticed in serum proteins disturbances (macroglobulinemia, paraproteinemia[9,10,11]) in normal intestinal mucous membrane[12] , as well as in chronic cellular infiltrates, jointly with malign tumors, plasmocytomes and other plasma cells neoplasm. [13, 14, 15] In patients with primary and secondary amiloidose, Rb were discovered in bone marrow.[16] According to data found in literature, Russell bodies, in dental granuloma appear in 80–86% [5,6] or even in 99% of the observed samples.[17]

Russell bodies are not pathognomonic for any kind of disease, that is, "there is not a single disease or pathological state in which Rb would exclusively occur."[18] On the other hand, according to Morton (1977), these bodies represent "cardinal finding of chronic periapical lesions", although their actual meaning has not been established.[19] It is thought that plasma cells with intracellular Russell bodies represent a pathological state (Mott cells) and that these may be encountered in auto-immune diseases.[20] Tazawa (1998) consider Russell bodies as intracellular inclusions of immunoglobulin, generated by activation and differentiation of aberrant B_1 cells by means of (aberrant) mutation process and that Mott's cells are not the effectors for autoimmune disease.[21] Valetti et all (1991) in a comprehensive study of Russell bodies, presume that these are of protein nature (H and L chains), representing general cellular response to accumulation of abundant dissoluble proteins not able to leave gER.[22]

By using immuno-hystochemical staining (PAP technique) in our previous researches, we found that there was no presence of immunoglobulin molecules in Rb center or periphery. However, the positive reaction (both of the centre and periphery) was the reaction of antibodies to Ig-kappa light chains, while the positive marginal reaction to some other monoclonal antibodies could be interpreted as the reaction of gER membrane components.[1]

Cilj ispitivanja

Ovo ispitivanje je preduzeto sa ciljem elektronomikroskopske procene prisutva PC u tkivu zubnog granuloma, njihovih karakteristika i različitosti, kao i procesa nastajanja Rt, tj. određivanja mesta njihovog stvaranja i "faznog razvoja".

Materijal i metode

Materijal

Materijal za istraživanje sačinjavalo je 20 zubnih granuloma, pacijenata starosti od 16 do 60 godina; 12 pacijenata bilo je ženskog, a 8 muškog pola. Materijal potiče sa 20 zuba gornje i donje vilice, najčešće sa gornjih lateralnih sekutića (11 uzoraka). Svi pacijenti su bili u klinički dobrom opštem zdravstvenom stanju. Granulomi su dobijani ili operativnim putem ili ekstrakcijom zuba na Odeljenju za oralnu hirurgiju Klinike za stomatologiju u Nišu. Granulomi su skalpelom pažljivo odvajani od korena zuba, odmah stavljani u 10% puferizovani neutralni formalin gde su ostajali najduže do 48 časova, ili stavljani u tečni azot gde su trenutno zamrzavani i čuvani u komori za duboko zamrzavanje na -60°C.

Metode

Od svakog granuloma je urađeno po nekoliko serijskih preseka debljine 4 – 6 μm radi globalne histološke verifikacije, pri čemu su daljoj obradi podvrgavani samo granulomi, dok su uzorci cisti odmah eliminisani. Za elekronmikroskopska proučavanja sečeni su uzorci debljine oko 1mm^3 i podvrgavani dvostrukoj fiksaciji (puferisani 3% glutaraldehid na +4°C, 4 – 6 časova i 1% osmijumska kiselina na sobnoj temperaturi, 2 – 3 časa), a zatim ugrađivani u epon 812 sa polimerizacijom na 60°C. Od eponskih kalupa uzimani su polutanki preseci debljine 0,5-1 μm i bojeni baznim fuksinom i metilenskim plavilom. Ovi preseci su korišćeni za podrobniju histološku analizu granuloma i za odabiranja područja sa kojih će se uraditi ultratanki preseci. Ovi preseci, debljine 40 – 60 nm, napravljeni su na ultramikrotomu NOVA-LKB (Švedska), a kontrastirani u kompjuterizovanom aparatu ULTRO-STEINER-LKB sa uranil

The aims of research

This study was aimed at electro-microscopic estimating of the presence of plasma cells in a dental granuloma tissue, their characteristics and diversities as well as Russell bodies generation processes, that is, determination of their generation position and "phase development".

Material and methods

Material

The study material comprised 20 dental granulomas of patients, 16 to 60 years old; 12 patients were females and 8 males. Material source is from 20 upper and lower jaw teeth, most frequently from upper lateral incisors (11 samples). All patients were in generally good clinical health condition. Granulomas were obtained either surgically or by teeth extraction at Dental Clinic of Nis – Oral Surgery Department. Granulomas were carefully separated from the tooth root by scalpel, immediately placed in 10% buffered neutral Formalin, kept there for 48 hours at most, or disposed in liquid nitrogen, frozen immediately and kept in deep freezing chamber at the temperature of -60°C.

Methods

Out of each granuloma, there were several 4 – 6 micrometers thick serial sections made for the purpose of global histological verification, in that only granulomas were subject to further processing while the cysts samples were immediately eliminated. For electronic microscopy study approximately 1 mm^3 thick samples were cut and then these were subject to double fixation (buffered 3% glutaraldehide at +4°C, 4 – 6 hours and 1% osmium acid at the room temperature, 2 – 3 hours), and then incorporated in Epon 812 with polymerization at 60°C. Out of Epon moulds there were taken semi-thin sections, 0.5 – 1.0 micrometers thickness and stained by base fuxine and methylene blue. These sections were used for more detailed histological analysis of granulomas and for selecting the area to be used for ultra-thin sections making. These sections 40 – 60 nanometers thick have been made on ultra-microtome NOVA-LKB (Sweden) and they have been contrasted in the computerized apparatus ULTRO-STEINER-LKB by means of ura-

acetatom i olovnim nitratom. Transmisiona EM vršena je na elektronskom mikroskopu BS-500, Tesla, Čehoslovačka.

Rezultati

Plazma ćelije, koje u osnovi imaju sličnu globalnu ultrastrukturu, u ovom istaživanju su pokazivale velike varijacije u odnosu na organizaciju gER-a, prisustvo lizozoma, prisustvo nukleolusa, stanje jedarnog hromatina i, najzad, u odnosu na prisustvo Raselovih telašaca. Plazmociti su se retko pojavljivali kao solitarni, uglavnom su bili zgomilani (shodno klonalnoj teoriji o udruživanju radi produkcije imunoglobulina). Na osnovu tih svojstava, izdvojene su 4 varijante plazmocita:

1. Najčešći tip plazmocita je poligonalnog oblika, sa lako ekscentrično postavljenim jedrom. Jedro je ovalno i sa tipičnom perifernom distribucijom grubih heterohromatinskih grudvi koje klinasto zalaze prema središtu u euhromatin. Jukstanuklearno, na strani veće citoplazmatske mase, nalazi se svetla zona dobro razvijenog Golgi aparata. U ostalom delu citoplazme dominira gER, raspoređen u vidu polulučnih i koncentričnih membrana sa nizom ribozoma na njihovoj spoljašnjoj površini. U citoplazmi se nalazi homogeni materijal niske elektronske gustine, retke mikrovezikule, retka tamna lizozomalna telašca i mnogobrojne mitohondrije (Sl. 1 i 2).

nil-acetate and lead nitrate. Transmission EM has been made on electronic microscope BS-500, Tesla, Czechoslovakia.

Results

In this study, plasma cells, of basically similar global ultra-structure, have shown great variations compared to gER organization, lysosomes presence, nucleoli presence as well as to the states of nucleus chromatin and finally, compared to the presence of Russell bodies. Plasma cells rarely appeared as solitary, they were mainly accumulated, (according to clone theory about joining for the purpose of immunoglobulin production). Based on these characteristics there were singled out four variants of plasma cells:

1. Most frequent plasma cell type has got a polygonal shape, the nucleus of which is positioned slightly eccentric. The nucleus is oval, with typical peripheral distribution of rough heterochromatin clods; these penetrate wedge-shaped toward the centre into euchromatin. Juxta-nucleary, on the side of greater cyto-plasmatic mass, there is a clear zone of well developed Golgi apparatus. In the rest of cytoplasm, gER dominates, arranged in thee shape of semi-arch and concentric membranes with a series of ribosomes on their outer surface. In the cytoplasm there is there is homogeneous material of law electronic density, rare micro-vesicles, rare dark lysosomal bodies and numerous mitochondria (Figs. 1 and 2).

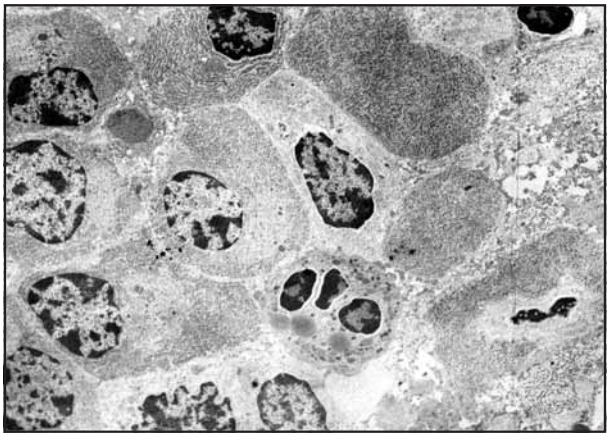

Slika 1. Grupa plazmocita sa tipičnim citoplazmatskim i jedarnim karakteristikama. Zapaža se upadljivi Goldži aparat i citoplazma bogata gER-om. 2000x.
Figure 1. Group of plasma cells of typical cytoplasmatic and nuclear characteristics. Conspicuous Golgy apparatus and cytoplasm rich in gER are observed. 2000x

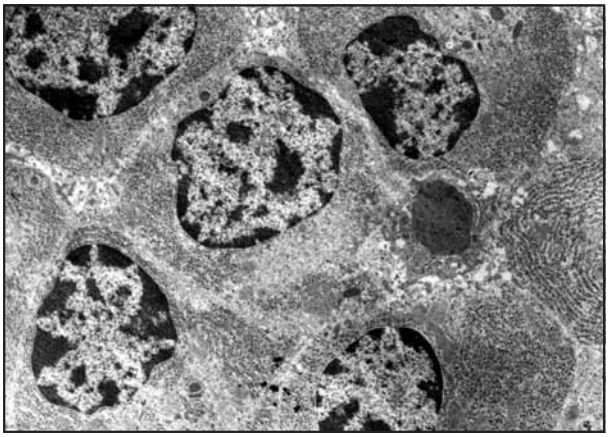

Slika 2. Plazmociti sa naizmeničnim eu- i heterohromatinom u jedru, retkim mitohondrijama i zgusnutim paralelnim cisternama gER-a. 10400x.
Figure 2. Plasma cells of alternate euchromatin and heterochromatin within the nucleus, rare mitochondria and dense parallel gER cisterns. 10400x.

2. Druga varijanta plazmocita poseduje manju količinu heterohromatina, obilje euhromatina, ekscentrični nukleolus i veliki broj nukleusnih pora. U citoplazmi, gER je nešto oskudniji, a u njegovim cisternama pojavljuju se okrugla telašca veće elektronske gustine. Goldži zona je umereno izražena, a primarni i sekundarni lizozomi su izuzetno retki. Moguće je da ovi oblici ćelija imaju deobnu sposobnost i da spadaju u proplazmocite (Sl. 3).

3. Među plazmocitima uobičajenih karakteristika, pojavljuju se i ćelije relativno "svetlijih jedara" sa mnogobrojnim umereno dilatovanim cisternama gER-a unutar kojih je više loptastih struktura bez membrane sa većom elektronskom gustinom (Sl. 4). U lumenima cisterni gER-a, koji pokazuju nejednaku širinu, prisutna su tamna kružna telašca jake osmiofilnosti. U drugim cisternama, zapaža se fibrilarni i pahuljičasti sadržaj, najvećim delom odvojen od membrane gER-a svetlom zonom nejednake širine, koji formira "corona like" zonu (sl. 5).

4. Pojedine plazma ćelije, pored standardnih karakteristika, ispunjene su naglašeno prisutnim gER-om, čije su cisterne najvećim delom paralelne, pretežno dilatovane, sa kontinuiranim ribozomalnim slojem na spoljašnjoj površini membrana. Unutar cisterni nalazi se grub pahuljičasti sadržaj nejednake elektronske

2. Other plasma cells variant posses lower hetero-chromatin quantity, huge amount of euchromatin, eccentric nucleolus and numerous nuclear pores. In cytoplasm, gER is somewhat lower, and in their cistern, there is the occurrence of round bodies of higher electronic densities. The Golgy zone is moderately expressed, and primary and secondary lysosomes are extremely rare. It is possible that these cell forms have the capacity of division and that they belong to pro-plasma cells (Figure 3).

3. Among the plasma cells of customary characteristics, there is the occurrence of relatively "clearer" nucleus cells and numerous moderately dilated gER cisterns, containing more ball-like structures, without a membrane and higher electronic density (Fig. 4) Within the lumens of gER cisterns, which show unequal width, there are dark round bodies present, of strong osmiofility. In other cisterns, there may be noted fibrilar and flake-like contents detached in most of its part from gER membrane by a clear zone of unequal width, which forms "corona like" zone (Figure 5).

4. Certain plasma cells, apart from standard characteristics, are filled with markedly present gER, the cisterns of which are in most part parallel, mostly dilated, of continual ribosomal layer on outer membrane surface. Inside the cisterns there is rough flake-like contents of un-

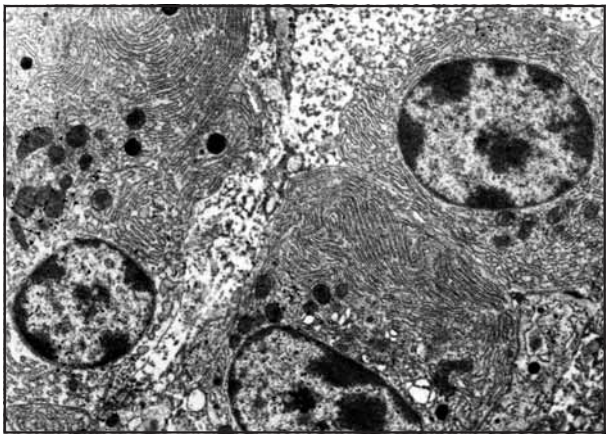

Slika 3. Plazmociti naglašenog gER-a, umereno razvijenog Goldži aparata i mitohondrija, sa retkim tamnim telašcima unutar gER-a. 8000x.

Figura 3. Plasma cells of conspicuous gER, of moderately developed Golgy apparatus and mitochondria and rare dark bodies within gER, 8000x

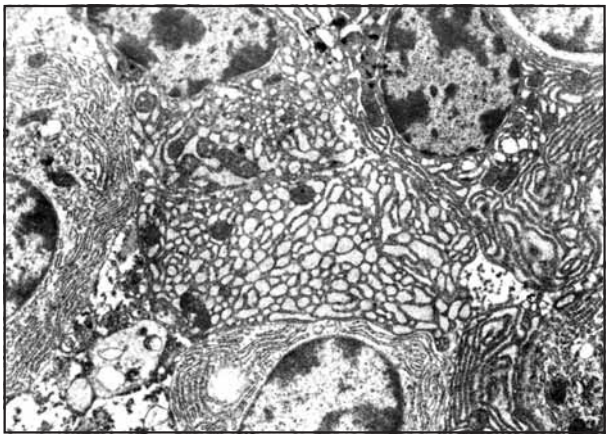

Slika 4. Plazmociti sa svetlijim jedrima, malim brojem mitohondrija i obilnom citoplazmom bogatom gER-om, čije su neke cisterne jako dilatovane i mestimično ispunjene paučinastim i elektron gustim sadržajem. 8000x.
Figure 4. Plasma cells with lighter nuclei, small number of mitochondria and ordinary gER- rich cytoplasm, some cisterns of which are highly dilated, partly filled with cobweb-like contents and electron dense contents. 8000x.

gustine i slojevitog rasporeda (Sl. 6). To su "inclusio-like" formacije promenljive veličine. Kod ovih tipova plazmocita, u dilatovanim cisternama gER-a, mogu se videti loptasta homogena telašca, umerene, ali kompaktne i jednake elektronske gustine. Ove strukture odgovaraju strukturi Russellovih telašaca (Sl. 7). Kao i kod svih prethodnih "inkluzionih" struktura, tako i kod Russellovih telašaca, u najvećem delu njihove cirkumference, postoji svetli halo koji ih odvaja od membrana gER-a (Sl. 6 i 8).

equal electronic density and distribution layers (Fig. 6). These are "inclusion-like" formations of variable size. In these types of plasma cells, in dilated gER cisterns there may be seen ball-like homogeneous bodies of moderate but compact and equal electronic density – these correspond to the Russell's bodies structure (Fig. 7). Like in all previous "inclusion" structures, in Russell's bodies, as well, in the greatest part of their circumference, there is a clear halo that detaches them from gER membranes (Figs. 6 and 8).

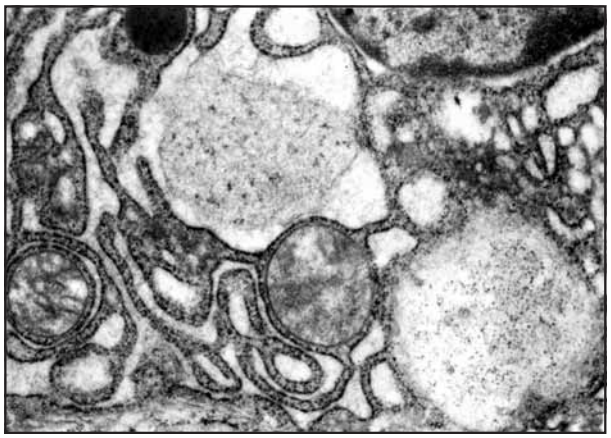

Slika 5. Jedro plazmocita je relativno euhromatično (gore desno) a cisterne gERa su jako dilatovane sa telašcima jake elektronske gustine i pahuljičastim sadržajem, omeđena svetlim haloom od membrane cisterni. 28000x.
Figure 5. Plasma cell nucleus is relatively euro-chromatic (top right) and gER cisterns are highly dilated with bodies of strong electronic density and flake-like contents, marked with light halo from cistern membranes. 28000x.

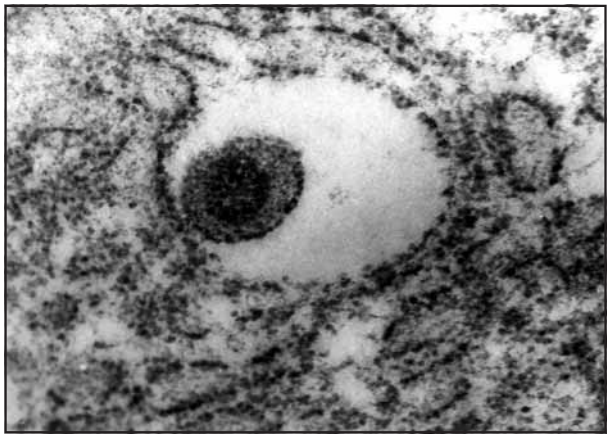

Slika 6. Više dilatovanih cisterni gER-a, od kojih je jedna izrazito proširena sa amembranskom "inkluzijom", sa koncentrično raspoređenim sadržajem nejednake elektronske gustine, okružena širokim svetlim haloom. 114000x.
Figure 6. Numerous dilated gER cisterns, one of which is extremely enlarged with a-membrane "inclusion" with concentrically distributed contents of unequal electronic density, surrounded by wide light halo. 114000x.

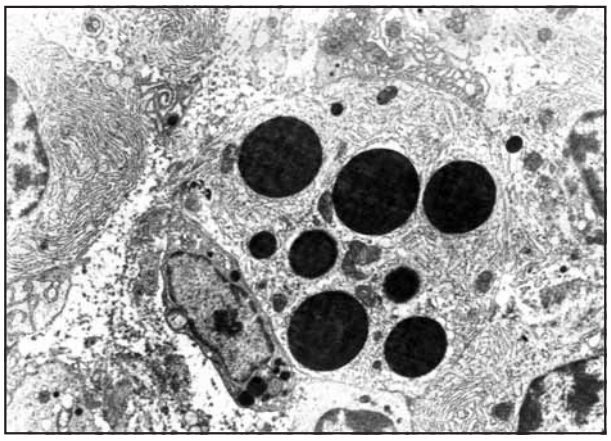

Slika 7. Mikrografija prikazuje nejednako dilatovane cisterne gER-a ispunjene homogenim elektron gustim Russell-ovim telašcima, okruženim svetlim haloom prema zidu cisterne. 8000x.
Figure 7. Micrograph shows unequally dilated gER cisterns filled with homogeneous electron dense Russell bodies, surrounded by light halo towards the cistern wall. 8000x.

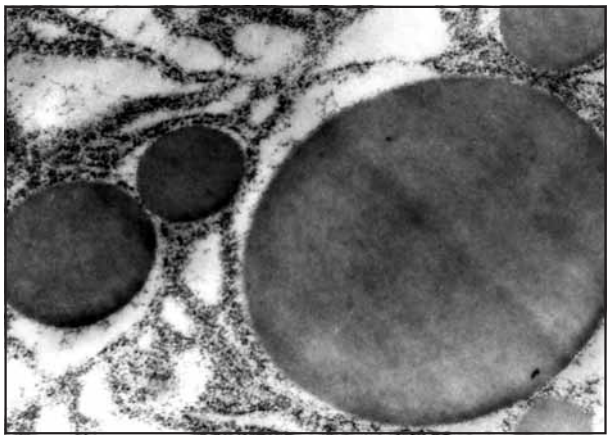

Slika 8. Detalj sa prethodne slike koji pokazuje više Rt, gotovo kružnog oblika i homogene građe, koji mestimično kontaktiraju sa unutrašnjim zidom gER-a. 46800x.
Figure 8. Detail of the previous figure, showing numerous Rbs of almost round shape and homogeneous structure which partially contacts the gER internal wall. 46800x.

Diskusija

Nesumljivo je visokoprocentno prisustvo PC u zubnom granulomu čoveka (do 80 % ćelijskog sadržaja) kao odgovor na iritativne stimuluse izazvane bakterijama i njihovim toksinima, kao i mnogobrojnim produktima dekompozicije tkiva prisutnim u nekrotičnoj ili gangrenski raspadnutoj pulpi. Stereometrijska ispitivanja u prethodnoj studiji, utvrdila su da od ukupne zapremine granuloma na PC otpada 2,68%.[1] Takođe, PC imaju najveću numeričku (N_V) i najveću površinsku gustinu (S_V) od svih ćelija u granulomu, što govori o njihovoj izuzetnoj funkcionalnoj aktivnosti.[1] Aktivnost PC u smislu sinteze imunoglobulina otkrivena je još 1948, od kada je postala predmet intenzivnog proučavanja. Fisher i Zbigniew (1970) opisuju "normalne" PC[10], a Toppozada i saradnici (1981) "reaktivne"PC.[7] Naša ispitivanja su potvrdila veliku funkcionalnu aktivnost PC koji se javljaju u četiri morfološka tipa-oblika. Drugi autori, baveći se problemom paraproteinemije i plazmaćelijskog mijeloma, na osnovu izgleda gER-a, elekronomikroskopski opisuju šest tipova.[10,13]

Prema podacima iz literature, ultrastukturne studije pokazuju da citoplazma PC sadrži obilje vezanih i malu količinu slobodnih ribozoma, što je u korelaciji sa njihovom funkcijom.[12,23] Sem paranukleusne regije, gde se nalazi Goldži aparat, ostali deo citolazme, a naročito njena periferija, ispunjena je dobro razvijenim gER-om. Izgled cisterni gER-a zavisi od aktivnosti PC: kod neaktivnih, cisterne pokazuju sliku koncentričnog membranoznog sistema, dok su kod aktivne sinteze u ćeliji, one jako proširene i prepunjene pahuljičastim sitnozrnastim materijalom-proteinom. Nagomilavanjem ovog proteina formiraju se Rt. Ova pojava verovatno odražava neko patološko stanje, pošto se u normalnim uslovima stvoreni polipeptidi (deo imunoglobulinskog molekula) transportuju do Goldži kompleksa gde se ugrađuje polisaharidna komponenta.[24] Gray i Doniach (1970) konstatuju da je "u svakom slučaju zbunjujuća karakteristika mesto Rt unutar ćelije pošto njihovi konstituenti obuhvataju ugljene hidrate".[12] Poznato je da se u sintezi glikoproteina, proteinska komponenta stvara u cisternama gER-a, a polisaharidna komponenta

Discussion

There is no doubt that there is a high presence of plasma cells in human dental granuloma (up to 80% of the cell contents), as a response to irritation stimuli caused by bacteria and their toxins as well as by numerous products of tissue decomposition, present in necrotic or gangrene decayed pulp. Some stereometric examinations in the previous study, established that from the total granuloma volume, plasma cells make 2.68%.[1] They have, as well, the greatest numerical density (Nv) and greatest surface density (Sv), of all granuloma cells, which tells on their extreme functional activity. [1] Plasma cells activity, in the sense of immunoglobulin synthesis, was discovered in 1948 and since then, that activity has been the subject of intensive study. Fisher and Zbigniew (1970) describe "normal plasma cell"[10] and Toppozada et all, talk about "reactive plasma cell". [7] Our study confirmed a great functional activity of plasma cells, describing their four morphological shape-types. Other authors, dealing with the problem of paraproteinemia and plasma-cell myeloma, and based on the appearance of gER obtained by electro-microscopy, described six types of plasma cells .[10, 13]

According to the data that may be found in literature, ultra-structural studies show that PC cytoplasm contains huge quantity of bound and small quantity of free ribosomes, which is correlated to their function. [12, 23] Except the paranuclear region, where Golgy apparatus is located, other part of cytoplasm and particularly its periphery, is filled with well developed gER. The appearance of gER cisterns depends on the PC activities: in inactive ones, the cisterns show the image of concentric membrane-like system, while in case of cell active synthesis, these are very enlarged and overfilled with flake-like small-grained material – protein. By this protein accumulation, Russell bodies (Rb) are being formed. This phenomenon probably reflects some pathological state, since polypeptides formed in normal circumstances (part of immunoglobulin molecule), are transported to Golgy complex where the polysaccharide component is incorporated. [24] Gray and Doniach (1970), state that "in any case, the characteristic contributing to confusion is the location, Russell bodies occupy within the cell since their constituents include carbohydrates".[12] It is known that in glycoproteins synthesis the protein component

dodaje u Goldži kompleksu. Ovako obrazovan sekret se transportuje do plazma membrane i tamo oslobađa procesom obrnute pinocitoze. Zbog toga je paradoksalno prisustvo glikoproteina u formi Rt unutar gER-a, jer to upućuje ili na obrnuti pravac toka od Goldži aparata, ili na to da se polisaharidna komponenta proteinu dodaje unutar gER-a. Bez obzira o kome načinu se radi, u osnovi nastanka Rt mogao bi da stoji funkcionalni poremećaj PC sa produženom ili hiperaktivnom sekrecijom inunoglobulina.[12]

PC su hiperaktivni u produkciji imunoglobulina.[24,25] Granulirani endoplazmatski retikulum je intracitoplazmatski odeljak za sintezu, segregaciju i komformacione promene u smislu savijanja rastvorljivih proteina. Ukoliko dođe do promena, kontrolni sistem gER-a otkriva nepotpuno ili pogrešno savijanje (nabiranje) proteina i njihove mutacije, pri čemu može reagovati na tri načina: neke proteine razlaže, druge izbacuje iz ćelije, a treće zadržava u gER-u, gde se akumulišu kao Rt.[16] Međutim, Tagger i sar. (2000) smatraju da nagomilani globulini dovode do rasprskavanja PC.[26] Plazma ćelije su opremljene proteolitičkim aparatom koji eliminiše oštećene, pogrešno savijene i nepravilno ili netačno udružene proteine. Tako se smatra da su Rt manifestacija ćelijskog nerazlaganja u gER-u i citoplazmatskim odeljcima. To dovodi do nagomilavanja proteina. Ona su, dakle, posledica slabog funkcionisanja u procesu savijanja (nabiranja) proteina ili njihovog udruživanja i transporta. Postoji i mišljenje da su Rt i agrezomi izraz ćelijske fagocitoze u gER-u koji nije u stanju da ih eliminiše zbog otkazivanja mehanizma degradacije. [27,28]

Svi zubni granulomi, podvrgnuti ovom ispitivanju, sadržavali su PC, a 85% njih i Rt kao jednu od značajnih karakteristika ovog hroničnog zapaljenjskog procesa. Druga karakteristika je postojanje širokih morfoloških varijacija PC, naročito u odnosu na prisustvo Rt. Svi istraživači su jedinstveni u oceni da ova telašca nastaju u PC. Plazma ćelije nemaju evidentnu fagocitnu aktivnost, već im je isključiva funkcija sinteza i sekrecija antitela.[23] Ova funkcija PC je predmet neprekidnog proučavanja pri čemu se, naročito poslednjih godina, one ćelije koje sadrže Rt ponovo nazivaju starim terminom, "Mottove ćelije". Prema podacima iz literature, postoje dve hipoteze o poreklu i

is being generated in gER cisterns and polysaccharide components, being added in the Golgy complex. Such formed secretion is transported to plasma membrane and released by means of the revert pinocytose process. For that reason, the presence of glycoproteins in the form of Russell bodies within gER is paradoxical, because it indicates either the revert flow direction from the Golgy apparatus or the polysaccharide component being added to the protein within gER. Regardless of the manner, the generation of Russel bodies may be related to PC functional disturbance with prolonged or hyperactive secretion of immunoglobulins. [12]

Plasma cells are hyperactive in immunoglobulin production.[24, 25] Granulated endoplasmatic reticulum (gER) represent intra-cytoplasmatic area for synthesis, segregation and conformational changes in the sense of soluble proteins bending. In case of changes occurrence, gER control system detects incomplete or wrong bending (wrinkling) of proteins and their mutations, in that, it can react in three ways: it degrades some proteins, expels other from the cell and it keeps the third ones in gER, where these are accumulated as Russell's bodies. [16] However, Tagger et all, think that the accumulated globulines cause plasma cells blow-out. [26] Plasma cells are equipped with proteolitic apparatus that eliminates damaged, wrongly bent and irregularly (incorrectly) associated proteins. Thus, Russell bodies are considered a manifestation of the cells, non-degrading within gER and cytoplasmatic areas. It leads to proteins accumulation. Therefore, it is the result of weak functioning in the proteins bending process or their association and transport. It is also thought that Russell bodies and aggresomes are the expression of a cell phagocytosis within gER, which is not able to eliminate them due to degradation mechanisms failure. [27, 28]

All dental granulomas presented in this study contained plasma cells, and 85% of them Russell bodies, as well, as one of major characteristics of this chronic inflammation process. The other characteristic is the existence of wide variations of plasma cells, particularly related to the presence of Russell bodies. All researchers have a unique opinion that these bodies are generated in PCs. Plasma cells do not have an evident phagocytic activity but the exclusive function of antibodies synthesis and secretion. [23] This function of PC is constantly the subject of study, in that, particularly during the previous years, those

produkciji Rt. Po prvoj, Rt se javljaju kao rezultat intranukleusne proteinske sinteze, zatim se okružuju troslojnom unit membranom i "ispuštaju" u perinukleusni prostor, odakle idu uobičajenim sekretornim putem preko gER-a. Po drugoj hipotezi, Rt se uglavnom produkuju u cisternama gER-a, ređe u perinukleusnom prostoru. Deo tog prostora, zajedno sa Rt, zalazi u nukleoplazmu i komprimuje unutrašnji deo membrane jedra. Ovaj proces dalje dovodi do stvaranja i intranukleusnih Rt ograničenih samo jednom unit membranom.[18] Rezultati naših EM ispitivanja idu više u prilog drugoj hipotezi, pošto se veoma dobro mogu pratiti morfološke faze u razvoju Rt, koja počinju kao paučinasta elektron svetla masa unutar lumena cisterni gER-a.

Zaključak

U ovom istraživanju ustanovljeno je da su svi ispitivani zubni granulomi sadržavali PC. Ove ćelije su pokazivale široke morfološke varijacije (četiri tipa), naročito u odnosu na prisustvo Rt, koja su se pojavljivala u 85% uzoraka. Ultrastrukturno, Rt se nalaze unutar dilatovanih cisterni gER-a u vidu sferičnih telašaca umerene, ali kompaktne i jednake elektronske gustine. Ustanovljeno mnogobrojno prisustvo Rt u tkivu zubnog granuloma čoveka predstavlja interesantan i gotovo jedinstven fenomen u čijoj osnovi stoji akumulacija imunoglobulina ili njihovih konstituenata i koji je najverovatnije rezultat nekog sekretornog poremećaja PC ili jedan od oblika eliminacije istrošenih PC.

Rad je posvećen sećanju na Profesora Dojčina Dojčinova (1927–2004), začetnika ovih istraživanja.

cells which contain Russell bodies are called again by old term "Mott cells". According to some literature data there are two hypotheses about the origin and production of Russell bodies: According to the first one, Russell bodies are occurring as the result of intra-nucleus protein synthesis, and then, they got surrounded by a three-layer unit membrane and "dropped" in the peri-nuclear space, from where they go further by the customary secretion way via gER. According to the second one, Russell bodies are produced mainly in gER cisterns and more rarely in perinuclear space. A part of that space with Russell bodies penetrates the nucleoplasm and compresses internal part of nucleus membrane. This process further results in generation of intranuclear Russell bodies, limited by only one unit membrane.[18] The results of our EM studies contribute more to the second hypothesis, because the morphological phases in the Russell bodies development that start as cobwebby electron clear mass inside the gER cistern lumen, may be followed in a very good way.

Conclusion

In this research, we came to conclusion that all of examined dental granulomas have contained PC. This cells have been showing wide morphological variety (four tipes) especially regarding the presents of Rts which were appearing in 85% of speciment. In terms of ultrastructure, Russell bodies are located within dilated gER cisterns, in the form of spherical bodies of moderate, by compact and equal electronic density. The established great presence of Russell bodies in the human tooth granuloma represent an interesting and almost unique phenomenon, based on immunoglobulines or their components accumulation, most likely as the result of some secretory disturbance of PCs or one of the forms of worn plasma cells elimination.

This paper is devoted to Professor Dojcin Dojcinov, histo-pathologist (1927 – 2004), who initiated this study.

LITERATURA/REFERENCES

1. Radičević G. Histochemical and immunocytochemical characteristics of dental granuloma with special emphasis on Russell bodies. Doctor thesis, Niš, 1990.

2. Takahachi K, MacDonald DG. Kinane DF. Analysis of immunoglobulin G synthesizing cells in human dental periapical lesins by *in situ* hibridisation and immunohistochemistry. J Oral Pathol Med, 1996, 25(6): 331-5.

3. Grover N, Rao NN, Katian MS. Evaluation of immunoglobulin G synthesizing plasma cells in periapical granuloma and cyst. Indian J Dent Res 2001, 12(1): 35-39.

4. Takahashi K, MacDonald DG, Murayama Y. Kinane DF. Cell synthesis, proliferation and apoptosis in human dental periapical lesions analysed by *in situ* hybridization and histohemistry. Oral Dis, 1999, 5(4): 513-20.

5. Freemann N. Histopathological investigations of the dental granuloma. J Dent Res, 1931, 11(2): 175-200.

6. Radičević G, Petrović S. Russellova telašca u zubnom granulomu. Acta Stom Naissi, 1986, 5:65-71.

7. Toppozada H. The epithelium an chronic inflammatory cells in scleroma. An elecron-microscopyc study. J Laryng Othol, 1981, 95: 1049-57.

8. Neisler D, Crachmar J, Goeken J. An immunopathologic study of giant papylary coniuctivitis associated with an ocular prosthesis. Am J Ophtal, 1981, 92:368-71.

9. Dillman R, Orth R, Royston I, Greco C, Green M. Extracellular paraprotein globules in patient with monoclonal gammopathy. Arch Pathol Lab Med 1982, 106:875-7.

10. Fisher E, Zbigniew Z. Ultrastructural features of plasma cells in patients with paraproteinemias. Am J Clin Pathol, 1970, 54:779-89.

11. Ricci A. Monahan R, Paradise C, Robinson S, Dvorak A. Inclusions in plasmacytoid cells their occurence in a patien with Waldensrom's macroglobulinaemia. Arch Pathol Lab Med, 1982, 106: 452-7.

12. Gray A, Doniach I. Ultrastructure of plasma cells containing Russell bodies in human stomach and thyroid. J Clin Pathol 1970, 23: 608-12.

13. Maldonado J, Brown A, Bayrd E, Pease G. Cytoplasmic and intranuclear electton dense bodies in the myeloma cell. Arch Pathol, 1966, 82: 484-500.

14. Tweel J, Teylor G, Papker JW, Lukes R. Immunoglobin inclusions in Non-Hodgin's lymphomas. Am J Clin Pathol, 1978, 69(3): 306-13.

15. Rappaport H, Jonson F. Intracellular protein resembling Russell bodies in malignant lymphomas associated with acquired hemolytic anemia. Blood, 1955, 10:132-44.

16. Chevet E, Jacob CA, Thomas DY, Bergeton JJ. Calnexin family members as modulators of genetic desease. Semin Cell Dev Biol, 1999, 10(5): 473-80.

17. Leonard EP. On the occucurence an morphology of Russell bodies in the dental granuloma. Oral Surg 1974, 38(4): 584-9.

18. Blom J, Mansa B, Wilk A. A study of Russell's bodies in human monoclonal plasma cells by means immunofluorescence and electron microskopy. Microbiol Scand Sect A, 1976, 84:335-49.

19. Morton T, Clegett J, Yavorsky D. Role of immune compexes in human periapical periodontitis. J Endodon 1977, 3(7): 261-8.

20. Jiang Y, Hirose S, Hamno Y, Codera S, Curui H, Abe M, Terashima K, Ishicawa S, Shirai T. Mapping of a gene for increased suspectibility of B1 cells to Mott Cells in mureine autoimmune disease. J Immunol, 1997, 158(2):992-7.

21. Tazawa K, Tsatsumi Y. Localised accumulation of Russell's body-containing plasma cells in gastic mucosa with Helicobacter pylori infection: "Russell's body gastritis" (letter). Pathol Int, 1998, 48(3): 242-4.

22. Valetti C, Grossi CE, Milstein C, Sitia R. Russell bodies: a general response of secretory cells to synthesis of a mutant immunoglobulin wich can neither exit from, norbe degraded in, the endoplasmic reticulum. J Cell Biol 1991, 115: 983-94.

23. Tanaka A, Mayahara H, Wada S, Tomita J, Tsutsui M. Ultrastructural localisation of acid phosphatase activity in plasma cells containing Russell's bodies in periodontitis. J Oral Pathol 1984, 13:105-10.

24. Petrović S. Morfologija i funkcija imunobiološkog sistema. Naučni podmladak, Niš, 1977, 86-91.

25. Zerosi C, Giardino L, Lafornara D, Scarola V. Presence of Russell's bodies in chronic dental pulp inflammation. Minerva Stomatol 1999, 48(7-8): 307-10.

26. Tagger E, Tagger M, Sarnat H. Russell bodies in the pulp of a primary tooth. Oral Sur, Oral Med, Oral Pathol Oral Radiol Endodon 2000, 90(3): 365-8.

27. Kopito RR, Sitia R. Aggresomes and Russel bodies symptoms of cellular indigestion? EMBO-Rep, 2000, 1(3): 225-31.

28. Kourie JI, Henry CL. Protein aggregation and deposition: implications for ion channel formation and membrane damage. Croat Med 2001, 42(4): 359-74.

Adresa za korespondenciju:

Goran Radičević
Medicinski fakultet
Klinika za stomatologiju,
Zorana Đinđića 52, 18000 Niš, Srbija
Srbija i Crna Gora
Tel./fax: +381 (0) 18 233-839
E-mail: aradic bankerinter.net

Address for correspondence:

Goran Radicevic
Medical Faculty
Dental Clinic
Zorana Djindjica 52, 18000 Nis, Serbia
Serbia and Montenegro
Tel./Fax: + 381 (0) 18 233-839
E-mail: aradic@bankerinter.net