Primljen/ Recived on: 13.7.2019.
Revidiran / Revisedon: 21.8.2019.
Prihvaćen/ Accepted on:15.9.2019.

PRIKAZ SLUČAJA
CASE REPORT
doi: 10.5937/asn2082091H

EVAGINACIJA I INVAGINACIJA ZUBA: PRIKAZ DVA SLUČAJA

DENS EVAGINATUS AND DENS INVAGINATUS: A REPORT OF TWO CASES

Shruthi Hegde[1], Jasmine Shanti Kamath[1], Vidya Ajila[1], Subhas Babu[1], Supriya Bhat[1]

NITTE UNIVERZITET, AB SHETTY MEMORIAL INSTITUT ZA STOMATOLOŠKE NAUKE, ODELJENJE ZA ORALNU MEDICINU I RADIOLOGIJU, MANGALURU, INDIJA

NITTE (DEEMED TO BE UNIVERSITY), AB SHETTY MEMORIAL INSTITUTE OF DENTAL SCIENCES, DEPARTMENT OF ORAL MEDICINE AND RADIOLOGY, MANGALORE, INDIA

Sažetak

Uvod: *Poremaćaji razvoja zuba u fazi morfološke diferencijacije povezani su sa anomalijama u promeni oblika i veličine zuba. Evaginacija i invaginacija zuba razvojne su anomalije u humanoj denticiji. Evaginacija zuba je retka anomalija okarakterisana prisustvom kvržice na okluzalnoj površini zuba i posledica je abnormalne proliferacije i savijanja unutrašnjeg gleđnog epitela i dela zubne papile u reticulum stellatum gleđnog organa; invaginacija zuba javlja se usled savijanja gleđi i dentina u kavumpulpe i nekada može da doseže i do vrha korena zuba.*
Prikaz slučaja: *Ovde smo prikazali slučajeve bilateralne evaginacije drugog premolara donje vilice i invaginaciju lateralnog sekutića gornje vilice.*
Zaključak: *Ovakve razvojne anomalije zuba zaslužuju klinički tretman, jer imaju velike šanse za ranu pojavu oboljenja pulpe*

Ključne reči: *evaginacijazuba, invaginacijazuba, zub u zubu, Leongov premolar*

Corresponding author:
Shruthi Hegde, DDM, PhD, Reader
Mangaluru, Karnataka state, India
Email: drshruthihegde@yahoo.co.in

Abstract

Introduction: *Developmental disturbances of teeth at the stage of morpho-differentiation have been related to abnormalities associated with changes in the tooth shape and size. Dens evaginatus and dens invaginatus are the developmental variations of the human dentition. Dens evaginatus, a rare anomaly characterized by the presence of a tubercle on the occlusal surface of teeth is seen to occur due to abnormal proliferation and folding of the inner enamel epithelium and part of the dental papilla into the stellate reticulum of the enamel organ; whereas, dens invaginatus is seen to occur due to infolding of the enamel and dentine into the pulp cavity and sometimes extending to the root apex.*
Case report*: We report cases with bilateral dens evaginatus in mandibular second premolars and dens invaginatus in maxillary lateral incisor.*
Conclusion: *Such developmental anomalies of teeth deserve clinical importance, as high chances of early pulpal pathosis.*

Key words: *dens evaginatus, dens invaginatus, developmental abnormalities,*

Uvod

Evaginacija zuba (EZ), retka razvojna anomalija zuba, okarakterisana je prisustvom kvržice na okluzalnoj površini zuba i najčešće se javlja na premolarima donje vilice i lingvalnim površinama prednjih zuba. Kvržicu u vidu promencije na okluzalnoj površini premolara prvi je zapazio M.O. Leong 1946. godine i ona se od tada zove Leongov premolar. Prevalencija se kreće aproksimativno oko 2% kod ljudi azijskog porekla, sa nešto većom učestalošću kod pripadnika kineske populacije. Obično se primećuje bilateralno, simetrično prisustvo ove anomalije, nešto učestalije kod osoba ženskog pola[1-3]. Invaginacija zuba (IZ) takođe je razvojna malformacija zuba, koja nastaje kao posledica savijanja zubne papile. Radiografski se vidi kao presavijanje gleđi i dentina, koje se proteže kroz kavumpulpe i ponekad ide do korena zuba, sa mogućnošću da dostigne do njegovog vrha[4]. Ovde prikazujemo slučaj bilateralne evaginacije zuba kod muškarca srednje životne dobi i slučaj invaginacije zuba povezane sa periapikalnom cistom na lateralnom sekutiću gornje vilice.

Prikaz slučaja

Slučaj 1

Muškarac starosti 42 godine javio se Odeljenju oralne medicine i radiologije na rutinski stomatološki pregled. Medicinska stomatološka istorija bolesti pacijenta bila je bez osobenosti. Intraoralnim pregledom, otkrivena je anatomska varijacija na drugim premolarima donje vilice. Levi drugi premolar donje vilice imao je izbočine nalik kvržicama na okluzalnom delu, tako da podseća na molar. Nije bilo vidljivog karijesa na zubu i osetljivosti zuba na perkusiju. Desni drugi premolar donje vilice imao je kvržicu na okluzalnom delu. Na osnovu kliničkog izgleda, kod pacijenta je dijagnostikovana evaginacija zuba na levom i desnom premolaru donje vilice (Slika 1). Zatražena je intraolna periapikalna radiografija (IOPAR). IOPAR je pokazala to da su premolari donje vilice imali izmenjene morfologije sa većom širinom krunice, slično susednim molarima. Prisutna je ekstenzija dentina na okluzalnoj površini u formi krvžice. Koreni su takođe pokazali atipičnu morfologiju i dužinu (Slika 2 A i B).

Introduction

Dens evaginatus (DE), a rare developmental anomaly of the human dentition, which is characterized by the presence of a tubercle on the occlusal surface of teeth, are frequently seen occurring on mandibular premolars and lingual surface of anterior teeth. The tubercle like prominence on the occlusal surface on the premolars was first noted by M.O. Leong in 1946 and it has ever since been called Leong's Premolar. The prevalence is found to be approximately 2% in people of Asian descent, with higher rates of occurrence in the Chinese population. It is usually observed as bilateral, symmetric distribution, with a slight predilection for females[1-3]. Dens invaginatus (DI) is also a developmental malformation of teeth seen due to the infolding of the dental papilla. This is seen radiographically as an infolding of enamel and dentine extending into the pulp cavity and sometimes extending to the root and even may reach the root apex [4]. We are reporting a case of bilateral dens evaginatus in a middle aged male and a case of dens invaginatus associated with periapical cyst in the maxillary left lateral incisor.

Case Report:

Case 1

A 42 year- old male patient reported to the Department of Oral Medicine and Radiology for routine dental check-up. Patient's medical and past dental history was unremarkable. Intraoral examination revealed anatomical variation with respect to the mandibular second premolars. Mandibular left second premolar had cusp-like protrusions from the occlusal aspect with varied pattern resembling molar tooth. There was no visible caries associated with the same tooth and no tenderness on percussion. Mandibular right second premolar had tubercle on occlusal aspect. Based on the clinical presentation patient was diagnosed with dens evaginatus with respect to mandibular left and right second premolars (Figure 1). Intra-oral periapical radiograph (IOPAR) was advised for the same. IOPAR revealed lower second premolars to have altered crown morphology and increased width of the crown as that of the adjacent molars. The dentine showed an extension on to the occlusal surface in form of a tubercle. The roots also showed atypical morphology and length (Figure 2 A and B).

Na osnovu ovih nalaza, postavljena je konačna dijagnoza evaginacije zuba na levom i desnomdrugom premolaru donje vilice.

Based on these finding, final diagnosis of dens evaginatus with respect to mandibular left and right second premolars was arrived upon.

Slika 1. Intra oralna klinička fotografija pokazuje kvržice na donjim drugim premolarima

Figure 1. Intra-oral Clinical photograph showing tubercles on the lower second premolars

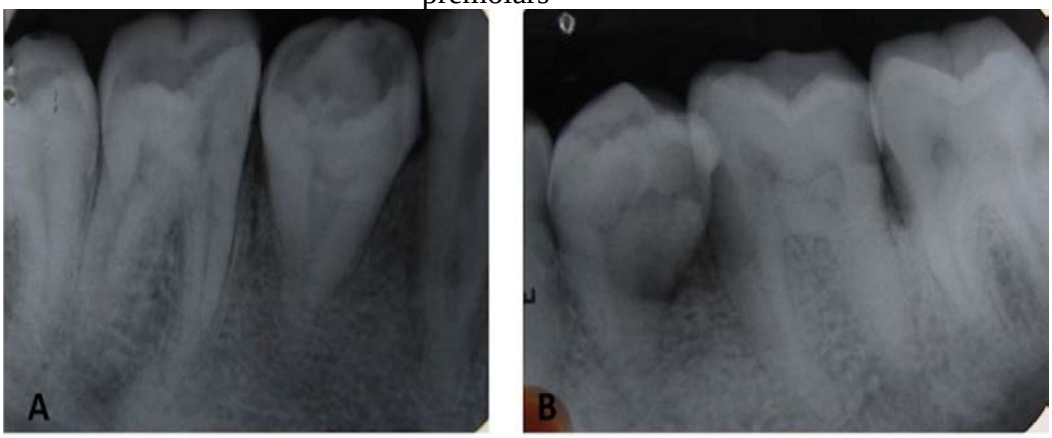

Slika 2 A i B. Intra olralna periapikalna radiografija koja pokazuje zahvaćenu krunicu i morfologiju korena zuba ukazuje na evaginaciju zuba

Figure 2 A and B. Intra-oral Periapical radiograph showing altered crown and root morphology suggestive of Dens evaginatus

Slučaj 2

Pacijent muškog pola star 30 godina javio se Odeljenju za oralnu medicinu i radiologiju zbog bola u gornjem prednjem zubu, koji je trajao nedelju dana. Bol je bio tup, kontinuiran i lokalizovan, bez olakšavajućih faktora. U istoriji bolesti pacijent je naveo i povremenu supuraciju u ovoj regiji. Medicinska i dentalna istorija bolesti pacijenta bila je bez osobenosti. Intraoralni pregled nije pokazao očigledne promene na levom lateralnom sekutiću gornje vilice.

Case 2

A 30 year- old male patient reported to the Department of Oral Medicine and Radiology for pain in the upper front tooth since 1 week. Pain was dull aching type, continuous and localised with no relieving factors. Patient also gave a history of pus discharge from the same area occasionally. Patient’s medical and past dental history was unremarkable. Intraoral examination revealed no apparent changes with respect to the maxillary left lateral incisor.

Na zubu nije bilo vidljive karijesne lezije, ali je bio prisutan bol zuba provociran blagom perkusijom. Zatražena je intraoralna periapikalna radiografija (IOPAR) levog lateralnog sekutića gornje vilice, koja je pokazala izmenjenu morfologiju zuba i dobro definisanu radiopaknu invaginaciju sa radiolucentnom longitudinalnom ekstenzijom od krunice do vrha korena zuba (Slika 3). Uočen je gubitak lamine dure na centralnim i lateralnim sekutićima gornje vilice. Uočena je i dobro definisana radiolucentna formacija veličine oko 1,5 cm x 1 cm u periapikalnoj regiji, koja se proteže od medijalnog dela levog centralnog sekutića gornje vilice do distalnog dela levog lateralnog sekutića gornje vilice. Na osnovu ovog nalaza, postavljena je konačna dijagnoza periapikalne sekundarne ciste od invaginacije levog lateralnog sekutića gornje vilice. Pacijent je upućen na apikotomiju sa endodontskim tretmanom zuba.

There was no visible caries associated with the same tooth but tenderness on percussion was elicited. Intra-oral periapical radiograph (IOPAR) with respect to maxillary left lateral incisor was advised, which revealed altered tooth morphology and a well-defined radiopaque invagination with a radiolucent interior extending longitudinally from the crown to the root apex (Figure 3). Loss of lamina dura was observed with respect to maxillary left central and lateral incisors. A well-defined radiolucency measuring around 1.5 X 1 cm in size was present in the periapical region extending from medial aspect of maxillary left central incisor to the distal aspect of maxillary left lateral incisor. Based on these findings, final diagnosis of periapical cyst secondary to dens invaginatus with respect to maxillary left lateral incisor was arrived upon. Patient was referred for apicectomy and endodontic treatment for the same.

Slika 3. Intra oralna periapikalna radiografija pokazuje periapikalnu cistu uzrokovanu invaginacijom levog lateralnog sekutića gornje vilice

Figure 3. Intra oral periapical radiograph showing periapical cyst due to dens invaginatus with respect to maxillary left lateral incisor

Diskusija

Poremećaji tokom razvoja zuba u fazi morfološke diferencijacije uzrokuju anomalije u obliku i veličini zuba. Evaginacija i invaginacija zuba spadaju u takve razvojne varijacije zuba[5].

Postoji mnogo sinonima za EZ, kao što su dodatna kvržica, okluzalno tuberkulisani premolar, Leongov premolar, evaginisani odontom i okluzalna perla.

Discussion

Disturbances during tooth development at the stage of morpho-differentiation have been related to abnormalities in the tooth shape and size. Dens evaginatus and dens invaginatus are such two developmental variations of tooth[5].

The many synonyms of DE are tuberculated cusp, accessory tubercle, occlusal tuberculated premolar, Leong's premolar, evaginatus odontoma and occlusal pearl.

Najčešća lokalizacija EZ je drugi premolar donje vilice, kao u slučaju pacijenta koga smo prikazali. Molari, očnjaci i sekutići takođe mogu biti zahvaćeni i promena se pojavljuje kao dopunska kvržica ili protuberancija na okluzalnoj površini. EZ se može javiti na jednom zubu ili dva zuba, odnosno obostrano. Izbačen rog pulpe prisutan je ispod tuberkuluma, stoga je ova kvržica često slaba tačka zuba[6]. Ostali problemi koji se vezuju za EZ su okluzalna interferncija, estetika, sklonost karijesu, atricija, akcidentalna fraktura kvržice i iritacija jezika tokom govora.

Levitan i sar[3]. su EZ podelili na 6 kategorija i to na osnovu faze infekcije pulpe, statusa zatvorenosti apeksa i posledičnog terapijskog protokola za lečenje istih. Tip I i II predstavljaju zube bez patologije pulpe i zrelim i nezrelim vrhom korena zuba. Tipovi III i IV predstavljaju zube sa inflamacijom pulpe, a tipovi V i VI zube sa nekrotičnom pulpom. Ukoliko vrh korena zuba nije zatvoren, kao kod tipova IV i VI, tada se aplikuje mineral-trioksi agregat, sa pulpotomijom ili bez pulpotomije; ako je vrh korena zuba zatvoren, kao kod tipova III i V, onda se savetuje endodontski tretman[3]. Slučaj našeg pacijenta može se okarakterisati kao tip I EZ.

Kod pacijenata sa EZ može se izvršiti selektivno brušenje, kako bi se izbegao prevremeni kontakt uz mogućnost postavljanja zalivača, kako bi se izvršila prevencija pojave karijesa. EZ bi mogla biti izazov za endodontsku terapiju u slučajevima kada je ona indikovana.U slučaju našeg pacijenta, ovakav tretman nije bio potreban, jer je pacijent bio asimptomatski.

Invaginacija zuba je anomalija sa kliničkom i radiografskom prezentacijom. Klinički može biti prisutna kao neobična morfologija krunice sa dubokom lingvalnom jamicom[7]. Lateralni sekutići gornje vilice najčešće su zahvaćeni IZ, kao što je to bilo i u slučaju našeg pacijenta[4]. Kada su zahvaćeni lateralni sekutići gornje vilice, incidencija se kreće u rasponu od 0,25% do 5,1%. Predhodne studije, koje su obuhvatile različite populacione grupe pokazale su to da IZ zahvata maksilarne lateralne sekutiće, centralne sekutiće, premolare i očnjake u opadajućem redosledu[8]. Guttal KS je istakao da se IZ retko javlja na zubima donje vilice[8].

U najvećem broju slučajeva, invaginacija zuba detektuje se slučajno, radigrafskim snimanjem[4]. U slučaju našeg pacijenta, dijagnoza je postavljena zbog prisutnih simptoma. Radiografski, gleđna invaginacija u kanal korena zuba uočava se kao radipakni obod, koji se pruža od cinguluma do kanala korena zuba[7].

Mandibular second premolars are usually affected in DE as in our case. Molars, canines, and incisors also can be affected and it appears as accessory cusp or a protuberance in the occlusal aspect. DE is observed in one or two teeth, on both sides. Projecting pulp horns are present below the tubercles; hence this tubercle is often the weakest spot of the tooth[6]. The other concerns associated with DE are occlusal interference, esthetics, caries susceptibility, attrition, accidental cuspal fracture and tongue irritation during speech.

Levitan et al.[3] have classified DE into6 categories based on the stage of pulpal infection, status of apex closure and the subsequent treatment protocol employed for the same[3]. Type 1 and 2 are teeth with no pulpal pathology and mature and immature apex respectively. Only conservative treatment is required for these teeth. Types 3 and 4 are teeth with inflamed pulp and types 5 and 6 are teeth with necrotic pulp. If the root apex is not closed as in type 4 and 6, then mineral trioxide aggregate with or without pulpotomy is done; if the apex is closed as in types 3 and 5, endodontic intervention is advised[3]. Our case can be classified as typeIDE.

In patients with DE selective grinding of the projection can be done to remove any premature contact and sealants can be placed to prevent caries. DE would pose as a challenge to endodontic therapy in cases where it is indicated. In our case treatment was not required as the patient was asymptomatic.

Dens invaginatus has variable clinical and radiographic presentations. Clinically it may present an unusual crown morphology with a deep lingual pit[7]. Maxillary lateral incisors are most susceptible for DI as in our case[4]. When the maxillary lateral incisors are affected, the frequency ranged from 0.25 to 5.1%. Previous studies among several population groups showed that DI affects maxillary lateral incisors, central incisors, premolars, and canines in decreasing order 8. Guttal KS reported that DI involving mandibular teeth is rare[8].

Dens invaginatus is detected as incidental finding on a radiograph in most of the cases[4]. Our case was diagnosed due to the presenting symptoms. Radiographically, the enamel invaginating into the root canal appears as a radiopaque rim, extending from the cingulum into the root canal. The invagination may manifest in different forms such as loop-like, pear-shaped and tooth within a tooth[7].

Oehler[9] je 1957. godine IZ podelio na osnovu dubine gleđne invaginacije. Kod invaginacije zuba tip I, gleđna invaginacija je ograničena na gornji deo zuba. Tip II pokazuje produženje invaginacije do gleđno-cementne granice. Kod tipa III invaginacija prodire u koren i stvara se dodatni otvor kanala na bočnoj strani zuba. Slučaj našeg pacijenta je okarakterisan kao IZ Tip III[10].

2D radiografije ne mogu dati dovoljne dijagnostičke informacije o složenosti anatomije invaginacije zuba[11]. CBCT obezbeđuje preciznu dijagnozu i tip IZ[12]. Invaginacija zuba može omogućiti ulaz mikroba[7]. Rana dijagnoza je od vitalnog značaja u obezbeđivanju preventivnog tretmana. Prikazani slučaj imao je periapikalnu patologiju zbog IZ.

Iako se ponekad evaginacija zuba može prevideti kod asimptomatskih pacijenata, kod ekstenzivnih invaginacija prisutan je povišeni rizik od nekroze pulpe i periapikalnih lezija, kao što je to bilo u slučaju našeg pacijenta. Ukoliko nema znakova infekcije pulpe, terapija nije potrebna. Ukoliko je potrebno izvršiti ekstenzivni endodontski tretman, on je obično otežan raznolikom morfologijom kanala korena zuba[13,14].

Zaključak

Prikazane su kliničke i radiografske karakteristike evaginacije premolara donje vilice i invaginacije levog lateralnog sekutića gornje vilice. Ovakve razvojne anomalije zuba zaslužuju klinički tretman, jer imaju velike šanse za ranu pojavu oboljenja pulpe.

Sukob interesa: NIL

Izvor finansiranja: NIL

Oehler[9] classified DI in 1957 based on the enamel invagination depth noticed radiographically[9]. In Type I enamel lined invagination restricted to the upper part of the tooth; type II exhibits elongation of the invagination ahead of cement-enamel junction. In type III invagination penetrates the root and an extra canal opening on lateral side of root is created. Our case is categorized as DI type III[10].

2D radiographs may not produce sufficient diagnostic information about complexity of the dens invaginatus anatomy[11]. CBCT allows for precise diagnosis and type of DI[12]. The invagination may allow entry of microbes[7]. Early diagnosis is vital to provide preventive treatment. Presenting case had periapical pathology due to DI.

Although dens invaginatus is sometimes overlooked in asymptomatic patients, with extensive invagination, there is a higher risk of pulpal necrosis and periapical pathology as was seen in our case. If there are no signs of pulp pathology, no treatment is required. If extensive endodontic treatment is required, it is often complicated due to the varied morphology of the root canal[13,14].

Conclusion

Clinical and radiographic features of dens evaginatus affecting the mandibular premolars and dens invaginatus involving the maxillary left lateral incisor is reported here. Such developmental anomalies of teeth deserve clinical importance, as high chances of early pulpal pathosis.

Sukob interesa: Ne postoji

Izvor finansiranja: Ne postoji

LITERATURA /REFERENCES

1. Echeverri EA, Wang MM, Chavaria C, Taylor DL. Multiple dens evaginatus: diagnosis, management, and complications: case report. Pediatr Dent 1994;16(4):314-7.
2. Stecker S, DiAngelis AJ. Dens evaginatus: a diagnostic and treatment challenge. J Am Dent Assoc. 2002; 133: 190-3.
3. Levitan ME, Himel VT. Dens evaginatus: literature review, pathophysiology, and comprehensive treatment regimen. J Endod 2006; 32: 1-9.
4. Hülsmann M. Dens invaginatus: aetiology, classification, prevalence, diagnosis, and treatment considerations. International Endodontic Journal 1997;30, 79–90.
5. Sharma G, Mutneja AR, Nagpal A, Mutneja P. Dens evaginatus and dens invaginatus in a double tooth: A rare case report. Indian J Dent Res 2015;26: 545-9.
6. Rao Y-G, Guo L-Y, Hu T. Multiple Dens Evaginatus of Premolars and Molars in Chinese Dentition: A Case Report and Literature Review. Int J Oral Sci 2010; 2(3): 177–180.
7. Koteeswaran V, Chandrasekaran S, Natanasabapathy V. Endodontic management of double dens invaginatus in maxillary central incisor. Journal of Conservative Dentistry : JCD. 2018;21(5):574-577.
8. Guttal KS, Naikmasur VG, Bhargava P, Bathi RJ. Frequency of Developmental Dental Anomalies in the Indian Population. Eur J Dent. 2010;4:263-9.
9. Oehlers FA. Dens invaginatus (dilated composite odontome). I. Variations of the invagination process and associated anterior crown forms. Oral Surg Oral Med Oral Pathol. 1957;10:1204–18.
10. Izaz S, Bolla N, Dasari B, Guntaka S. Endodontic Management of Calcified Oehler's Type IIIb Dens Invaginatus in Permanent Maxillary Lateral Incisor Using Cone Beam Computed Tomography . Journal of Dentistry. 2018;19(3):243-247.
11. Dembinskaite A, Veberiene R, Machiulskiene V. Successful treatment of dens invaginatus type 3 with infected invagination, vital pulp, and cystic lession: A case report. Clinical Case Reports. 2018;6(8):1565-1570.
12. Różyło TK, Różyło-Kalinowska I, Piskórz M. Cone-beam computed tomography for assessment of dens invaginatus in the Polish population. Oral Radiology 2018;34(2):136-142.
13. Mupparapu M, Singer SR. A rare presentation of dens invaginatus in a mandibular lateral incisor occurring concurrently with bilateral maxillary dens invaginatus: Case report and review of literature. Aust Dent J 2004;49:90–93.
14. Alani A, Bishop K. Dens invaginatus. Part 1: classification, prevalence and aetiology. Int Endod J 2008;41:1123–36.