

Primljen/ Received on:14.4.2021.
Revidiran / Revised on: 06.08.2021.
Prihvaćen/ Accepted on:03.09.2021

PRIKAZ SLUČAJA
CASE REPORT
doi: 10.5937/asn2184282F

PARRY-ROMBERGOV SINDROM I DEFORMITET “PRESEK SABLJOM” – PRIKAZ SLUČAJA

PARRY ROMBERG SYNDROME WITH EN COUP DE SABRE: A REPORT OF A RARE CASE

Mohamed Faizal Asan¹, Subhas Babu G¹, Vikram Shetty², Renita Lorina Castelino¹, Vaibhav Pandita¹

¹ NITTE UNIVERZITET, AB SHETTY MEMORIJALNI INSTITUT ZA STOMATOLOŠKE NAUKE
DEPARTMENT ZA ORALNU MEDICINU I RADIOLOGIJU, MANGALORE, INDIJA

² NITTE UNIVERZITET, NITTE MEENAKSHI INSTITUT ZA KRANIOFACIJALNU HIRURGIJU, MANGALORE, INDIJA

¹ NITTE (DEEMED TO BE UNIVERSITY), AB SHETTY MEMORIAL INSTITUTE OF DENTAL SCIENCES, DEPARTMENT OF ORAL MEDICINE AND RADIOLOGY MANGALORE, INDIA

² NITTE (DEEMED TO BE UNIVERSITY), NITTE MEENAKSHI INSTITUTE OF CRANIOFACIAL SURGERY, MANGALORE, INDIA

Sažetak

Osnov problema: Parry-Rombergov sindrom (PRS) je redak razvojni poremećaj, koji se manifestuje sporom i progresivnom atrofijom lica, često jednostranom i zato se naziva i progresivna hemifacijalna atrofija. Opseg atrofije može varirati, uključujući površinski sloj kože i atrofiju, koja zahvata dublja tkiva do kosti. Kliničke karakteristike PRS-a uključuju kraniofacijalne, neurološke, oftalmološke i dermatološke manifestacije, koje rezultiraju različitim funkcionalnim i psihološkim problemima. PRS i linearna skleroderma pripadaju istoj vrsti bolesti. Može postojati jasna granica između normalne i abnormalne kože, koja se može uvideti kod PRS-a, pod nazivom „presek sabljom“. PRS se najčešće javlja kod žena i uključuje levu stranu lica.

Metod rada: Opisujemo slučaj PRS-a kod mlade devojkice sa deformitetom „presek sabljom“ na desnoj strani lica.

Rezultati: Mikrohiruska rekonstrukcija lica zahvaćene strane je zlatni standard među metodama za korekciju asimetrije lica. U prikazanom slučaju, pacijentkinja se trenutno nalazi na dugogodišnjem praćenju, a estetski hirurški tretman planira se kada atrofija bude u stabilnoj fazi.

Zaključak: Povezivanje PRS-a sa Linearnom sklerodermijom može predstavljati poteškoću u dijagnozi ovog sindroma. Pažljivo evidentiranje istorije bolesti i klinički pregled pacijenta uz odgovarajuće ispitivanje mogu pomoći u postavljanju tačne dijagnoze.

Ključne reči: kompjuterska tomografija konusnih zraka, hemifacijalna atrofija, maksilofacijalne abnormalnosti, retke bolesti.

Corresponding author:

Subhas Babu G,
AB Shetty Memorial Institute of Dental Sciences (ABSMIDS),
Nitte (Deemed to be University),
Mangalore, India
Email: goginenisb@yahoo.co.in

Abstract

The basis of the problem: Parry Romberg syndrome (PRS) is a rare developmental disorder manifesting as a slow and progressive atrophy of the face which is often unilateral, hence also termed as progressive hemifacial atrophy. The extent of the atrophy may vary, involving the superficial skin extending upto the underlying bone. The clinical features of PRS include craniofacial, neurologic, ophthalmic and dermatological manifestations, which result in various functional and psychological problems. PRS and linear scleroderma belong to the same disease spectrum. There can be demarcating line between the normal and abnormal skin seen in PRS, termed as “en coup de sabre”. PRS is most commonly seen in females and involves the left side of the face.

Method: We hereby report a case of PRS in a young girl presenting with en coup de sabre appearance on the right side of face.

Results: Microsurgical facial reconstruction of the affected side is known to be the gold standard method for correction of the facial symmetry. In our case, the patient is currently kept under long term follow up and cosmetic surgical treatment will be planned once the atrophy attains stability.

Conclusion: The association of PRS with linear scleroderma may present difficulty in its diagnosis. Hence, careful recording of the history and clinical examination with appropriate investigations can aid in establishing the correct diagnosis.

Key words: cone-beam computed tomography, hemifacial atrophy, maxillofacial abnormalities, rare diseases.

2021 Faculty of Medicine in Niš. Clinic of Dentistry in Niš.
All rights reserved / © 2021. Medicinski fakultet Niš. Klinika
za stomatologiju Niš. Sva prava zadržana.

Uvod

Parry-Rombergov sindrom (PRS) je redak razvojni poremećaj, koji pogađa kraniofacijalnu regiju. Hillier Parry 1815. godine i Moritz Heinrich Romberg 1846. godine prvi su opisali ovaj entitet¹. PRS karakteriše sporo napredujuća atrofija lica, koja je često jednostrana, pa se naziva i progresivna hemifacijalna atrofija. Poremećaj sporo napreduje od detinjstva do adolescencije, posle koje se može stabilizovati. Maksilofacijalne manifestacije su najistaknutije, zajedno sa neurološkim i oftalmološkim promenama^{2,3}. Atrofija se u početku može pojaviti na površini kože, ali kasnije može zahvatiti potkožno tkivo, masno tkivo, fascije, mišiće, hrskavicu i kosti. Zlezdane strukture, takođe, mogu biti uključene⁴. Cilj ovog članka je da opiše slučaj Parry-Rombergovog sindroma.

Prikaz slučaja

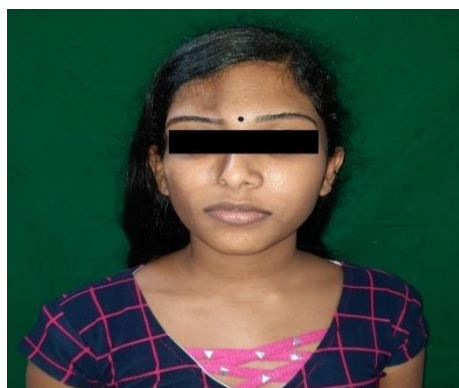Šesnaestogodišnja devojčica žalila se od detinjstva na asimetriju na desnoj strani lica. Njena bolest počela je kada je imala 9 godina i polako je napredovala do stadijuma predstavljenog u ovom radu. Takođe, javio se gubitak kose na desnoj strani poglavine. Nisu zabeleženi drugi neurološki i oftalmološki simptomi. Nije bilo istorije traume, niti porodične istorije vezane za ovo oboljenje. Prilikom kliničkog pregleda, primećena je asimetrija desne strane lica, sa odstupanjem usana, hiperpigmentacijom i hipoplazijom lica i nosa (Slika 1). Uočen je linearni ožiljak, koji ukazuje na deformitet „presek sabljom“, koji se proteže od desnog frontalnog područja do desne bočne hrskavice nosa (Slika 2). Duž zahvaćene strane, zapaža se suvo vlasništvo sa izraženom alopecijom (Slika 3). Intraoralnim pregledom, ustanovljena je stalna denticija, koja obuhvata zube u prvoj klasi, sa obe strane. Pacijentkinja je upućena na neurološke i oftalmološke analize, kako bi se isključile abnormalnosti. Urađena je kompjuterska tomografija konusnih zraka (CBCT), zbog procene uznapredovalosti oboljenja (Slika 4) i uočena je abnormalnost nosnog septuma sa nerazvijenom desnom nosnom šupljinom, hipoplastičnim desnim etmoidnim i frontalnim sinusom (Slika 5). Desni maksilarni sinus i desni kondil bili su hipoplastični, u poređenju sa levom stranom (Slika 6). Tako je, na osnovu kliničkih i radiografskih karakteristika, postavljena dijagnoza PRS-a sa deformitetom „presek sabljom“, koji zahvata desnu stranu lica.

Introduction

Parry Romberg syndrome (PRS) is an uncommon developmental disorder affecting the craniofacial region. Hillier Parry in 1815 and Moritz Heinrich Romberg in 1846 were the first to describe this entity¹. PRS is characterized by slowly progressing facial atrophy which is often unilateral, hence it is also termed as progressive hemifacial atrophy. The disorder has a slow progression from childhood upto adolescence after which it may attain stability. The maxillofacial manifestations are most prominent along with neurological and ophthalmic changes^{2,3}. Atrophy may present initially in the superficial skin but later can involve the subcutaneous tissue, fat, fascia, muscle, cartilage and bone. The underlying glandular structures may also be involved⁴. The objective of this article is to report a case of Parry Romberg syndrome.

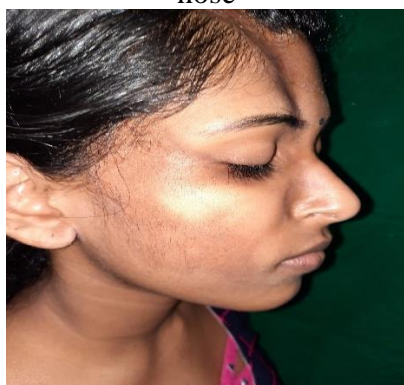
Case report

A 16 year old girl presented with the complaint of asymmetry on the right side of her face since childhood. Her illness started when she was 9 years old and it has progressed slowly to the present state. She had also developed hair loss on the right frontal region of the head. There was no other neurological and ophthalmic symptoms. There was no history of trauma and no relevant family history. On physical examination, facial asymmetry with deviation of lips, hyperpigmentation and hypoplasia of the face and nose was noted on the right side (Figure 1). A linear scar suggestive of “en coup de sabre” was seen extending from the right frontal region to the right lateral cartilage of the nasal cavity (Figure 2). Dry scalp with marked alopecia was noted along the affected side (Figure 3). Intraoral examination revealed permanent dentition with no significant findings and Class 1 molar relation was observed on both the sides. The patient was referred for neurological and ophthalmological evaluation, which ruled out abnormalities. Cone beam computed tomography (CBCT) was taken to evaluate the bony involvement (Figure 4), presence of deviated nasal septum with underdeveloped right nasal cavity, hypoplastic right ethmoidal and frontal sinus (Figure 5). The right maxillary sinus and right condyle were hypoplastic when compared to the left side (Figure 6). Thus, on correlation of the clinical and radiographic features, a diagnosis of PRS with en coup de sabre involving the right side of the face was made.



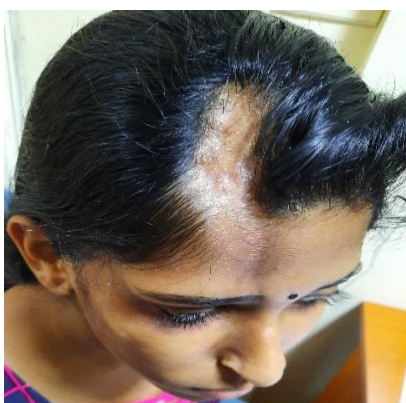Slika 1: Klinička slika prikazuje asimetriju lica sa hiperpigmentacijom na desnoj strani, zajedno sa promenama na usnama i nosu.

Figure 1: Clinical picture showing facial asymmetry with hyperpigmentation on the right side along with deviation of lips and nose



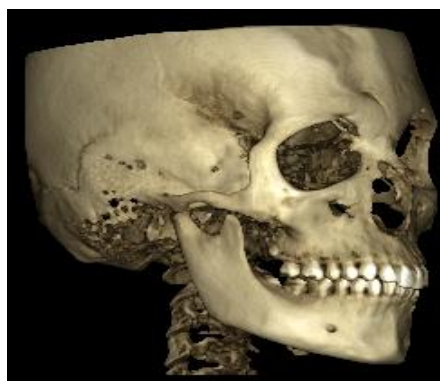Slika 2: Bočni prikaz desne strane lica pokazuje defekt u frontalnoj regiji, koji se proteže do bočnog dela nosne šupljine

Figure 2: Right lateral view of the face showing a defect in the frontal region extending to the lateral part of nasal cavity



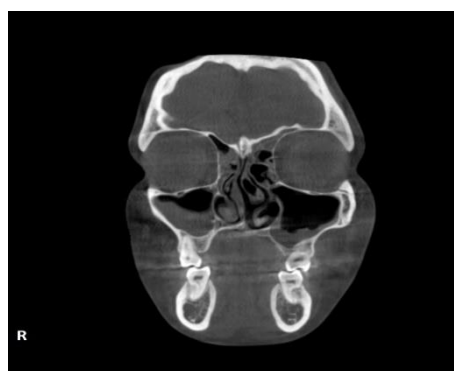Slika 3: Klinička slika, koja pokazuje izraženu alopeciju

Figure 3: Clinical picture showing marked alopecia



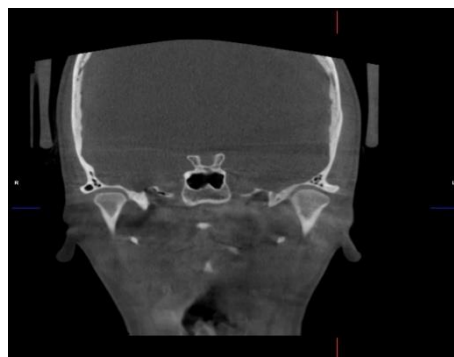
Slika 4: 3D rekonstrukcija, koja pokazuje defekt na čeonj kosti

Figure 4: 3D Reconstruction demonstrating the defect in the frontal bone



Slika 5: Koronalna CBCT slika, koja prikazuje odstupanje nosnog septuma i nerazvijenu desnu nosnu šupljinu, hipoplastičnu desnu stranu maksilarnih i etmoidalnih sinusa, sa delimičnim zamućenjem

Figure 5: Coronal CBCT image showing deviated nasal septum and underdeveloped right nasal cavity, hypoplastic right maxillary and ethmoidal sinuses with partial opacification



Slika 6: Koronalna CBCT slika, koja prikazuje hipoplaziju desnog kondila

Figure 6: Coronal CBCT image showing hypoplasia of the right condy

Diskusija

Parry-Rombergov sindrom je redak degenerativni poremećaj, koji dovodi do različitih funkcionalnih i psiholoških problema kod obolelih osoba, zbog asimetrije lica⁵. Poremećaj se može pripisati različitim etiološkim faktorima, uključujući nasledne faktore, viruse, traume, poremećaje simpatičkog nervnog sistema, endokrine poremećaje, autoimune uzroke itd.³ Stone J. je prijavio stopu prevalencije od 1 na 700.000 među opštom populacijom. Prema literaturnim podacima, približan vremenski razmak od početka poremećaja do dijagnoze je oko 10 godina, jer većina obolelih pacijenata i dalje nije svesna svoga stanja u blažem obliku⁶. Bolest je prisutna većinom kod žena, a leva strana lica najčešće je pogođena⁷. Međutim, u slučaju naše pacijentkinje desna strana lica bila je zahvaćena defektom duž srednje linije, a zahvaćena koža bila je suva i hiperpigmentisana. U prikazanom slučaju, primećena je linija koja razgraničava normalnu kožu od abnormalne kože, koja je označena kao "presek sabljom", slična linearnoj sklerodermiji. PRS i linearna skleroderma pripadaju istoj grupaciji bolesti i oko 28% – 42% slučajeva PRS-a koezistira sa lokalizovanom sklerodermom⁸. Segna i saradnici⁹ prijavili su niz slučajeva pacijenata sa PRS-om i linearnom sklerodermijom lica sa različitim prevalencijom, slično kao u slučaju naše pacijentkinje. Defekti kose, poput fokalne alopecije, takođe su primećeni u slučaju naše pacijentkinje. Uobičajene maksilofacijalne manifestacije uključuju promene u predelu nosa i usana na zahvaćenoj strani, što je primećeno i u slučaju naše pacijentkinje, ali druge maksilofacijalne karakteristike, kao što su atrofija jezika, nerazvijene obe vilice, tvrdo i meko nepce, odloženo nicanje zuba i to sa kratkim korenima nisu detektovani u slučaju pacijentkinje predstavljene u ovom radu¹⁰. Mogu se javiti i retinalni vaskulitis i gubitak periorbitalnog masnog tkiva, koji rezultira enoftalmosom, a česte su i oftalmološke manifestacije. Oboleli pojedinci mogu, takođe, imati paresteziju lica, neuralgiju trigeminusa i epilepsiju, koji nisu primećeni u slučaju naše pacijentkinje⁵. Farmakološko lečenje PRS-a sa coup de sabre deformitetom uključuje steroide, D penicilamin, metotreksat, topikalne analoge vitamina D3, psoralen sa UVA, ali je stopa uspeha različita od slučaja do slučaja⁶.

Discussion

Parry Romberg syndrome is a rare degenerative disorder leading to various functional and psychological problems in the affected individuals due to facial asymmetry⁵. The disorder may be attributed to various etiologies including hereditary, viral, trauma, sympathetic malfunctions, endocrine disturbances, autoimmune causes, etc.³ Stone J reported a prevalence rate of 1 per 700,000 among the general population. According to the literature evidences, the approximate time gap between the onset of the disorder to diagnosis is about 10 years, as most of the affected patients remain unaware of the condition in the milder form⁶. The disease has a female predilection with left side of the face being most frequently affected⁷. However, in our case, the right side of the face was affected with a defect along the midline and the affected skin was dry and hyperpigmented. A line demarcating the normal with abnormal skin, called "en coup de sabre" which is similar to linear scleroderma was seen in our case. PRS and linear scleroderma belong to the same disease spectrum and about 28–42% of PRS cases coexist with localized scleroderma⁸. Segna et al.⁹ have reported a series of cases with PRS and linear facial scleroderma with varied involvement, similar to our case. Hair defects such as focal baldness was also seen in our case. Common maxillofacial manifestations include deviation of nose and mouth to the affected side as observed in our case, but other maxillofacial features like atrophy of the tongue, underdeveloped jaws, hard and soft palate, delayed tooth eruption and teeth with short roots were not present in our case¹⁰. Retinal vasculitis and loss of periorbital fat resulting in enophthalmos are the common ophthalmological manifestations. The affected individuals can also present with facial paresthesia, trigeminal neuralgia and contralateral epilepsy, which were not seen in the present case⁵. The Pharmacological management of PRS with coup de sabre include steroids, D-penicillamine, methotrexate, topical Vitamin D3 analogues, psoralen with UVA have been reported in the literature but the success rate varies on a case-to-case basis⁶. Patient education, motivation and surgical correction of the atrophy need to be considered for a successful treatment outcome. Microsurgical facial reconstruction of the affected side is known to be the gold

Obrazovanje pacijenata, motivaciju i hiruršku korekciju atrofije treba uzeti u obzir, kada je reč o uspešnom ishodu lečenja. Poznato je to da je mikrohrurška rekonstrukcija lica zahvaćene strane zlatni standard među metodama za korekciju asimetrije lica¹⁰. Kozmetičke hirurške opcije uključuju mikrovaskulature slobodne reznjeve, aloplastične graft materijale za transplantaciju, autolognu transplantaciju masti itd.¹¹ Poznato je to da titanijumski implantati za rekonstrukciju defekta daju dobre rezultate¹². U prikazanom slučaju, pacijentkinja se trenutno nalazi na dugogodišnjem praćenju, a estetski hirurški tretman planira se kada atrofija bude u stabilnoj fazi.

Zaključak

PRS je redak, samoograničavajući poremećaj sa različitom uključenošću i težinom simptoma. Povezivanje PRS-a sa linearnom sklerodermijom može napraviti poteškoće u njegovoj dijagnozi. Zbog toga je potreban pažljiv fizički i sistematski pregled za postavljanje ispravne dijagnoze i formiranja sveobuhvatnog plana lečenja.

Sukobi interesa

Nema

standard method for correction of the facial symmetry¹⁰. Cosmetic Surgical options include Microvascular free flaps, Alloplastic graft materials, autologous fat transplantation, etc¹¹. Custom made titanium implants for reconstruction of the defect are known to give good outcomes¹². In our case, the patient is currently kept under long term follow up and cosmetic surgical treatment will be planned once the atrophy attains stability.

Conclusion

PRS is a rare, self-limiting disorder with varied involvement and severity. The association of PRS with linear scleroderma may present difficulty in its diagnosis. Therefore, a careful physical and systemic examination is required for establishing a proper diagnosis and formulating a comprehensive treatment plan.

Conflicts of interest

Nil

LITERATURA /REFERENCES

1. Goldhammer Y, Kronenberg J, Tadmor R, Braham J, Leventon G: Progressive hemifacial atrophy (Parry-Romberg's disease), principally involving bone. *J Laryngol Otol.* 1981;95 (6): 643-647.
2. Buonaccorsi S, Leonardi A, Covelli E, Indrizzi E, Perdicchi A, Fini G. Parry-Romberg syndrome. *J Craniofac Surg.* 2005;16(6):1132-1135.
3. Deshingkar SA, Barpande SR, Bhavthankar JD, Humbe JG. Progressive hemifacial atrophy (Parry-Romberg Syndrome). *Contemp Clin Dent.* 2012;3(Suppl 1):S78-81.
4. Madasamy R, Jayanandan M, Adhavan UR, Gopalakrishnan S, Mahendra L. Parry Romberg syndrome: A case report and discussion. *J Oral Maxillofac Pathol.* 2012;16(3):406-410.
5. Rangare AL, Babu SG, Thomas PS, Shetty SR. Parry-romberg syndrome: a rare case report. *J Oral Maxillofac Res.* 2011;2(2):e5.
6. Lazaridou E, Giannopoulou C, Apalla Z, Fotiadou C, Trigoni A, Ioannides D. Parry-Romberg syndrome. *J Dermatol Case Rep.* 2010;4:30-32.
7. Stone J. Parry-Romberg syndrome: a global survey of 205 patients using the Internet. *Neurology.* 2003;61(5):674-676.
8. Srinivasan R, Joy ST. Parry-Romberg syndrome in an adolescent: a case report on progressive hemifacial atrophy. *Oxf Med Case Reports.* 2020;2020(1):omz127.
9. Segna E, Pucciarelli V, Beltramini GA, Sforza C, Silvestre FJ, Gianni AB, et al. Parry Romberg Syndrome and linear facial scleroderma: management in pediatric population. *J Biol Regul Homeost Agents.* 2017;31(2 Suppl 1):131-138.
10. Abdelnour JGW, Abdelnour YGW, Kerollos RAB, Mahmoud ZIT. Parry-Romberg syndrome associated with en coup de sabre in a patient from South Sudan - a rare entity from East Africa: a case report. *J Med Case Rep.* 2019;13(1):138.
11. Sargunar B, Ebenezer V, Balakrishnan R, Priya S. Parry Romberg Syndrome-A Review of Treatment Options. *Biomed Pharmacol J* 2014;7(1):207-211.
12. Kim JY, Jung BK, Kim YS, Roh TS, Yun IS. Forehead reconstruction with a custom-made three-dimensional titanium implant in a Parry-Romberg syndrome patient. *Arch Craniofac Surg.* 2018;19(2):135-138.