

Primljen/ Received on: 12.6.2021.  
Revidiran / Revised on: 19.09.2021.  
Prihvaćen/ Accepted on: 01.10.2021.

PRIKAZ SLUČAJA  
CASE REPORT  
doi: 10.5937/asn2184295R

## RETKA PREZENTACIJA CEMENTO-OSIFICIRAJUĆEG FIBROMA U MAKSILI: PRIKAZ SLUČAJA

### A RARE PRESENTATION OF CEMENTO-OSSIFYING FIBROMA IN THE MAXILLA: A CASE REPORT

*Santhosh Rajan Packiaraj<sup>1</sup>, Balamurugan Rajendran<sup>2</sup>, Sahana Pushpa Thaneraj<sup>3</sup>*

<sup>1</sup> STOMATOLOŠKA BOLNICA, ORALNA I MAKSILOFACIJALNA HIRURGIJA, RAJAN, ČENAJ, INDIJA

<sup>2</sup> BOLNICA FONDACIJE RYA COSMO, ORALNA I MAKSILOFACIJALNA HIRURGIJA I ORALNA IMPLANTOLOGIJA ČENAJ, INDIJA

<sup>3</sup> UNIVERZITET DR. MGR, ORALNA I MAKSILOFACIJALNA PATOLOGIJA, ČENAJ, INDIJA

<sup>1</sup> RAJAN DENTAL HOSPITAL, ORAL AND MAXILLOFACIAL SURGERY, CHENNAI, INDIA

<sup>2</sup> RYA COSMO FOUNDATION HOSPITAL, ORAL AND MAXILLOFACIAL SURGERY AND ORAL IMPLANTOLOGY, CHENNAI, INDIA

<sup>3</sup> DR. MGR UNIVERSITY, ORAL AND MAXILLOFACIAL PATHOLOGY CHENNAI, INDIA

#### Sažetak

**Osnova problema:** Cemento-osificirajući fibrom je benigna fibro-koštana lezija vilice. Manifestuje se kao spororastući otok, koji može da se povećava progresivno, ukoliko se ne interveniše hirurški. Kada je reč o cemento-osificirajućem fibromu, u upotrebi su različita terminologija i različiti dijagnostički kriterijum za predlaganje strateškog plana njegovog lečenja.

**Metode rada:** Ovaj članak opisuje retku pojavu cemento-osificirajućeg fibroma u gornjoj vilici kod četrdesetčetvorogodišnje pacijentkinje. Klinički prisutna lezija je bila bezbolna i spororastuća. Kompjuterska tomografija otkrila je hipodenzno polje u desnoj posteriornoj regiji maksile veličine 19,07 mm x 27,11 mm. Lezija je hirurški resecirana, u opštoj anesteziji i patohistološki je utvrđeno da se radi o cemento-osificirajućem fibromu.

**Rezultati:** Na vreme se mora obezbediti totalna enukleacija/resekcija koštane lezije kako bi se sprečilo ponovno pojavljivanje ove lezije, i postigla dobra prognoza, što je u opisanom prikazu slučaja i učinjeno. U slučaju ovog pacijenta, koji je praćen 24 meseca, nije prijavljen nijedan recidiv.

**Zaključak:** Iako postoje brojne kontroverze, kada je reč o upotrebi terminologije, multicentrični pristup nalaže da se uspostavi klinička, radiografska i histološka povezanost, kako bi se odredila perspektiva lečenja ovih lezija.

**Ključne reči:** osobe ženskog pola; maksila; spori rast; bezbolnost

#### Abstract

**The basis of the problem:** Cemento-ossifying fibroma is a benign fibro-osseous lesion of the jaw. It presents as a slow growing swelling which progressively enlarges if not surgically intervened. Cemento-ossifying fibroma revolves around the use of different terminologies and diagnostic criteria in proposing a strategic treatment plan.

**Method:** The current article describes a rare occurrence of cement-ossifying fibroma affecting maxilla in a 44 year old female patient. Clinically, the lesion was painless and slow growing in nature. Computed tomography revealed a hypodense area in the right posterior maxilla measuring 19.07mm X 27.11mm. The lesion was surgically resected under general anesthesia and it was histopathologically confirmed to be cemento-ossifying fibroma.

**Results:** Total enucleation/ resection of the osseous lesion must be timely ensured to prevent recurrence and also to achieve good prognosis which was done in the described case report. No recurrence was reported in the present case which had a follow up for 24 months.

**Conclusion:** Although numerous controversies exist in the use of terminologies, a multi centric approach mandates to correlate clinically, radiographically and histologically to determine the treatment perspective.

**Keywords:** female individuals; maxilla; slow growing; painless

#### Corresponding author:

Dr. Balamurugan Rajendran MDS (OMFS), FICOI (USA)  
Oral and Maxillofacial Surgery and Oral Implantology  
RYA COSMO Foundation Hospital 380, Konnur High Road, Otteri,  
India, Tamilnadu - 600012  
E-mail: drbalamurugan.mdsomfs@gmail.com

2021 Faculty of Medicine in Niš. Clinic of Dentistry in Niš.  
All rights reserved / © 2021. Medicinski fakultet Niš. Klinika  
za stomatologiju Niš. Sva prava zadržana.

## Uvod

Cemento-osificirajući fibrom je koštana neoplazma odontogenog porekla, koju je Svetska zdravstvena organizacija (SZO)<sup>1</sup> klasifikovala kao neoplazmu fibro-koštanog tipa. Zastupljenija je kod žena u odnosu na muškarce. Cemento-osificirajući fibrom klinički se manifestuje kao spororastuća masa u donjoj vilici. Veličina lezije nadalje se povećava, kada se uočava u predelima maksile i paranasalnog sinusa<sup>2</sup>.

Radiografski, cemento-osificirajući fibrom pokazuje jasno definisane granice, sa oblastima mešovityh radiolucentnih i rentgenkontrastnih područja, uslovljenih različitim stepenom kalcifikacije. Lezije nezrelog tipa manifestuju se kao radiolucentna područja, dok su zrele lezije označene kao radiopakna polja<sup>3</sup>. Patohistologija otkriva fibrozu stromu vezivnog tkiva sa masom sličnom osteoidu i cementu<sup>4</sup>. Lečenje cemento-osificirajući fibroma povezano je sa spektrom kontroverzi, koje uključuju određivanje dijagnoze i, sa time u vezi, planom terapije. Pristup cemento-osificirajućem fibromu uključuje hiruršku resekciju koštane lezije i kiretažu koštanog ležišta<sup>5</sup>.

## Prikaz slučaja

U ovom prikazu slučaja predstavljamo pacijentkinju staru 44 godine, koja je u poslednjih 6 meseci imala otok na desnoj strani lica. Anamnestički je utvrđeno to da je pre 10 meseci bila podvrgnuta ekstrakciji maksilarnih desnih kutnjaka, zbog parodontopatije. Otok je u početku bio male veličine i postepeno se, tokom vremena, povećavao. Pacijentkinja nije osećala bol, ali je mogla da oseti neku neprijatnost tokom žvakanja. Ekstraoralno, na desnoj strani lica bio je očigledan difuzni otok. Intraoralno, uočen je otok u desnoj maksilarnoj alveoli, u predelu molara (Slika 1). Otok je bio nepravilnog oblika, širio se medijalno do dubine vestibuluma, bočno je dopirao do nepca i pozadi do tubera maksile. Površina otoka bila je glatka. Otok je bio bledoružičaste boje. Prilikom palpacije, otok je bio čvrste konzistencije i nije bio osetljiv na dodir.

Aksijalna kompjuterizovana tomografija otkrila je hipodenzno polje u desnoj maksilarnoj alveoli veličine 19,07 mm x 12,11 mm (Slika 2), koja se proteže medijalno od bukalnog korteksa, ne naslanjajući se na maksilarni sinus, bočno do nepca i posteriorno doseže do gornje vilice. Uočeni su bikortikalna ekspanzija kosti i pomeranje zuba.

## Introduction

Cemento-ossifying fibroma is a bony neoplasm of odontogenic origin which was classified as fibro osseous type by the World Health Organisation (WHO)<sup>1</sup>. It is more prevalent among females than males. Cemento-ossifying fibroma clinically presents as a slow growing mass in the mandible. This size of the lesion further increases when it is seen in the regions of maxilla and paranasal sinus<sup>2</sup>.

Radiographically, cemento-ossifying fibroma shows well-defined borders with areas of mixed radiolucent and radiopaque areas based on the varying degree of calcifications. Immature type of lesions appears as radiolucent areas and mature lesions signify radiopaque areas<sup>3</sup>. Histopathology reveals a fibrous connective tissue stroma with osteoid and cementumlike mass<sup>4</sup>. The management of cemento-ossifying fibroma is surrounded by spectrum of controversies which involves determining the diagnosis and its associated treatment design. Approach to cemento-ossifying fibroma includes surgical resection of the bony lesion and curettage of the bony bed<sup>5</sup>.

## Case report

The present case report depicts a 44 year old female patient who presented with a swelling on the right side of her face for the past 6 months. History revealed that she underwent extraction of her maxillary right molars due to periodontitis 10 months back. The swelling was initially small in size which gradually increased over a period of time. The patient had no pain but she could experience some discomfort while mastication. Extraorally, a diffused swelling was evident on her right side of the face. Intraorally, the swelling was seen in the right maxillary alveolus in the region of molars (Figure 1). The swelling was irregular in shape extending medially till the depth of vestibule, laterally reaching the palate and posteriorly lying close to the maxillary tuberosity. The surface of the swelling was smooth. It was pale pink in colour. On palpation, the swelling was hard in consistency and non-tender.

Axial computed tomography revealed hypodense areas in the right maxillary alveolus measuring 19.07mmX12.11mm(Figure2) that extended medially to buccal cortex not abutting the maxillary sinus, laterally to the palate and posteriorly reaching to the maxillary tuberosity.

Na osnovu gorepomenute kliničke i radiografske interpretacije, slučaj je dijagnostikovao kao cementno-koštana displazija. Planirana je hirurška resekcija koštane lezije, nakon čega bi usledila kiretaža osnovnog koštanog ležišta.

Autori potvrđuju da su dobili pismeni informisani pristanak pacijenata za fotografisanje (slike priložene u ovom prikazu slučaja pripadaju autorima: dr Santhosh Rajan Packiaraj, dr Balamurugan Rajendran i dr Sahana Pushpa Thaneraj) i dobijanje drugih kliničkih informacija, koje će biti objavljene u časopisu, uz obavezu autora da neće objaviti ime i inicijale pacijenta i da će nastojati da se prikrije identitet pacijenta, ali da se njegova anonimnost ne može garantovati.

### ***Hirurška procedura***

Pod nazo-endotrahealnom intubacijom, sprovedena je opšta anestezija. Izvršeno je standardno bojenje i drapiranje. Intraoralno su dati povidon jod i fiziološki rastvor. Rezovi središnjeg grebena, zajedno sa buko lateralnim oslobađajućim rezom postavljeni su da odražavaju režanj pune debljine, kako bi se otkrilo hirurško mesto. Izvršena je ostetomija i koštana lezija je uklonjena u celosti, uz obilnu irigaciju fiziološkim rastvorom (Slika 3). Koštano ležište je kiretirano, nakon čega je urađena periferna ostektomija. Koštane ivice su doterane, a režnjevi su osveženi, kako bi se ponovo približili korišćenjem 4-0 vikrilnih šavova. Na patohistološko ispitivanje poslata su dva uzorka tvrdog tkiva dimenzija 2,5 cm x 1,5 cm i 1 cm x 0,5 cm. Presek obojen hematoksilinom i eozinom pokazao je ostrva koštanog tkiva sa masama sličnim cementu, prekrivenim fibroznom stromom vezivnog tkiva, što ukazuje na cemento-osificirajući fibrom (Slika 4).

### ***Postoperativni ishod***

Nakon operacije, pacijent je pregledan nakon 10 dana, a zatim praćen u 6., 12. i 24. mesecu. Desetog dana praćenja, pacijent je imao minimalan bol i nije bilo znakova otoka i infekcije. Mesto operacije je bilo je zdravo, bez dehiscencije tkiva. Nisu primećeni recidivi lezije u 6., 12. i 24. mesecu praćenja.

Bicortical expansion of bone and displacement of teeth were evident. Based on the above clinical and radiographic interpretation, the case was diagnosed as cemento-osseous dysplasia. A surgical resection of the osseous lesion was planned which was then followed by curettage of the underlying osseous bed.

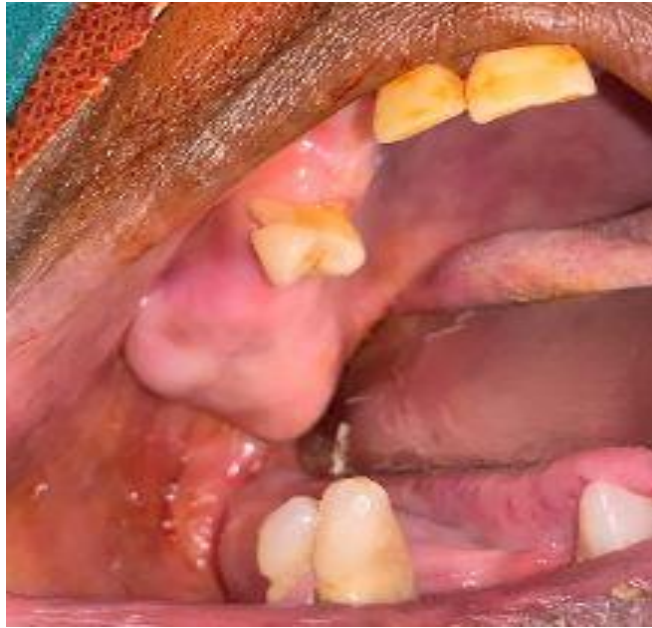The authors certify that they have obtained written informed patient consent for images (the images enclosed in the current case report refers to authors: Dr. Santhosh Rajan Packiaraj, Dr. Balamurugan Rajendran, Dr. Sahana Pushpa Thaneraj) and other clinical information to be reported/published in the journal with an understanding that names and initials will not be published and due efforts will be made to conceal identity, but anonymity cannot be guaranteed.

### ***Surgical procedure***

Under naso-endotracheal intubation, general anesthesia was administered. Standard painting and draping was performed. Povidone iodine and saline wash was given intraorally. Midcrestal incisions along with lateral buccal releasing incision were placed to reflect the full thickness flap in order to expose the surgical site. The osteotomy cuts were placed and the osseous lesion was removed in toto under copious saline irrigation (Figure 3). The underlying bone bed was curetted, following which a peripheral osteotomy was performed. The bony margins were trimmed and the flaps were freshened to approximate it using 4-0 vicryl sutures. Two hard tissue specimens measuring 2.5cm X 1.5cm and 1cm X 0.5cm were sent for histopathological examination. The hematoxylin and eosin stained section showed islands of bony tissue with cementum like masses covered by a fibrous connective tissue stroma suggestive of cemento-ossifying fibroma (Figure 4).

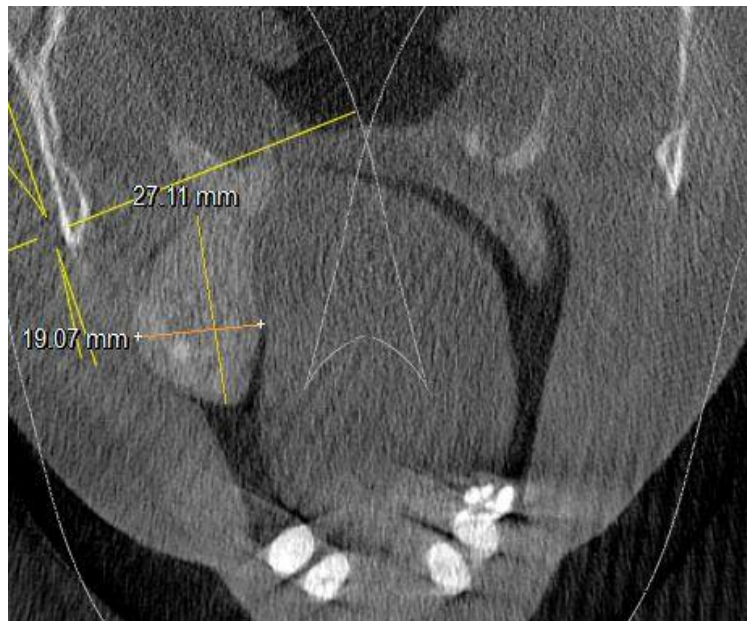### ***Postoperative outcome***

Post-surgery, the patient was reviewed after 10 days and thereafter at 6-, 12- and 24 month follow-up. On the 10th day of follow up the patient had minimal pain and there was no sign of swelling and infection. The surgical site was healthy with no tissue dehiscence. No evidence of recurrence was observed at 6-, 12- and 24- month follow up.



**Slika 1:** Klinička slika pokazuje leziju u desnoj alveoli gornje vilice koja se proteže medijalno do bukalnog korteksa, lateralno do nepca, a posterijorno dostiže do tubera maksile

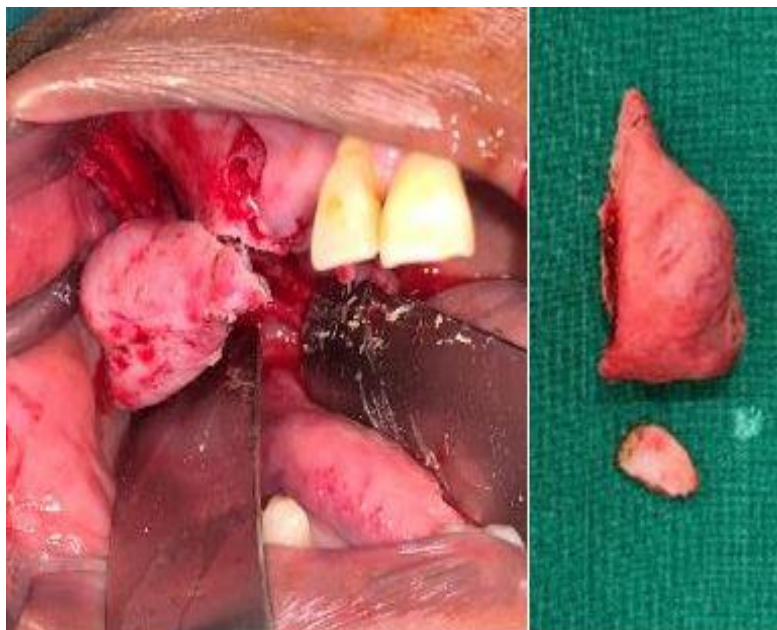
**Figure 1:** Clinical image showing lesion in the right maxillary alveolus extending medially to the buccal cortex, laterally to the palate and posteriorly reaching to the maxillary tuberosity



**Slika 2:** Slika aksijalne kompjuterizovane tomografije pokazuje hipodenzna polja u desnoj alveoli gornje vilice veličine oko 19.07mm X 12.11mm

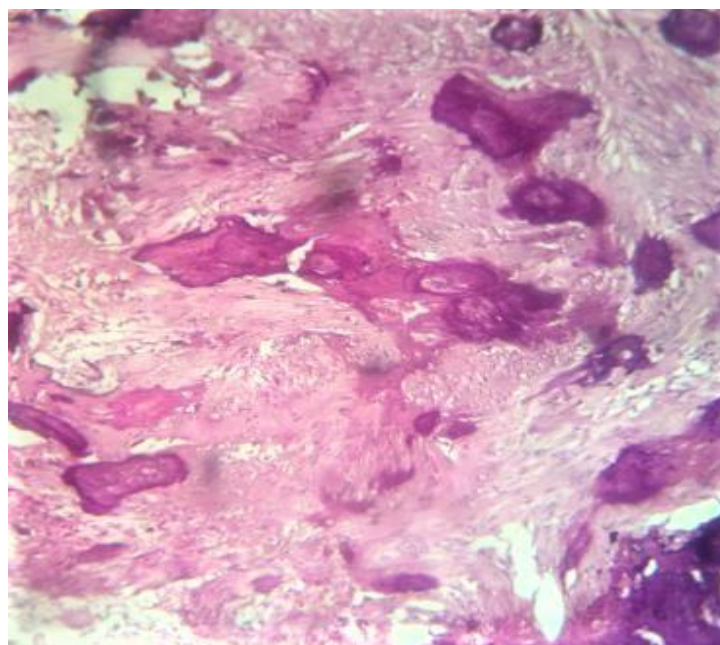
**Figure 2:** Axial computed tomography image showing hypodense areas in the right maxillary alveolus measuring about 19.07mm X 12.11mm





**Slika 3:** Lezija u gornjoj desnoj alveoli je hirurški osteotomizovana i potpuno resektovana iz koštanog ležišta. Dobijena su dva tvrdotkivna uzorka: jedan veliki dimenzija 2,5 cm X 1,5 cm i drugi mali tvrdotkivni uzorak dimenzija 1 cm X 0,5 cm

**Figure 3:** The lesion in the maxillary right alveolus was surgically osteotomized and resected completely from the underlying osseous bed. Two hard tissue specimens were obtained: one large hard tissue measured 2.5cm X 1.5cm and other small hard tissue measured 1cm X 0.5cm



**Slika 4:** Presek obojen hematoksilinom i eozinom koji pokazuje kalcifikovanu masu sličnu cementu okruženu fibroznom vezivno-tkivnom stromom

**Figure 4:** Hematoxylin and eosin stained section showing cementum like calcified mass surrounded by fibrous connective tissue stroma

## Diskusija

Cemento-osificirajući fibrom, u mandibuli, prvi je opisao Menzel 1872. godine. Kasnije, SZO 1971. godine počinje da smatra cemento-osificirajući fibrom lezijom koja formira cement. SZO je 2005. godine redefinisala termin „cemento-osificirajući fibrom“ kao „osificirajući fibrom“. Cemento-osificirajući fibrom manifestuje se u dve različite varijante: centralna varijanta je neoplastični oblik i razvija se iz parodonticijuma, dok je periferna varijanta neneoplastični oblik, koji nastaje iz mekih tkiva vilice<sup>3</sup>.

Cemento-osificirajući fibrom počinje kao spororastuća lezija, koja se pretežno javlja kod osoba starosti 30 do 50 godina života. Lezija se češće javlja kod žena i odnos učestalost lezija kod muškaraca u odnosu na žene kreće se od 2 : 17 do 5 : 1111. Generalno, kod osoba kod kojih se javlja, cemento-osificirajući fibrom je u ranim fazama pojave asimptomatski. U uznapredovalim stadijumima, lezija se postepeno povećava, što rezultira ekspanzijom kortikalne kosti, pomeranjem zuba i deformacijom lica<sup>5</sup>. Kod dece, lezija se naziva juvenilni cemento-osificirajući fibrom, koji je agresivan i visoko vaskularan. Etiologija je nepoznata, ali trauma, odnosno vađenje zuba mogu biti predisponirajući reaktivni uzroci, koji mogu dovesti do cemento-osificirajućeg fibroma. Razlog za takav uzrok je to što nakon vađenja zuba neki deo parodontalnog ligamenta ostaje vezan za alveolarnu kost, koja nakon stimulacije taloži cement.

Radiografske šablone cemento-osificirajućeg fibroma opisali su Eversole i sar<sup>6</sup>. U početnim fazama, lezija se karakteriše kao unilokularna ili multilokularna radiolucencija. Kako lezija sazreva, evidentna je mešovita oblast žarišta sa dobrodefinisanim radiolucencijom i raštrkanim rentgenkontrastnih poljima. Sklerotični obod radiolucenčnih područja nastaje perifernom kondenzacijom kosti, koja proširuje korteks, bez ikakve perforacije, dovodeći do resorpcije zuba i divergencije korena<sup>5</sup>. Ponekad je moguća i ujednačena ekspanzija kortikalne kosti, koja pokazuje karakterističan centrifugalni obrazac, značajan kriterijum za dijagnozu cemento-osificirajućeg fibroma.

Waldron i sar.<sup>7</sup> izvestili su o tome da je 26% slučajeva pokazalo radiolucenčne oblasti, 63% slučajeva pokazalo je mešovite radiolucenčne i rentgenkontrastnih oblasti, dok je 12% slučajeva imalo homogenu formu. Suprotno tome, Titinchi et al.<sup>8</sup> pokazali su radiopakna područja u 49,2% slučajeva,

## Discussion

Cemento-ossifying fibroma was at first described by Menzel in 1872 in mandible. Later WHO in 1971 considered cemento-ossifying fibroma as cementum forming lesion. In 2005, WHO redefined the terminology of “cemento-ossifying fibroma” as “ossifying fibroma”. Cemento-ossifying fibroma presents itself in two different variants: the central variant is a neoplastic form and develops from the periodontium while the peripheral variant is a non-neoplastic form which arises from the soft tissues of the jaws<sup>3</sup>.

Cemento-ossifying fibroma initiates as a slow growing lesion which predominantly affects individuals between 30 and 50 years old. The lesion has female predilection and the male to female ratio ranges from 2:17 to 5:1111. Generally, the individuals are asymptomatic in the early stages of the occurrence of cemento-ossifying fibroma. In advanced stages, the lesion gradually enlarges resulting in expansion of cortical bone, displacement of teeth and facial disfigurement<sup>5</sup>. In children, the lesion is termed as juvenile cemento-ossifying fibroma which is aggressive and is highly vascular. The etiology is unknown however trauma/tooth extractions could be a predisposing reactive cause that can lead to cemento ossifying fibroma. The reason for such cause is that, after a dental extraction some portion of the periodontal ligament remains attached to the alveolar bone which upon stimulation deposits cementum.

The radiographic patterns of cemento-ossifying fibroma were described by Eversole et al<sup>6</sup>. During initial stages, the lesion presents as unilocular or multilocular radiolucency. As the lesion matures, a mixed area of foci is evident with well-defined radiolucency and scattered radio-opacities. The sclerotic rimming of radiolucent areas are formed by the peripheral condensation of the bone which expands the cortex without any perforation causing resorption of tooth and root divergence<sup>5</sup>. At times, uniform expansion of the cortical bone is also possible showing a characteristic centrifugal pattern, a significant criteria for diagnosing cemento-ossifying fibroma.

Waldron et al<sup>7</sup>, reported that 26% of cases showed radiolucent areas, 63% of cases showed mixed radiolucent and radiopaque areas and 12% cases had homogenous form. On the contrary, Titinchi et al<sup>8</sup>, demonstrated radiopaque areas in 49.2% of cases, mixed form in 34.9% of cases and only 15.9% cases had radiolucent areas.

mešovitu formu u 34,9% slučajeva i samo 15,9% slučajeva imalo je radiolucetna područja.

Na osnovu obrasca perifernog oboda, Barberi i sar.<sup>9</sup>, opisali su je kao dobrodefinisane leziju, bez sklerotičnih granica u 40% slučajeva, dobrodefinisane leziju sa sklerotskim obodom u 45% slučajeva i 15% slučajeva pokazalo je loše definisane granice.

Postoje razlike u dijagnozi i proceni cemento-osificirajućeg fibroma, jer ga je teško histološki razlikovati od osteoida i cementa<sup>2</sup>. Cemento-osificirajući fibrom manifestuje se kao fibrovaskularna stroma vezivnog tkiva sa kalcifikacijama. Preseci bojeni hematoxilinom i eozinom pokazuju fragmente bazofilnih kalcifikacija, koji ukazuju na nezreli cement, što sugerise na centralni cemento-osificirajući fibrom, dok je presek hematoxilina i eozina, koji pokazuje kalcifikovane fragmente sa eozinofilnim osteoidom značajan za centralni osificirajući fibrom. Kako bi se prevazišle ove razlike, Endo i sar.<sup>10</sup> analizirali su upotrebu keratin-sulfata i hondroitin-4-sulfata na tri različite lezije i to cemento-osificirajući fibrom, osificirajući fibrom i fibrozne displazije, kroz imunohistohemijsku procenu. Njihove studije ističu da je keratin-sulfat pokazao imunu reaktivnost za cemento-osificirajući fibrom, dok je hondroitin-4-sulfat značajan za osificirajući fibrom i fibrozne displazije.

Preporučeni tretman cemento-osificirajućeg fibroma je enukleacija, kada je lezija mala, dok bi kod velikih ekspanzivnih lezija poželjna bila hirurška resekcija lezije, praćena rekonstrukcijom kosti<sup>4</sup>. U ovom slučaju, zbog velikog obima, autori su izvršili hiruršku resekciju prisutne lezije. Čak iako veličina i obim lezije mogu da variraju, mora se obezbediti potpuna hirurška enukleacija lezije, praćena kiretažom osnovnog koštanog ležišta. Prognoza cemento-osificirajućeg fibroma je dobra ali je utvrđena visoka stopa recidiva u maksili, u poređenju sa stopom recidiva u mandibuli. U slučaju ovog pacijenta, koji je praćen 24 meseca, nije prijavljen nijedan recidiv. Bala i sar.<sup>1</sup> prijavili su prosečni recidiv od 10,1% tokom perioda praćenja od 25 meseci. Liu i sar.<sup>11</sup> primetili su recidiv od 27,2% za 7 godina, a Eversole i sar.<sup>6</sup> prijavili su recidiva od 28% za period praćenja od 38 meseci.

Based on the peripheral rimming pattern, Barberi et al<sup>9</sup>, described as well-defined lesion without sclerotic borders in 40% of cases, well-defined lesion with sclerotic rim in 45% of cases and 15% of cases showed ill-defined borders.

Differences in the diagnosis exist in evaluating cemento-ossifying fibroma as it is difficult to distinguish osteoid and cementum histologically<sup>2</sup>. Cemento-ossifying fibroma presents as fibrovascular connective tissue stroma with calcifications. Hematoxylin and eosin section showing fragments of basophilic calcifications indicating immature cementum suggestive of central cemento-ossifying fibroma while, hematoxylin and eosin section showing calcified fragments with eosinophilic osteoid is significant of central ossifying fibroma. In order to overcome these differences, Endo et al<sup>10</sup> assessed the use of keratin sulphate and chondroitin-4-sulphate on three different lesions namely cemento-ossifying fibroma, ossifying fibroma and fibrous dysplasia through immunohistochemical evaluation. Its studies report that keratin sulphate showed immune reactivity for cemento-ossifying fibroma while chondroitin-4-sulphate was significant for ossifying fibroma and fibrous dysplasia.

The recommended treatment for cemento-ossifying fibroma is enucleation when the lesion is small and surgical resection followed by reconstruction of bone can be preferred at large expansile lesions<sup>4</sup>. In the present case, the authors have performed surgical resection since the extent of the lesion was large. Even if the size and the extent of the lesion may vary, a complete surgical enucleation followed by curettage of the underlying osseous bed must be ensured. The prognosis of the cemento-ossifying fibroma is fair and the rate of recurrence is found to be high in maxilla when compared to mandible. No recurrence was reported in the present case which had a follow up for 24 months. Whereas Bala et al<sup>1</sup>, reported average recurrence of 10.1% for a follow up period of 25 months, Liu et al<sup>11</sup> observed recurrence of 27.2% in 7 years and Eversole et al<sup>6</sup> reported 28% recurrence in 38 months.

## ***Zaključak***

Cemento-osificirajući fibrom u maksili retka je zastupljen, u poređenju sa njegovom prevalencijom u mandibuli. Iako postoje brojne kontroverze, kada je reč o upotrebi terminologije, multicentrični pristup nalaže da se uspostavi klinička, radiografska i histološka povezanost, kako bi se odredila perspektiva lečenja. Na vreme se mora obezbediti totalna enukleacija/resekcija koštane lezije kako bi se sprečilo ponovno pojavljivanje ove lezije, i postigla dobra prognoza.

### ***Sukob interesa:***

Autori izjavljuju da nemaju sukob interesa.

## ***Conclusion***

Cemento-ossifying fibroma in maxilla is a rare presentation when compared to its prevalence in mandible. Although numerous controversies exist in the use of terminologies, a multi centric approach mandates to correlate clinically, radiographically and histologically to determine the treatment perspective. Total enucleation/ resection of the osseous lesion must be timely ensured to prevent recurrence and also to achieve good prognosis.

### ***Conflict of interest:***

The authors declare that they have no conflict of interest



## LITERATURA /REFERENCES

1. Bala TK, Soni S, Dayal P, Ghosh I. Cemento-ossifying fibroma of the mandible. A clinicopathological report. *Saudi Med J* 2017; 38 (5): 541-5.
2. Prakash R, Shahid MS, Raj H, Anil KS. Cemento Ossifying Fibroma: A Pathological Entity *J Carcinog Mutagen* 2021; 12:359.
3. Mohapatra M, Banushree CS, Nagarajan K, Pati D. Cemento-ossifying fibroma of mandible: An unusual case report and review of literature. *J Oral Maxillofac Pathol* 2015; 19:405.
4. Mahato B, Mandal S, Ray JG, Chaudhuri K. Central cemento-ossifying fibroma: a case report. *MOJ Clin Med Case Rep* 2015; 3(2):214-6.
5. Rangil JS, Silvestre FJ, Bernal JR. Cemento-ossifying fibroma of the mandible: Presentation of a case and review of the literature. *J Clin Exp Dent* 2011; 3(1):e66-9.
6. Eversole LR, Leider AS, Nelson K. Ossifying fibroma: a clinicopathologic study of sixty-four cases. *Oral Surg Oral Med Oral Pathol* 1985; 60: 505-11.
7. Waldron CA, Giansanti JS. Benign fibro-osseous lesions of the jaws: a clinical-radiologic-histologic review of sixty-five cases. *Oral Surg* 1973; 35: 340-50.
8. Titinchi F, Morkel J. Ossifying Fibroma: Analysis of treatment methods and recurrence patterns. *J Oral Maxillofac Surg* 2016; 24
9. Barberi A, Cappabianca S, Collela G. Bilateral cement-ossifying fibroma of the maxillary sinus. *Br J Radiol* 2003; 76: 279-80.
10. Endo Y, Uzawa K, Mochida Y, Nakatsuru M, Shiiba M, Yokoe H et al. Differential distribution of glycosaminoglycans in human cementifying fibroma and fibro-osseous lesions. *Oral Dis* 2003; 9: 73-6.
11. Liu Y, Wang H, You M, Yang Z, Miao J, Shimizutani K et al. Ossifying fibromas of the jaw bone: 20 cases. *Dentomaxillofac Radiol* 2010; 39: 57-63.