

Primljen / Received on: 12.08.2021.
Revidiran / Revised on: 13.10.2021.
Prihvaćen / Accepted on: 24.11.2021.

PRIKAZ SLUČAJA
CASE REPORT
doi: 10.5937/asn2285389P

MOGUĆI EFEKTI HIPERPARATIROIDIZMA NA GUBITAK OSEOINTEGRACIJE ZUBNIH IMPLANTATA: PRIKAZ SLUČAJA

POSSIBLE EFFECTS OF HYPERPARATHYROIDISM IN THE LOSS OF OSSEOINTEGRATION OF DENTAL IMPLANTS: A CASE REPORT

Giulia Petroni¹, Lukas Jonathan Brodacz¹, Alfredo Passaretti², Alessio Zanza¹, Luca Testarelli¹,
Andrea Cicconetti¹

¹ SAPIENZA UNIVERZITET U RIMU, DEPARTMAN ZA ORALNE I MAKSILOFACIJALNE NAUKE, RIM, ITALIJA
² PRIVATNA STOMATOLOŠKA ORDINACIJA, RIM, ITALIJA

¹ SAPIENZA UNIVERSITY OF ROME, DEPARTMENT OF ORAL AND MAXILLO-FACIAL SCIENCES, ROME, ITALY
² PRIVATE DENTAL PRACTICE, ROME, ITALY

Sažetak

Uvod: Hiperparatiroidizam (HPT) je čest endokrini poremećaj sa potencijalnim komplikacijama, vezanim za skeletni, bubrežni, neurokognitivni i kardiovaskularni sistem. Njegova povezanost sa nedostatkom oseointegracije zubnih implantata nije opisana u medicinskoj literaturi.

Prikaz slučaja: Ovaj prikaz slučaja ima za cilj diskusiju o dva slučaja gubitka zubnih implantata, zbog visokog nivoa parathormona (PTH), uz odsustvo bilo kog drugog sistemskog ili lokalnog komorbiditeta, što ukazuje na moguću korelaciju između HPT i odbacivanja implantata. Oba pacijenta upućena su na Kliniku sa žalbama na protetske komplikacije, upalu gingive i pokretljivost zubne proteze. Nakon procene Cone-Beam kompjuterizovanom tomografijom, svi implantati oba pacijenta su uklonjeni, zbog odbacivanja nastalog usled periimplantitisa, a zatim su četiri implantata umetnuta pacijentu i pet implantata pacijentu 2. Kod oba pacijenta korišćeni su kratki implantati (Bicon LLC, Boston, Massachusetts, USA), prečnika 4 mm i visine 5 mm i napravljene su protezne podstrukture od Trinia® (Bicon LLC, Boston, Massachusetts, SAD). U petoj godini posle ugradnje, pacijenti su prijavili komplikacije i neuspeh implantacije. Da bi se utvrdili uzroci nespuha, pacijenti su morali da urade test krvi kako bi procenili metabolizam kostiju i posebno da bi se procenili nivoi paratiroidnog hormona (PTH), kalcijuma i vitamina D.

Rezultati: Rezultati analize krvi pokazali su kod oba pacijenta normalnu kalcemiju, nedostatak vitamina D i povišen nivo PTH. Posle konsultacije endokrinologa, dijagnostikovano je sekundarni hiperparatiroidizam.

Zaključak: Sasvim je logično pretpostaviti da gubitak oseointegracije dentalnih implantata može biti u korelaciji sa efektima HPT.

Ključne reči: zubni implantati; hiperparatiroidizam; implantologija; osteointegracija; parathormon.

Corresponding author:

Alessio Zanza DDM,
Prof Luca Testarelli, D.M.D, PhD
Department of Oral and Maxillo-Facial
Sciences, Sapienza University of Rome,
Viale Regina Elena 287a, 00161 Rome, Italy
e-mail.alessio.zanza@uniroma1.it
e-mail.luca.testarelli@uniroma1.it

Abstract

Background: Hyperparathyroidism (HPT) is a common endocrine disorder with potential complications on the skeletal, renal, neurocognitive and cardiovascular systems. Its association with the lack of osseointegration of dental implants has not been described in the medical literature.

Case presentation: This case report aims to discuss two cases of dental implant loss in which a high level of parathormone (PTH) was found in the absence of any other systemic or local comorbidity, suggesting the possible correlation between HPT and implant. Both patients were referred to the clinic complaining about prosthetic complications, gingival inflammation and mobility of the dental prosthesis. After a Cone-Beam computed Tomography evaluation, all implants of both patients were removed for rejection arising from periimplantitis and then four implants were inserted in the patient 1 and five implants in the patient 2. For both patients short implants (Bicon LLC, Boston, Massachusetts, USA), featured by 4 mm in diameter and 5 mm in height, were used and the prosthesis substructure was made of Trinia® (Bicon LLC, Boston, Massachusetts, USA). During the fifth year, the patients reported complications and the implant treatment failure. In order to establish the causes of failure, a thorough investigation was performed. Since no causes were detected, the patients were required to perform a blood test to evaluate bone metabolism and specifically to assess parathyroid-hormone levels (PTH), calcium levels and vitamin D.

Results: The results of the blood tests showed normal calcemia, vitamin D deficiency and elevated PTH levels in both patients. After an endocrinologist's consultation, secondary hyperparathyroidism was diagnosed.

Conclusion: It is reasonable to assume that the loss of osseointegration of dental implants can be correlated with the effects of HPT.

Key words: dental implants, hyperparathyroidism, implantology, osseointegration, parathormone

2022 Faculty of Medicine in Niš. Clinic of Dental Medicine Niš. All rights reserved / © 2022. Medicinski fakultet Niš. Klinika za dentalnu medicinu Niš. Sva prava zadržana.

Uvod

Stopa uspeha ugradnje implantata je 90% do 95%. Iako je postao tretman izbora, komplikacije koje nastaju ugradnjom zubnih implantata i dalje su jedan od najvećih izazova za stomatologe¹. Kontinuirano kliničko iskustvo ugazuje na mogućnost da nova sistemska stanja mogu biti povezana sa rizikom od odbacivanja zubnih implantata, kao što je npr. hiperparatiroidizam (HPT). Štaviše, medicinska literatura jedva da izveštava o povezanosti između HPT i odbacivanja zubnih implantata. U stvari, unošenjem ključnih reči na PubMed-u [„hiper-paratiroidizam“ i „neuspeh zubnog implantata“] dobija se samo jedan rezultat².

Uloga parathormona (PTH) u našem telu dobro je poznata: PTH je ključni regulator homeostaze kalcijuma i igra suštinsku ulogu u metabolizmu kostiju^{3,4,5}. HPT, čak i u svom "asimptomatskom" obliku, povezan je sa potencijalnim morbiditetima, uključujući smanjenu gustinu kortikalne kosti⁶.

Rai i saradnici proučavali su oromandibularne efekte primarnog HPT⁷, što je sistemska hiperkalcemijska bolest, kod koje su gubitak lamine dure, izgled poput brušenog stakla i smanjenje širine donje vilice uobičajeni nalazi⁷.

Sekundarni hiperparatiroidizam je česta komplikacija oboljenja bubrega. Kod hronične bolesti bubrega dolazi do zadržavanja fosfata, smanjene bubrežne sinteze aktivnog vitamina D (kalcitriola), sa rezultujućom hipokalcemijom i sekundarnim hiperparatiroidizmom. Ako se ne leči, dolazi do pojave osteodistrofije (*osteitis fibrosa cystica*)^{2,8}.

Zbog toga je velika verovatnoća da bi neravnoteža u nivou PTH-a mogla izazvati promene u kostima, što može usloviti i odbacivanje implantata.

Ovaj prikaz slučaja ima za cilj da otkrije sistematska stanja, poput hiper-paratiroidoze, koja mogu direktno da doprinesu odbacivanja implantata, a koja još uvek nisu uključena među faktore rizika koji se procenjuju u preoperativnoj i postoperativnoj fazi.

Materijali i metode

2.1. Prikaz slučaja

U 2019. godini dva pacijenta upućena su na dalje zbrinjavanje na Odeljenje za oralnu hirurgiju UOC, Stomatološke klinike, "Sapijenca" Univerziteta u Rimu, Italija, a koja su prethodno rehabilitovana fiksnom protezom, sa punim zubnim lukom fiksiranim na donjim lukovima sa četiri implantata (Pacijent 1) odnosno pet implantata (Pacijent 2).

Introduction

The success rate of implants is reported to be 90%–95%. Although it has become the treatment of choice, the complications arising from dental implant placement are still one of the biggest challenges for dentists¹. In continuous clinical experience, there is a possibility that new systemic conditions may be associated with a risk of failure of dental implants, such as hyperparathyroidism (HPT). Moreover, the medical literature barely reports the association between HPT and dental implants failure. In fact, the search of the PubMed by entering the keywords ["hyperparathyroidism" and "dental implant failure"] returned only one result².

The role of parathormone (PTH) within our body is well known: PTH is a crucial regulator of calcium homeostasis and plays an essential role in bone metabolism^{3,4,5}. HPT, even in its "asymptomatic" form, is associated with potential morbidities, including decreased cortical bone density⁶.

Rai et al. studied the oromandibular effects of primary HPT⁷, which is a systemic hypercalcemic disease where loss of lamina dura, ground glass appearance, and mandibular cortical width reduction are common findings⁷.

Secondary hyperparathyroidism is a frequent complication of kidney diseases. With chronic kidney disease there is phosphate retention, decreased renal synthesis of active vitamin D (calcitriol) with resultant hypocalcemia and secondary hyperparathyroidism. If untreated, osteodystrophy (*osteitis fibrosa cystica*) develops^{2,8}.

It is therefore highly probable that an imbalance in PTH could cause bone alterations, which could lead then to implant failure.

This case report aims to bring to light systematic conditions, such as hyperparathyroidism, which may contribute directly to implant failure and which have not yet been included among the risk factors to be assessed in the pre- and post-operative phases.

Materials and Methods

2.1. Cases Presentation

In 2019, two patients in care at the UOC Oral Surgery Department of Dental Sciences, Dental Clinic "Sapienza" University of Rome (Italy), and previously rehabilitated with a full arch cement-retained fixed prosthesis on four implants (Patient 1) and five implants (Patient 2) at the lower arch, were referred to our clinic for further management of prosthetic complications.

Pacijenti su rehabilitovani fiksnom protezom pričvršćenom cementom, sa punim lukom, po istom hirurškom i protetskom protokolu, 2014. godine.

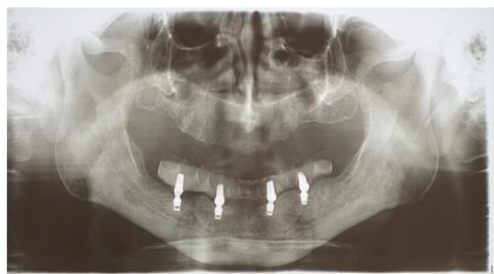Kod oba pacijenta ugrađeni su kratki implantati (Bicon LLC, Boston, Massachusetts, SAD), prečnika 4 mm i visine 5 mm. Implantat karakteriše plato dizajn, čista konusna veza, koso rame, hemisferni profil uporišta i površinska obrada kalcijum-fosfatom. Implantati i abatmenti sistema napravljeni su od legure titanijuma Ti6Al4V. Podstruktura proteze izrađena je od Trinia® (Bicon LLC, Boston, Massachusetts, SAD). Podkonstrukciju upotpunili su zubi proteze od kompozitnog materijala.

Pacijent 1

Muškarac star 71 godinu požalio se na pokretljivost proteze i nemogućnost žvakanja hrane. Kliničkim pregledom uočena je upala gingive i klinička pokretljivost proteze. CBCT otkrivena je radiolucencija svojstvenu periimplantatu lokalizovanu na svim implantima (Slika 3). S obzirom na lokalne uslove, uklonili smo sve implantate i protezu zbog ekstremne pokretljivosti nosača.

Pacijent 2

Žena stara 70 godina javila se na kliniku zbog krvarenje gingive, pokretljivosti proteze i bola tokom žvakanja. Kliničkim pregledom uočeni su upala gingive i lokalni bol. Ortodontomografijom otkrivena je periimplantna radiolucencija, lokalizovana na implantatima postavljenim na mestima 33 i 41. Nastavili smo sa uklanjanjem proteze (implantat na mestu 41 sam je ispao tokom ove procedure; videti Sliku 4) i zabeležili kliničku pokretljivost dva implantata. Imajući u vidu lokalne uslove, uklonili smo dva implantata postavljena na mestima 33 i 42 (Slika 5) i ponovo prilagodili postojeći okvir lokalnim uslovima. Ostala tri implantata (43, 45 i 35) popustila su u narednim mesecima.



Slika 1. Pacijent 1: četvorogodišnje praćenje
Figure 1. Patient 1, four-year follow-up

The patients were rehabilitated with a full arch cement-retained fixed prosthesis, by the same surgical and prosthesis protocol, in 2014.

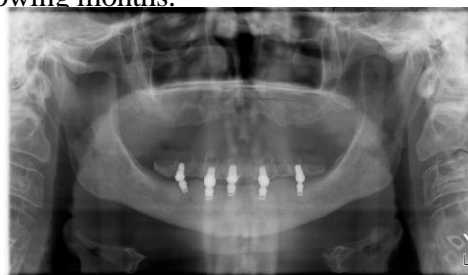Both patients received short implants (Bicon LLC, Boston, Massachusetts, USA), featured by 4 mm in diameter and 5 mm in height. The implant is characterized by a plateau design, a pure locking taper connection, sloping shoulder, abutment hemispheric profile and calcium phosphate surface treatment. The implants and abutments of the system are made of the titanium alloy Ti6Al4V. The prosthesis substructure was made of Trinia® (Bicon LLC, Boston, Massachusetts, USA). The substructure was completed by denture teeth made of composite material.

Patient 1

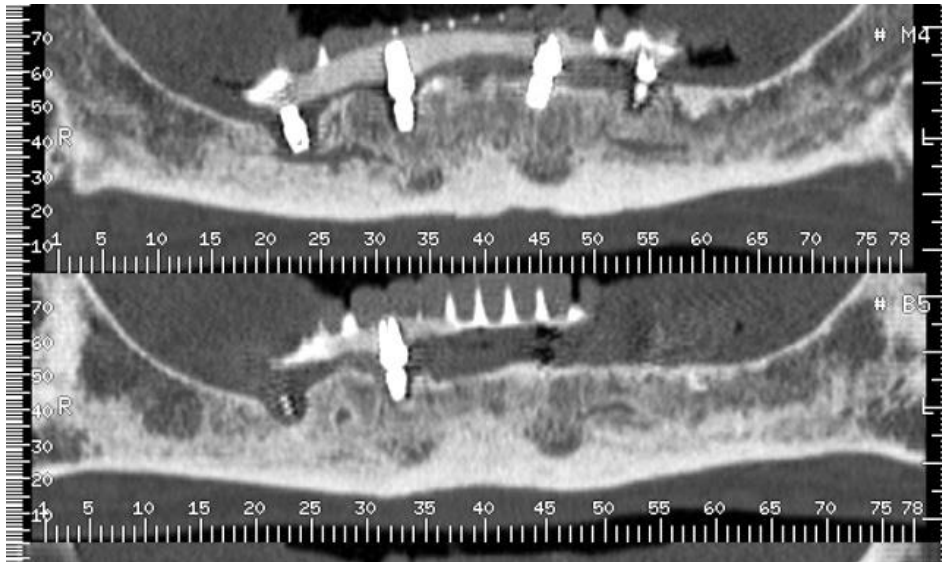
A 71-year-old man complained about prosthesis mobility and the impossibility of food chewing. By clinical examination, we detected gingival inflammation and clinical mobility of the prosthesis. The CBCT revealed a peri-implant radiolucency localized to all fixtures (Figure 3). Considering the local conditions, we removed all implants and the prosthesis due to the extreme mobility of the fixtures.

Patient 2

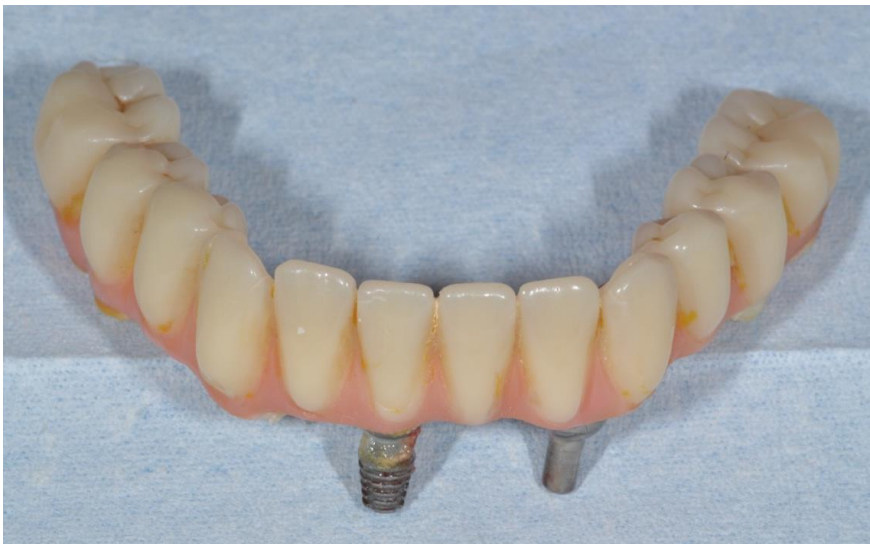A 70-year-old woman presented with gingival bleeding, prosthesis mobility and pain during the mastication. By clinical examination, we detected gingival inflammation and local pain. The orthopantomography revealed a peri-implant radiolucency localized to the implants placed in sites 3.3 and 4.1. We proceeded to remove the prosthesis (the implant in site 4.1 removed itself during this procedure, see Figure 4) and recorded the clinical mobility of the two implants. Considering the local conditions, we removed the two implants placed in sites 3.3 and 4.2 (Figure 5) and readapted the existing framework to local conditions. Other three implants (4.3, 4.5 and 3.5) failed in the following months.



Slika 2. Pacijent 2: petogodišnje praćenje
Figure 2. Patient 2, four-year follow-up



Slika 3. Pacijent 1: petogodišnje praćenje
Figure 3. Patient 1, five-year follow-up



Slika 4. Pacijent 2: Klinička fotografija kompletno uklonjene proteze sa pričvršćenim neuspelim implantom
Figure 4. Patient 2, clinical photo of the prosthesis removed in its entirety, with the failed implant attached

2.2. Hirurški protokoli

Operacija je uključivala ugradnju četiri implantata (Pacijent 1) i pet (Pacijent 2) kratkih imlantanata, respektivno.

Sledeće, navedene, procedure sprovedene su kod oba pacijenta.

Nakon lokalne anestezije mepivakainom sa adrenalinom, korišćenjem skalpelnog sečiva Bard Parker #15, urađen je režanj pune debljine; krov reznja podignut je i održavan Langenbeck retraktorom.

Osteotomija na mestu implantata izvedena je upotrebom prvog pilot borera (prečnika 2 mm) koji radi pod vodenim hlađenjem pri konstantnoj brzini od 10000

2.2. Surgical Protocols

The surgery involved the insertion of four (patient 1) and five (patient 2) short implants.

The following procedures were performed in both patients.

After local anesthesia with mepivacaine with adrenaline, using a Bard-Parker #15 scalped blade, a full thickness flap was performed; the flap was raised and maintained with a Langenbeck retractor.

The implant site osteotomy was performed using a first pilot drill (2 mm diameter) working under irrigation at a constant speed of 10.000 rpm, followed by

o/min, a zatim četiri atraumatska borera (prečnika 2,5 mm, 3 mm, 3,5 mm i 4 mm) koji se rotiraju brzinom od 50 o/min, bez vodenog mlaza. Veličina poslednjeg zavrtnja bila je jednaka veličini implantata i implantat je postavljen pod pritiskom, linija do linije, od 1 mm do 3 mm ispod kosti. Urađen je šav sa Vicryl 3.0. Postoperativno propisani su amoksicilin 1 g dva puta dnevno tokom šest dana i ibuprofen 600 mg dva puta dnevno tokom dva dana.

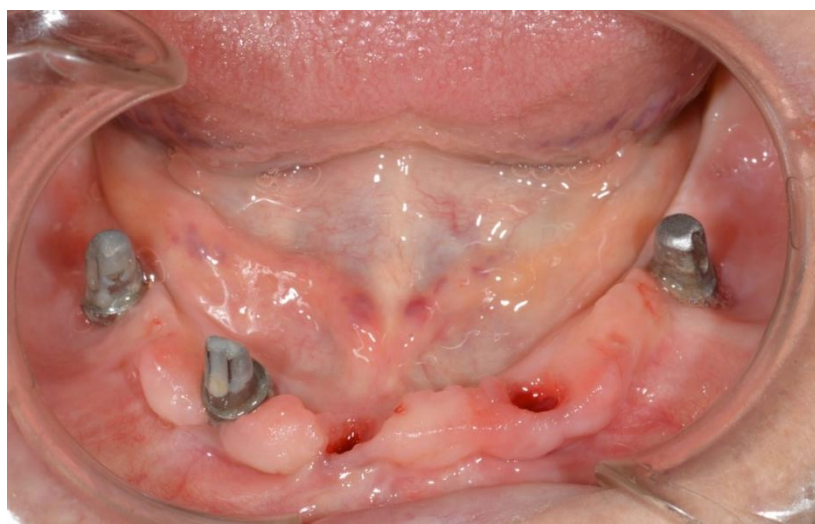2.3. Protetski protokol

Nakon tri meseca implantati su hirurški otkriveni i postavljene su kapice za zarastanje. Dve nedelje kasnije uzet je otisak sa implantima i zuba antagonista. Proteza je cementirana upotrebom privremenog sredstva za cementiranje (Temp Bond NE, Kerr). Zatim je izvršena kontrola okluzije.

four atraumatic drills (diameter 2,5-3-3,5-4 mm) rotating at a speed of 50 rpm, without irrigation. The size of the last reamer was equal to the size of the implant and the implant was placed under pressure, line to line, from 1 to 3 mm below the bone. Suture with Vicryl 3.0 was performed. Amoxicillin 1 g twice daily for six days, and ibuprofen 600 mg twice daily for two days were prescribed as postoperative therapy.

2.3. Prosthetic protocol

After three months, implants were surgically exposed and the healing abutments were applied. Two weeks later, a full arch polyvinyl siloxane impression of the implants and the opposing teeth was taken. The prosthesis was cemented using a temporary luting agent (Temp Bond NE, Kerr). Then, the control of the occlusion was performed.



Slika 5. Pacijent 2: Klinička fotografija dobijena tokom uklanjanja implantata
Figure 5. Patient 2, Clinical photo obtained during implant removals

2.4. Praćenje

Kontrolne posete su bile zakazivane jednom godišnje nakon proteziranja pacijenata, na Odeljenju za oralnu hirurgiju UOC, Stomatološke klinike „Sapijenca“ Univerziteta u Rimu (Italija).

Tokom prve četiri godine klinička i radiografska kontrola nije pokazala komplikacije. Radili smo panoramski rendgenski snimak tokom četvorogodišnjeg praćenja (Slika 1 i Slika 2).

Tokom pete godine pacijenti su prijavili komplikacije.

2.4. Follow-up

Follow-up visits were scheduled every year after prosthetic loading, at the UOC Oral Surgery Department of Dental Sciences, Dental Clinic “Sapienza” at the University of Rome (Italy).

During the first four years, a clinical and radiographic check showed no complications. We reported the panoramic x-ray at four-year follow-up (Figure 1 and Figure 2).

During the fifth year, the patients reported complications.

Što se tiče mogućih uzroka ova dva slučaja neuspjeha, razmatrali smo različite moguće faktore. Oba pacijenta su pregledana na bilo kakve sistemske i lokalne kontraindikacije za rehabilitaciju pre lečenja. Krvni testovi (krvna slika, glukoza u krvi, PT, PTT, INR) i kardiološka procena nisu pokazali nikakve kontraindikacije. Farmakološki tretman dva pacijenta nije bio povezan sa odbacivanjem implantata. Tokom posmatranog perioda nisu zabeležene sistemske promene u zdravlju, a takođe nisu prijavljene promene u farmakološkoj terapiji. Tokom godišnjeg praćenja otkrili smo da nijedna lokalna promena nije mogla da dovede do odbacivanja implantata. Okluzalno preopterećenje je već isključeno zbog toga kompletnog uklanjanja proteze sa suprotnog luka.

Zbog toga, od pacijenata smo zahtevali da urade test krvi da bi procenili metabolizam kostiju i posebno da bi procenili nivoe paratiroidnog hormona (PTH), kalcijuma i vitamina D.

Podaci testova krvi nisu bili u granicama normale. Rezultati pokazuju normalnu kalcemiju, nedostatak vitamina D i povišen nivo PTH.

Pacijente smo uputili endokrinologu koji je kod oba pacijenta dijagnostikovao sekundarni hiperparatiroidizam.

Diskusija

Sekundarni hiperparatiroidizam je sistemska bolest koja uzrokuje gubitak koštane mase. Ovo stanje se može javiti kod nedostatka vitamina D, dugotrajne terapije litijumom i hronične bubrežne bolesti.

Ding i saradnici su 2019. godine analizirali su komplikacije i preživljavanje implantata nakon hemiartoplastike kod pacijenata sa bubrežnom bolešću. Incidencija labavljenja bila je veća kod pacijenata sa hiperparatiroidizmom. Hiper-paratiroidizam nije bio povezan sa intraoperativnim prelomima, ali je bio povezan sa povećanim stopama radiografskog labavljenja u poređenju sa svim pacijentima⁹.

U dva prikazana slučaja, pretpostavljamo da je gubitak oseointegracije zubnih implantata u korelaciji sa efektima HPT. Analizirali smo sve parametre koji su trenutno u korelaciji sa rizikom od kasnog odbacivanja implantata¹⁰ i uspehi smo da ih sve isključimo. Farmakološki tretman dva pacijenta nije bio povezan sa odbacivanjem implantata i nije se menjao tokom godina. Tokom posmatranog perioda nisu zabeležene sistemske zdravstvene promene.

Concerning the possible causes of these two failure cases, we took plenty of considerations. Both patients were screened for any systemic and local contraindication for the rehabilitation before the treatment. The blood tests (blood count, blood glucose, PT, PTT, INR) and the cardiologic assessment did not show any contraindication. The pharmacologic treatment of the two patients was not related to implant failure. Neither systemic health alterations nor changes in pharmacological therapy were reported during the observation period. During the annual follow up, we detected that no local alteration was able to lead to implant failure. Occlusal overload was already excluded due to the presence of a complete removable denture at the opposing arch.

This being the case, we required patients to perform a blood test to evaluate bone metabolism and specifically to assess parathyroid hormone levels (PTH), calcium levels and vitamin D.

The data of the blood tests were not in the normal range. The results showed normal calcemia, vitamin D deficiency and elevated PTH levels.

We referred the patients to an endocrinologist who diagnosed secondary hyperparathyroidism.

Discussion

Secondary hyperparathyroidism is a systemic disease causing bone loss. This condition can occur with vitamin D deficiency, long-term lithium therapy, and chronic renal disease.

In 2019 Benjamin TK Ding et al. analyzed the complications and implant survivorship of hemiarthroplasty in patients with renal disease. The incidence of loosening was higher in patients with hyperparathyroidism. Hyperparathyroidism was not associated with intraoperative fractures but was associated with increased rates of radiographic loosening when compared among all patients⁹.

In the two cases presented, we assume that the loss of osseointegration of dental implants is correlated with the effects of HPT. We have analyzed all the parameters that are currently correlated with a risk of late implant failure¹⁰ and were able to rule out all of them. The pharmacological treatment of the two patients was not related to implant failure and did not change over the years. No systemic health alterations were recorded during the observation period. During the annual follow up, we detected that no local alteration could lead to implant failure.

Tokom godišnjeg praćenja otkrili smo da nijedna lokalna promena nije mogla da dovede do odbacivanja implantata. Okluzalno preopterećenje je već isključeno zbog činjenice da je na suprotnom lulu proteza kompletno uklonjena.

Zubni implantati su u kontinuiranoj interakciji sa koštanim tkivom, prenoseći mehanička opterećenja na ekstracelularni matriks¹¹. Alternacija osteogeneze i resorpcije karakteriše ovaj proces interakcije, a zakoni Volfa i Frosta¹² ga regulišu. U slučaju visokih nivoa PTH, povećanje osteoklastne aktivnosti¹³ dovodi do poremećaja ravnoteže sistema u pravcu resorpciji kostiju. Osim toga, visoki nivoi PTH mogu smanjiti mineralizaciju i pogoršati kvalitet minerala i kolagena u novoformiranoj kosti¹⁴. Dakle, ako kortikalna kost gubi debljinu usled bolesti i trabekularna kost se formira slabije mineralizovana, onda to može ugroziti osteointegraciju potpornog implantata. Ovo možda neće biti klinički evidentno sve dok ne dođe do kasnog neuspjeha u proteznoj fazi².

Oba efekta mogu dovesti do odbacivanja implantata, kao što se to pretpostavlja u ova dva prijavljena slučaja.

Pošto ova dva pacijenta nisu imala nikakvu analizu nivoa PTH pre rehabilitacije implantata, nema informacija o tome kada je došlo do metaboličke promene. Međutim, pošto nije bilo izveštaja o tome u periodu od 5 godina, autori smatraju da je do oboljenja došlo nakon implantacije.

S obzirom na prijavljene destruktivne efekte u ova dva slučaja, poželjno je sprovesti studije kako bi se pokazalo da li visok nivo PTH može biti povezan sa gubitkom oseointegracije.

Ako se to potvrdi, treba obratiti pažnju na mogućnost ispitivanja nivoa PTH pre podvrgavanja implantoterapiji i tokom perioda praćenja, posebno kod visoko rizičnih pacijenata⁶. Međutim, biće potrebne dalje i opsežne studije koje bi pratile ovu povezanost kak bi se potvrdila klinička hipoteza.

Autori treba da prodiskutuju rezultate i kako se oni mogu tumačiti iz perspektive prethodnih studija i radnih hipoteza. O nalazima i njihovim implikacijama treba razgovarati u najširem mogućem kontekstu. Takođe se mogu istaknuti i budući pravci istraživanja.

Occlusal overload was already excluded due to the presence of a complete removable denture at the opposing arch.

Dental implants are in continuous interaction with the bone tissue, transferring the mechanical loads to the extracellular matrix¹¹. An alternation of osteogenesis and resorption characterizes this interaction process, and the laws of Wolff and Frost¹² regulate it. In the case of high PTH levels, an increase in osteoclastic activity¹³ unbalances the system towards bone resorption. In addition, high PTH levels can reduce mineralization and worsen mineral and collagen quality in a newly formed bone¹⁴. Therefore, if the cortical bone is losing thickness because of the disease and trabecular bone is formed preferentially but not being substantially mineralized, then supportive implant osseointegration may be compromised. This may not be clinically evident until there is a late failure in the prosthetic phase².

Both effects could lead to implant failure, as supposed in the two reported cases.

Since the two patients did not have any analysis of PTH levels before implant-prosthetic rehabilitation, there is no information on when the metabolic alteration occurred. However, since there were no reports on this in the 5-year observation period, it is the authors' opinion that the pathogenesis occurred after the implant treatment.

Given the destructive effects reported in these two cases, it is desirable to conduct studies to demonstrate whether a high level of PTH could be related to the loss of osseointegration.

If ascertained, we should pay attention to the possibility of investigating the levels of PTH before undergoing implant therapy and during the follow-up period, especially in high-risk patients⁶.

Nevertheless, further and extensive association studies will be needed to validate the clinical hypothesis.

Authors should discuss the results and how they can be interpreted from the perspective of previous studies and of the working hypotheses. The findings and their implications should be discussed in the broadest context possible. Future research directions may also be highlighted.

Zaključak

Na osnovu prikazanih slučajeva, logično je pretpostaviti da gubitak oseointegracije dentalnih implantata može biti u korelaciji sa efektima HPT. Međutim, s obzirom na ograničenje ovog prikaza slučajeva, biće potrebne dalje studije da bi se potvrdila veza HPT sa neuspehom u ugradnji implantata i gubitkom osteointegracije.

Konflikt interesa: Nema
Finansijske podrške: Nema
Zahvalnice: Nema

Conclusion

According to the presented cases, it is reasonable to assume that the loss of osseointegration of dental implants can be correlated with the effects of HPT. However, since the limitation of this case report, further studies will be needed to validate the relationship with HPT and implant failure and loss of osteointegration

Conflict of Interest: Nil
Financial Support: Nil
Acnowlegments: Nil

LITERATURA /REFERENCES

1. Raikar S, Talukdar P, Kumari S, Panda SK, Oommen VM, Prasad A., Factors affecting the survival rate of dental implants: A retrospective study; *J Int Soc Prevent Communit Dent* 2017; 7:351-5.
2. Flanagan D, Mancini M. Bimaxillary full arch fixed dental implant supported treatment for a patient with renal failure and secondary hyperparathyroidism and osteodystrophy. *J Oral Implantol.* 2015 Apr;41(2):e36-43.
3. Khundmiri SJ, Murray RD, Lederer E.: PTH and Vitamin D; *American Physiological Society. ComprPhysiol* 2016; 6:561-601.
4. Lombardi G, Di Somma C, Rubino M, Faggiano A, Vuolo L, Guerra E, Contaldi P, Savastano S, Colao A: The roles of para-thyroid hormone in bone remodeling: prospects for novel therapeutics; *J Endocrinol Invest.* 2011 Jul;34(7 Suppl):18-22.
5. Wojda SJ, Donahue SW. Parathyroid hormone for bone regeneration; *J Orthop Res.* 2018 Oct;36(10):2586-2594.
6. Duan K, Gomez Hernandez K, Mete O. Clinicopathological correlates of hyperparathyroidism; *J Clin Pathol* 2015;68:771–787.
7. Rai S, Bhadada SK, Rattan V, Bhansali A, Rao DS, Shah V. Oro-mandibular manifestations of primary hyperparathyroidism. *Indian J Dent Res.* 2012 May-Jun;23(3):384-7.
8. Brockmann W, Badr M. Chronic kidney disease. *JADA* 2010;141: 1330–1339.
9. Ding BT, Shinde A, Tan KG. Hip hemiarthroplasty for femoral neck fractures in end-stage renal disease patients on dialysis compared to patients with late-stage chronic kidney disease. *Singapore Med J.* 2019 Aug; 60(8):403-408.
10. Do, T.A.; Le, H.S.; Shen, Y.-W.; Huang, H.-L.; Fuh, L.-J. Risk Factors related to Late Failure of Dental Implant—A Systematic Review of Recent Studies. *Int. J. Environ. Res. Public Health* 2020, 17, 3931. <https://doi.org/10.3390/ijerph17113931>
11. Kuroshima, Masaru S. Kaku, M Ishimoto, T Sasaki, M Nakano, T Sawase.T: A paradigm shift for bone quality in dentistry: A literature review, *Journal of Prosthodontic Research.* 2017: 61(4): 353-362.
12. Frost HM: A 2003 Update of Bone Physiology and Wolff's Law for Clinicians. *The Angle Orthodontist*; February 2004; 74 (1) ; 3-15.
13. Lee SK, Lorenzo. Parathyroid Hormone Stimulates TRANCE and Inhibits Osteoprotegerin Messenger Ri-bonucleic Acid Expression in Murine Bone Marrow Cultures: Correlation with Osteoclast-Like Cell Formation, *Endocrinology* 1999;140(8):3552-3561,
14. Yoshioka, Y., Yamachika, E., Nakanishi, M. et al.: Intermittent parathyroid hormone 1–34 induces oxidation and deterioration of mineral and collagen quality in newly formed mandibular bone. *Sci Rep* 2019;9:8041.